



A SUPPLEMENT TO

JOURNAL OF DRUGS IN DERMATOLOGY

JDD

DRUGS • DEVICES • METHODS

PREBIOTIC SKINCARE MANAGEMENT
OF ATOPIC DERMATITIS AND XEROSIS
IN DIVERSE ETHNICALLY PATIENTS

This supplement to the *Journal of Drugs in Dermatology* is funded by La Roche-Posay Laboratoire Dermatologique.

PREBIOTIC SKINCARE MANAGEMENT OF ATOPIC DERMATITIS AND XEROSIS IN DIVERSE ETHNICALLY PATIENTS

INTRODUCTION

- s4 **Recent Advances in Skincare Management of Atopic Dermatitis in Diverse Racial and Ethnic Groups**

Hawasatu Dumbuya PhD, Katharine Podimatis MA

ORIGINAL ARTICLE

- s6 **Atopic Dermatitis Skincare and Impact on Quality of Life for Patients With Skin of Color**

Hawasatu Dumbuya PhD, Chesahna Kindred MD MBA, Cheri N. Frey MD, Zoe Diana Draelos MD

- s12 **Efficacy of a Prebiotic Skincare Regimen on Improving Mild Atopic Dermatitis and Severe Xerosis in Diverse Ethnically Patients**

Hawasatu Dumbuya PhD, Katharine Podimatis MA, Delphine Kerob MD, Zoe Diana Draelos MD

Recent Advances in Skincare Management of Atopic Dermatitis in Diverse Racial and Ethnic Groups

Hawasatu Dumbuya PhD, Katharine Podimatis MA

La Roche-Posay Laboratoire Dermatologique, L'Oréal USA, New York, NY

Atopic Dermatitis (AD) is a chronic relapsing inflammatory skin disease associated with a significant patient burden on quality-of-life. Rising evidence demonstrate skin microbiome playing an essential role in AD pathogenesis. A decrease in skin microbial diversity, particularly an overabundance of *Staphylococcus aureus* colonization, is observed on AD lesional skin, plus is associated with disease severity.¹

AD epidemiology studies report a higher incidence and prevalence among patients with skin of color (SOC).² Racial/ethnic variations in AD clinical phenotypes and endophenotypes, including *S. aureus* colonization have been reported.³ Despite higher prevalence and persistence, particularly in children, populations with skin of color remain underreported and underrepresented in dermatology clinical trials.⁴ The lack of diversity in AD clinical trials contributes to the lack of knowledge and documentation surrounding the various possible AD clinical manifestations, disease progression, impact on quality-of-life, and most importantly short and long-term treatment strategies.

Given skin barrier including skin microbiome changes are linked to AD pathogenesis, prebiotic emollients are shown to improve disease symptoms and maintain skin barrier integrity, normalizing skin microbiota.⁵ This JDD supplement aims at providing the most recent updates on the role of skincare in managing Atopic Dermatitis and Xerosis in diverse ethnic patients, highlighting nuances between skin conditions and impact on quality-of-life, plus bringing forth new clinical knowledge on the benefits of a prebiotic cleanser and moisturizer regimen to manage long-term sequelae.

DISCLOSURE

The authors declare no conflict of interest.

REFERENCES

1. Seite S, Flores GE, Henley JB, et al. Microbiome of affected and unaffected skin of patients with atopic dermatitis before and after emollient treatment. *J Drugs Dermatol*. 2014;13(11):1365-72.

2. Kaufam BP, Guttman-Yassky E, Alexis AF. Atopic dermatitis in diverse racial and ethnic groups—Variations in epidemiology, genetics, clinical presentation and treatment. *Exp Dermatol*. 2018;27(4):340-357

3. Merriman JA, Mueller EA, Cahill MP, et al. Temporal and racial differences associated with atopic dermatitis staphylococcus aureus and encoded virulence factors. *mSphere*. 2016;1(6):e00295-16.

4. Hirano SA, Murray SB, Harvey VM. Reporting, Representation, and subgroup analysis of race and ethnicity in published clinical trials of atopic dermatitis in the United States Between 2000 and 2009. *Pediatr Dermatol*. 2012;29(6):749-5

5. Zelenkova H, Kerob D, Salah S, et al. Impact of daily use of emollient 'plus' on corticosteroid consumption in patients with atopic dermatitis: An open, randomized controlled study. *J Eur Acad Dermatol Venereol*. 2023;37 Suppl 5:27-34.

AUTHOR CORRESPONDENCE

Hawasatu Dumbuya PhD

E-mail:..... hawasatu.dumbuya@loreal.com

Atopic Dermatitis Skincare and Impact on Quality of Life for Patients With Skin of Color

Hawasatu Dumbuya PhD,^a Chesahna Kindred MD MBA,^b Cheri N. Frey MD,^c Zoe Diana Draelos MD^d

^aLa Roche-Posay Laboratoire Dermatologique, L'Oréal USA, New York, NY

^bKindred Hair & Skin Center, Columbia, MaD

^cHoward University Dept of Dermatology, Washington, DC

^dDermatology Consulting Services, PLLC, High Point, NC

ABSTRACT

Atopic Dermatitis (AD) epidemiologic studies report a higher incidence and prevalence among populations with skin of color (SOC). Additionally, differences in AD underlying gene mutations and skin morphology are observed to lead to frequent and prominent xerosis, pruritus, and pigmentary sequelae in patients of color. However, populations with SOC are underrepresented in dermatology clinical trials, including AD. This article reviews the nuances in AD epidemiology, clinical presentation, and impact on quality-of-life among populations with SOC, plus highlight the role of skincare in AD management.

J Drugs Dermatol. 2024;23:3(Suppl 2):s6-11.

INTRODUCTION

Atopic dermatitis (AD) is a chronic inflammatory skin disease characterized by pruritic eczematous lesions and associated adverse health outcomes, including cutaneous symptoms, subsequent sleep disturbance, and mental health impact.¹ AD has a high prevalence and is the leading cause of skin-related burden of disease globally.^{2,3} Disparities in AD health care and variations in the clinical presentation have been reported to impact the quality-of-life (QoL) of patients of color.⁴⁻⁶ This article reviews the nuances in AD epidemiology, clinical presentation, and impact on QoL among US populations with SOC, plus highlight the role of skincare in AD management.

Atopic Dermatitis Epidemiology in Patients With Skin of Color

AD pathogenesis involves a complex interplay of genetic factors, immune dysregulation, defective skin barrier, environmental factors and microbial dysbiosis.^{1,7,8}

AD epidemiologic data reports a higher incidence and prevalence among patients with SOC. For example, a study demonstrated that African Americans have 19% AD prevalence compared with 16% in European-Americans counterparts.^{9,10} Similarly, higher AD prevalence and persistence in children with SOC in the US have been reported.³

Immunophenotypic and genetic variations between racial/ethnic populations have also been described, including filaggrin gene mutations, plus lipid content and stratum corneum structure differences.¹¹ The most studied genetic variation is filaggrin, which is a structural protein involved in skin barrier function, and filaggrin-2 mutations are associated with AD persistence.

However, African American children with AD show significantly fewer filaggrin mutations, which does not correlate with the increased AD prevalence and persistence in populations with SOC. This nuance may indicate that

the increased AD prevalence in African Americans is not fully explained by ancestry-related genetic effects.^{11,12} Multiple genes involved in epithelial barrier function and immune regulation are implicated in AD pathogenesis, which results from the synergistic effect of numerous genes.⁷

Racial/Ethnic Variations in Atopic Dermatitis Presentation

Although AD presents similarly across racial/ethnic groups as chronic and relapsing pruritic eczematous lesions, it can differ in clinical presentation and morphology in certain populations with SOC. AD may present as gray, hyperchromic, reddish-brown, or violaceous rather than bright red in patients of color.⁸ Furthermore, AD patients of color may show more frequent and prominent xerosis, pruritus, pigmentary sequelae (erythema and post-inflammatory dys-pigmentation), follicular accentuation, lichenoid morphologies, and papulonodular presentations.⁷⁻⁹

Populations with SOC remain underreported and underrepresented in dermatology and clinical trials.¹³⁻¹⁵ When reporting occurs, the racial/ethnic categorization and incorporation of the racial/ethnic data into the results are often lacking. The lack of diversity in AD clinical trials contributes to the lack of knowledge and documentation surrounding the various possible AD clinical manifestations on multiple skin tones, which may impact clinicians' ability to diagnose AD in patients of color. Recognizing differing AD clinical presentations, and disease course, including morphological variations in ethnically diverse patients is important for an accurate and early diagnosis, plus appropriate short and long-term treatment.¹⁶

Atopic Dermatitis Impact on Quality of Life for Patients With Skin of Color

More pronounced AD clinical and morphological variations in patients of color may critically impact QoL.⁷⁻⁹ In populations with SOC, AD prevalence was shown to be higher, while disease control poorer.¹² Due to greater visibility in the context of darker skin, AD-associated xerosis and post-inflammatory dys-pigmentation are more pronounced and stigmatizing in patients of color.^{7,9} The increased xerosis prevalence and severity in patients of color is likely due to racial/ethnic differences in skin bar-

rier properties. One study in 311 American women from four ethnic groups (African-American, Caucasian, Chinese and Mexican) showed that the skin dryness index markedly increases in African-American and Caucasian groups, but not in Chinese and Mexican counterparts.¹⁷ Moreover, AD-related pruritus is more burdensome in patients of color due to potential scarring and lasting post-inflammatory dyspigmentation.^{7,9,18} For example, one study reported higher levels of pruritus-related burning and scarring, as well as greater emotional impact in patients of color.¹⁸ Another study reported children with SOC were more likely to be absent from school due to AD, which was not explained by sociodemographic factors, health care visits, and atopic comorbidities.¹⁹

Disturbing racial/ethnic disparities in health care utilization and access to standard-of-care therapies for AD have been identified in populations with SOC, impacting QoL.^{4-6,9,20,21} Additionally, structural racism likely has significant impact on AD progression for patients of color.²² AD patients with SOC have reduced specialty care utilization and more frequent primary care, urgent care, emergency department, and hospital utilization.²⁰⁻²⁴ Among patients with AD, African-Americans are less likely than white to receive specialty care, such as a dermatologist.^{20,21,23,24} Thus, efforts to improve access to specialty dermatologic AD care is needed to potentially decrease healthcare costs and improve outcomes for populations with SOC.

Overall, AD impact on QoL in patients of color is significant compared to white counterparts due to the disease burden, potential long-lasting sequelae, and disparities in healthcare, which impose many barriers to proper treatment.

Skincare Management of Atopic Dermatitis in Patients With Skin of Color

Epidermal skin barrier dysfunction plays a key role in AD development, and various types of emollients are shown to prevent AD in both pediatric and adult patients.²⁵⁻²⁷ Maintaining an intact skin barrier by using gentle cleansers and moisturizers can attenuate AD by delaying or reducing flares.^{9,26} AD-associated hyperpigmentation is more frequent and pronounced in patients with SOC; however many hyperpigmentation treatments, such as hydroquinone, can be irritating in AD affected skin.⁹ Moreover, though effective, long-term continuous AD treatment with standard-of-care topical corticosteroids

TABLE 1.

Racial Ethnic Variations in Atopic Dermatitis Patients			
Author/Year	Study Population/N	What was studied?	Key Findings
Shaw, 2011	102,353 children	Eczema prevalence in the US: data from the 2003 National Survey of Children's Health	African American and metropolitan living were significantly associated with a higher eczema prevalence
Hirano, 2012	645 clinical trials	Race and ethnicity in published AD clinical trials in the US between 2000 and 2009	No significant improvement in demographic data reporting in AD clinical trials
Margolis, 2012	857 children	Association of filaggrin variants with AD persistence children	The filaggrin variants in US children with AD differ significantly by race and association with AD persistence
Hay, 2014	Prevalence study in 187 countries	The global burden and prevalence of skin disease and impact of skin conditions	AD has a high prevalence and is the leading cause of skin-related burden of disease globally
Brunner, 2019	PubMed literature review (years 2000-2018)	Racial differences in AD	AD has differences among various ethnic and racial groups
Kim, 2019	1437 mother-child pairs	Racial/ethnic differences in incidence and persistence of childhood AD	AD incidence and persistence are higher among certain nonwhite racial/ethnic subgroups
Margolis, 2019	741 children	Association of filaggrin loss-of-function variants with race in children with AD	The filaggrin variants in US children with AD differ significantly by race and association with AD persistence
McKenzie, 2019	4898 mother-child pairs	The prevalence and persistence of AD in urban US children	AD prevalence and persistence were highest in African American US urban children
Abuabara, 2020	86,893 adults	Genetic ancestry association with AD susceptibility and disease control among US African Americans	Ancestry-related genetic effects do not explain increased AD prevalence or poorer disease control among African Americans
Bell, 2020	40,906 adults	Racial and ethnic disparities in access to emerging and frontline AD therapies	Racial and ethnic disparity in accessing newly approved and standard of care medical therapies for AD
Tackett, 2020	201 children	Race and socioeconomic influence on the AD severity in African American children	Race and socioeconomic status affect AD severity in African American children
Sevagamoorthy, 2022	119 clinical trials	Racial and ethnic diversity of US participants in AD clinical trials	Race and ethnicity remain underreported in dermatologic clinical trials

and calcineurin inhibitors is associated with adverse effects and hypopigmentation in patients with SOC.^{7,28} Early intervention of pigmentary changes, plus topical alternatives with anti-inflammatory and skin barrier repair properties that allow routine long-term use without risk can be effective in reducing AD severity, and related symptoms for patients of color.^{26,29-31}

The skin microbiome plays an important role in AD pathophysiology.³²⁻³⁴ Several studies have evaluated the role of the microbiome in skin barrier function, and the efficacy of prebiotic emollients to target *Staphylococcus aureus* for AD management.³⁵⁻³⁸ More recently, a prebiotic emollient, containing shea butter, canola oil, niacinamide and *Aqua posae filiformis* (a lysate of *Vf* grown in La Roche-Posay thermal spring water), was shown to significantly decrease the usage frequency of topical corticosteroid after 28 days in AD patients, compared to control group who used their usual classical emollient.³⁹ Similarly, the same prebiotic emollient provided significant greater reduction pruritus in AD patients under systemic therapy (cyclosporin A, dupilumab or a Janus kinase inhibitor).⁴⁰ Additionally, emollients 'plus', which correspond to prebiotic emollients have recently been recommended in European AD guidelines.^{41,42} Altogether, these results highlight the benefits of prebiotic skincare in AD treatment and the role of microbiome for healthy skin barrier.

Though, a plethora of AD moisturizers are available, the lack of robust comparative studies with ethnically diverse populations poses a challenge. Racial/ethnic variations in AD clinical presentation, as well as a greater burden of pruritus and xerosis among patients with SOC may require different approaches to AD management and treatment. US guidelines strongly recommend moisturizers and gentle cleansers as an integral part of AD management to reduce disease severity and the need for pharmacological intervention.²⁶ Therefore, clinicians should integrate QoL assessments, skincare, and prescription therapies with patient perspectives on cultural norms and treatment priorities.

CONCLUSION

In populations with SOC, AD is more prevalent and is associated with a variety of physical and mental QoL impacts. In addition, healthcare and socioeconomic disparities affect the access to AD specialty care and dermatologic clinical trials for patients with SOC. Increased clinician awareness of AD presentation, associated symptoms and comorbidities, plus impact on patients of color will improve treatment outcomes. Further research is needed on the benefits of adjunctive emollients, moisturizers, and cleansers in the management of AD and their impact on QoL in diverse ethnically populations.

DISCLOSURES

HD is an employee of La Roche-Posay Laboratoire Dermatologique, L'Oreal USA. CK has served as on the advisory board and speaker for Lilly, UCB, Aerolase, Sun Pharmaceuticals, Regeneron; a speaker for Nutrafol, Novartis; consultant for Abbvie, Pfizer; and Janssen steering committee, SOC advisory board. CNF has served as an advisor and consultant for L'Oreal. ZDD has served as a researcher and consultant for L'Oreal.

ACKNOWLEDGMENT

We thank RBC Consultants for their contribution to manuscript.

REFERENCES

1. Lopez Carrera YI, Al Hammadi A, Huang YH, et al. Epidemiology, diagnosis, and treatment of atopic dermatitis in the developing countries of Asia, Africa, Latin America, and the Middle East: a review. *Dermatol Ther (Heidelb)*. 2019;9(4):685-705.
2. Hay RJ, Johns NE, Williams HC, et al. The global burden of skin disease in 2010: an analysis of the prevalence and impact of skin conditions. *J Invest Dermatol*. 2014;134(6):1527-1534.
3. Kim Y, Blomberg M, Rifas-Shiman SL, et al. Racial/ethnic differences in incidence and persistence of childhood atopic dermatitis. *J Invest Dermatol*. 2019;139(4):827-834.

4. Patel KR, Singam V, Vakharia PP, et al. Measurement properties of three assessments of burden used in atopic dermatitis in adults. *Br J Dermatol*. 2019;180(5):1083-1089.
5. McKenzie C, Silverberg JI. The prevalence and persistence of atopic dermatitis in urban United States children. *Ann Allergy Asthma Immunol*. 2019;123(2):173-178.e1.
6. Silverberg JI, Margolis DJ, Boguniewicz M, et al. Validation of five patient-reported outcomes for atopic dermatitis severity in adults. *Br J Dermatol*. 2020;182(1):104-111.
7. Kaufman BP, Guttman-Yassky E, Alexis AF. Atopic dermatitis in diverse racial and ethnic groups-Variations in epidemiology, genetics, clinical presentation and treatment. *Exp Dermatol*. 2018;27(4):340-357.
8. Leung DY. Atopic dermatitis: Age and race do matter! *J Allergy Clin Immunol*. 2015;136(5):1265-1267.
9. Alexis A, Woolery-Lloyd H, Andriessen A, et al. Insights in skin of color patients with atopic dermatitis and the role of skincare in improving outcomes. *J Drugs Dermatol*. 2022;21(5):462-470.
10. Brunner PM, Guttman-Yassky E. Racial differences in atopic dermatitis. *Ann Allergy Asthma Immunol*. 2019;122(5):449-455.
11. Margolis DJ, Apter AJ, Gupta J, et al. The persistence of atopic dermatitis and filaggrin (FLG) mutations in a US longitudinal cohort. *J Allergy Clin Immunol*. 2012;130(4):912-917.
12. Abuabara K, You Y, Margolis DJ, et al. Genetic ancestry does not explain increased atopic dermatitis susceptibility or worse disease control among African American subjects in 2 large US cohorts. *J Allergy Clin Immunol*. 2020;145(1):192-198.e11.
13. Hirano SA, Murray SB, Harvey VM. Reporting, representation, and subgroup analysis of race and ethnicity in published clinical trials of atopic dermatitis in the United States between 2000 and 2009. *Pediatr Dermatol*. 2012;29(6):749-755.
14. Chatrath S, Bradley L, Kentosh J. Dermatologic conditions in skin of color compared to white patients: similarities, differences, and special considerations. *Arch Dermatol Res*. 2023;315(5):1089-1097.
15. Sevagamoorthy A, Sockler P, Akoh C, et al. Racial and ethnic diversity of US participants in clinical trials for acne, atopic dermatitis, and psoriasis: a comprehensive review. *J Dermatolog Treat*. 2022;33(8):3086-3097.
16. Alexis AF, Woolery-Lloyd H, Williams K, et al. Racial/ethnic variations in skin barrier: implications for skincare recommendations in skin of color. *J Drugs Dermatol*. 2021;20(9):932-938.
17. Diridollou S, de Rigo J, Querleux B, et al. Comparative study of the hydration of the stratum corneum between four ethnic groups: influence of age. *Int J Dermatol*. 2007;46 Suppl 1:11-14.
18. Shaw FM, Luk KMH, Chen KH, et al. Racial disparities in the impact of chronic pruritus: A cross-sectional study on quality of life and resource utilization in United States veterans. *J Am Acad Dermatol*. 2017;77(1):63-69.
19. Wan J, Margolis DJ, Mitra N, et al. Racial and Ethnic Differences in Atopic Dermatitis-Related School Absences Among US Children. *JAMA Dermatol*. 2019;155(8):973-975.
20. Wan J, Oganisian A, Spieker AJ, et al. Racial/Ethnic variation in use of ambulatory and emergency care for atopic dermatitis among US children. *J Invest Dermatol*. 2019;139(9):1906-1913.e1.
21. Bell MA, Whang KA, Thomas J, et al. Racial and ethnic disparities in access to emerging and frontline therapies in common dermatological conditions: a cross-sectional study. *J Natl Med Assoc*. 2020;112(6):650-653.
22. Tackett KJ, Jenkins F, Morrell DS, et al. Structural racism and its influence on the severity of atopic dermatitis in African American children. *Pediatr Dermatol*. 2020;37(1):142-146.
23. Silverberg JI, Gelfand JM, Margolis DJ, et al. Atopic dermatitis in US adults: from population to health care utilization. *J Allergy Clin Immunol Pract*. 2019;7(5):1524-1532.e2.
24. Chovatiya R, Begolka WS, Thibau IJ, et al. Financial burden and impact of atopic dermatitis out-of-pocket health care expenses among black individuals in the United States. *Arch Dermatol Res*. 2022;314(8):739-747.
25. Eichenfield LF, Tom WL, Chamlin SL, et al. Guidelines of care for the management of atopic dermatitis: section 1. Diagnosis and assessment of atopic dermatitis. *J Am Acad Dermatol*. 2014;70(2):338-351.
26. Eichenfield LF, Tom WL, Berger TG, et al. Guidelines of care for the management of atopic dermatitis: section 2. Management and treatment of atopic dermatitis with topical therapies. *J Am Acad Dermatol*. 2014;71(1):116-132.
27. Simpson EL, Chalmers JR, Hanifin JM, et al. Emollient enhancement of the skin barrier from birth offers effective atopic dermatitis prevention. *J Allergy Clin Immunol*. 2014;134:818-23.
28. Harcharik S, Emer J. Steroid-sparing properties of emollients in dermatology. *Skin Therapy Lett*. 2014;19(1):5-10.

29. van Zuuren EJ, Fedorowicz Z, Christensen R, et al. Emollients and moisturisers for eczema. *Cochrane Database Syst Rev.* 2017;2(2):CD012119.
30. Rerknimitr P, Otsuka A, Nakashima C, et al. Skin barrier function and atopic dermatitis. *Curr Derm Rep.* 2018;7:209-220.
31. Danby SG, Andrew PV, Brown K, et al. An investigation of the skin barrier restoring effects of a cream and lotion containing ceramides in a multi-vesicular emulsion in people with dry, eczema-prone, skin: the RESTORE study phase 2. *J Am Acad Dermatol.* 2020;83(6):Suppl AB71.
32. Strugar TL, Kuo A, Seit  S, et al. Connecting the dots: from skin barrier dysfunction to allergic sensitization, and the role of moisturizers in repairing the skin barrier. *J Drugs Dermatol.* 2019;18(6):581.
33. Seite S, Bieber T. Barrier function and microbiotic dysbiosis in atopic dermatitis. *Clin Cosmet Investig Dermatol.* 2015;8:479-483.
34. Baldwin HE, Bhatia ND, Friedman A, et al. The role of cutaneous microbiota harmony in maintaining a functional skin barrier. *J Drugs Dermatol.* 2017;16(1):12-18.
35. Seite S, Flores GE, Henley JB, et al. Microbiome of affected and unaffected skin of patients with atopic dermatitis before and after emollient treatment. *J Drugs Dermatol.* 2014;13(11):1365-1372.
36. Gueniche A, Knaudt B, Schuck E, et al. Effects of nonpathogenic gram-negative bacterium *Vitreoscilla filiformis* lysate on atopic dermatitis: a prospective, randomized, double-blind, placebo-controlled clinical study. *Br J Dermatol.* 2008;159(6):1357-1363.
37. Seit  S, Zelenkova H, Martin R. Clinical efficacy of emollients in atopic dermatitis patients - relationship with the skin microbiota modification. *Clin Cosmet Investig Dermatol.* 2017;10:25-33.
38. Moreau M, Seit  S, Aguilar L, et al. Topical *S. aureus* - targeting endolysin significantly improves symptoms and QoL in individuals with atopic dermatitis. *J Drugs Dermatol.* 2021;20(12):1323-1328.
39. Zelenkova H, Kerob D, Salah S, et al. Impact of daily use of emollient 'plus' on corticosteroid consumption in patients with atopic dermatitis: An open, randomized controlled study. *J Eur Acad Dermatol Venereol.* 2023;37 Suppl 5:27-34.
40. Magnolo N, Jaenicke T, Tsianakas A, et al. Comparison of different skin care regimens in patients with moderate to severe atopic dermatitis receiving systemic treatment: A randomized controlled trial. *J Eur Acad Dermatol Venereol.* 2023;37 Suppl 5:18-26.
41. Wollenberg A, Kinberger M, Arents B, et al. European guideline (EuroGuiDerm) on atopic eczema: part I - systemic therapy. *J Eur Acad Dermatol Venereol.* 2022;36(9):1409-1431.
42. Wollenberg A, Kinberger M, Arents B, et al. European guideline (EuroGuiDerm) on atopic eczema - part II: non-systemic treatments and treatment recommendations for special AE patient populations. *J Eur Acad Dermatol Venereol.* 2022;36(11):1904-1926.
43. Crudele J, Kim E, Murray K, et al. The importance of understanding consumer preferences for dermatologist recommended skin cleansing and care products. *J Drugs Dermatol.* 2019;18(1s):s75-s79.

AUTHOR CORRESPONDENCE

Hawasatu Dumbuya PhD

E-mail:..... hawasatu.dumbuya@loreal.com

Efficacy of a Prebiotic Skincare Regimen on Improving Mild Atopic Dermatitis and Severe Xerosis in Diverse Ethnically Patients

Hawasatu Dumbuya PhD,^a Katharine Podimatis MA,^a Delphine Kerob MD,^b Zoe Diana Draelos MD^c

^aLa Roche-Posay Laboratoire Dermatologique, L'Oréal USA, New York, NY

^bLa Roche-Posay Laboratoire Dermatologique, L'Oréal, Levallois-Perret, France

^cDermatology Consulting Services, PLLC, High Point, NC

ABSTRACT

Atopic Dermatitis (AD) is a chronic relapsing inflammatory skin disease associated with a significant patient burden on quality-of-life. Given skin barrier including skin microbiome changes are linked to AD pathogenesis, prebiotic emollients are shown to improve disease symptoms and maintain skin barrier integrity, normalizing skin microbiota. In this study, we evaluated the efficacy and safety of a prebiotic skincare routine in improving AD and xerosis, and ultimately quality-of-life in ethnically diverse patients. A total of 140 subjects from different racial/ethnic backgrounds, aged 3-80 years old with skin phototypes I-VI, and presenting with mild-AD or severe xerosis completed study. Expert grading, instrumentation, self-assessment questionnaires, plus clinical imaging demonstrated that a prebiotic cleanser and moisturizer routine significantly reduced skin conditions severity, strengthened skin barrier properties in both lesional and normal skin, and improved patients' quality-of-life while providing itch relief as soon as 4 weeks. The results of this research indicate that a prebiotic cleanser and moisturizer regimen offers benefits for diverse patient's daily skincare routine by effectively managing AD and xerosis severity and symptoms, normalizing skin microbiota, plus preserving skin barrier integrity to prevent long-term sequelae.

J Drugs Dermatol. 2024;23:3(Suppl 2):s12-22.

INTRODUCTION

Atopic Dermatitis (AD) is a common and heterogeneous chronic relapsing inflammatory skin disease, characterized with eczematous and pruritic lesions.¹ Affecting both children and adults, it is associated with a significant burden on patients' quality-of-life and several comorbidities, such as skin pain, sleep disturbance and depression.^{2,3} AD epidemiology studies report a higher incidence and prevalence among patients with skin of color (SOC).⁴⁻⁹ In the US, African American children are 1.7 times likely to develop AD than their European American counterparts, and 3 times more likely to be diag-

nosed with disease after a dermatology visit.^{10,11} SOC individuals also have increased cost of care and prolonged length of stay associated with their AD.¹² These nuances between racial/ethnic groups may require different approaches to AD treatment to effectively manage symptoms and prevent long-term sequelae.

AD pathophysiology is multifactorial and involves gene predisposition, skin barrier dysfunction, environmental triggers, immune dysregulation, and microbial dysbiosis.^{1,13-17} Rising evidence demonstrate skin microbiome playing an essential role in AD pathogenesis.¹⁶⁻¹⁸

A decrease in skin microbial diversity, particularly an overabundance of *Staphylococcus aureus* colonization, is observed on AD lesional skin, plus is associated with disease severity and skin barrier dysfunction.¹⁹⁻²¹ In children, lack of skin microbiome diversity was shown to be present during AD flares, and to precede disease clinical diagnosis.^{22,23}

Several studies have evaluated the efficacy of emollients on preserving skin barrier integrity and maintaining bacterial diversity for AD symptoms management.^{21,24-26} In AD patients, Seite et al., demonstrated that emollient treatment significantly reduced erythema, dryness, and desquamation on lesional skin, plus restored skin microbiome composition comparable to normal skin after 84-days.²¹ Additionally, prebiotic emollient containing *Vitreoscilla filiformis* (Vf) lysate, a Gram-negative nonpathogenic bacterium with anti-inflammatory and antioxidant properties, showed to decrease AD-related pruritus, severity, and transepidermal water loss (TEWL), plus normalized skin microbiota by reducing *S. aureus* abundance in AD patients.²⁷⁻³⁰ Recently, prebiotic emollients were demonstrated to decrease the usage frequency of topical corticosteroid in patients with mild to moderate AD, as well as reducing pruritus in moderate to severe AD patients under systemic therapy.^{31,32} These studies support the recommendation European AD guidelines of using emollients ‘plus’ in AD patients, which correspond to emollients supplemented with active ingredients and non-medicated substances.^{33,34} Together, these findings highlight the benefits of prebiotic skincare in AD management and the role of microbiome for healthy skin barrier.

Racial/ethnic variations in AD prevalence and severity, plus clinical phenotypes and endophenotypes, including *S. aureus* colonization have been reported.^{4-12,35,36} Despite higher prevalence and persistence, particularly in children, SOC patients are under-represented in AD clinical trials.³⁷ Additionally, limited studies exist on the benefits of adjunctive emollients in the management of AD in SOC individuals.^{26,37} In this study, we evaluated the efficacy of a prebiotic skincare routine, consisting of a cleanser and moisturizer, in improving mild-AD and severe xerosis, plus impact on quality-of-life in ethnically diverse US patients.

MATERIALS AND METHODS

Study Participants

The study was performed in accordance with Good Clinical Practices and the principles of the Declaration of Helsinki. The procedures used in this study were approved by Allendale Institutional Review Board (Old Lyme, CT). Before any study procedure, the subjects received the necessary written and verbal information and signed an informed consent form. Eligibility was determined by physical examination and confirmation of all inclusion/exclusion criteria. A total of hundred-and forty (140) subjects from diverse racial/ethnic backgrounds, aged 3-80 years old with skin phototypes I-VI, and presenting with mild-AD or moderate to severe xerosis completed study. Subjects with history of allergy, hypersensitivity, or any serious reaction to any cosmetic product; or any concomitant medical condition that may interfere with the study conduct in the opinion of the investigator were excluded.

Test Materials

The prebiotic cleanser (Lipikar AP+ Gentle Foaming Cleansing Oil) contained niacinamide, shea butter, glycerin and La Roche-Posay thermal spring water. The prebiotic moisturizer (Lipikar AP+M Moisturizing Cream) contained ceramide, shea butter, niacinamide, glycerin, Aqua posae filiformis (APF, a lysate of Vf grown in La Roche-Posay thermal spring water), plus Microresyl.

Study Design

After dermatological evaluations, all subjects started using a prebiotic cleanser alone for 2 weeks, followed by using a prebiotic moisturizer in adjunct for an additional 8 weeks. All subjects were given diaries to record daily frequency and time of product applications, plus any observations. Evaluations included clinical and instrumental assessments, quality-of-life questionnaires, plus clinical imaging at baseline (week 0), week 2, 4, 8, and 10.

Evaluations

The investigational area in this study were the legs. The severity of xerosis and AD were visually assessed by clinical expert grading. AD was evaluated using two different validated scales: 1) Investigator Global Assessment (IGA) and 2) Eczema Area and Severity Index (EASI); while xerosis was assessed using the Overall Dry Skin (ODS) scale. Safety and tolerance were evaluated throughout the study by dermatologically assessing the symptoms of erythema, edema, peeling and dryness, plus by subject reporting the degree of burning, stinging, tingling, tightness and itching on investigational area using an internally validated scale, ranging 0 (absence) to 3 (severe).

Skin hydration and pH levels were assessed using a corneometer (Dermalab, Cortex Technologies, Hansund, Denmark) and pH probe meter (Dermalab, Cortex Technologies, Hansund, Denmark) respectively. TEWL was assessed using a Tewameter (RG, Cyberderm, Broomall, PA). All instrumental evaluations were performed on both normal and lesional skin for AD patients.

Two (2) different self-assessments questionnaires were given to all subjects to evaluate the impact of the skin conditions and perceived benefits of the prebiotic skincare regimen: 1) Dermatology Life Quality Index (DLQI) questionnaire to assess quality of life, and 2) Worst Itch Numeric Rating Scale (WI-NRS) questionnaire to assess itch intensity during the previous 24-hour period.

Clinical Imaging

Clinical images of AD and xerosis patients' legs were taken at baseline, week 2 and 10 using SkinCam[®], a portable camera with crossed polarization modalities.³⁸

Statistical Analysis

All clinical assessment of efficacy and tolerance parameters were expressed in terms of raw and change from baseline data, by time and skin condition (xerosis and AD) group. All clinical assessment of efficacy and tolerance parameters were analyzed using a linear mixed model. Checking normality of data was done by using a normal probability plot of model residuals (qqplot). In case of huge departure from normality assumption, a

non-parametric test was preferred (Wilcoxon test at each time point). Benjamini Hochberg's adjustment was used for multiple comparison of all defined primary criteria. *P*-values < 0.05 were considered statistically significant.

RESULTS

AD & Xerosis Improvement Overtime

A hundred-and thirty-eight (138) subjects from diverse racial/ethnic backgrounds with a mean age of 42 + 9 years old completed study with evaluable data, consisting of sixty-nine (69) subjects presented with mild-AD, and 69 subjects with moderate to severe xerosis (Figure 1A). Starting at week 4, the prebiotic skincare regimen significantly improves global eczema appearance in AD subjects, reaching 86% and 93% reduction in IGA and EASI scores respectively by week 10 (Figure 1B & 1C). In xerosis subjects, we observed significant improvement in overall xerosis appearance with cleanser alone at 2 weeks, reaching 83% reduction by week 10 with prebiotic regimen (Figure 1D).

Skin Barrier Properties in AD & Xerosis Patients

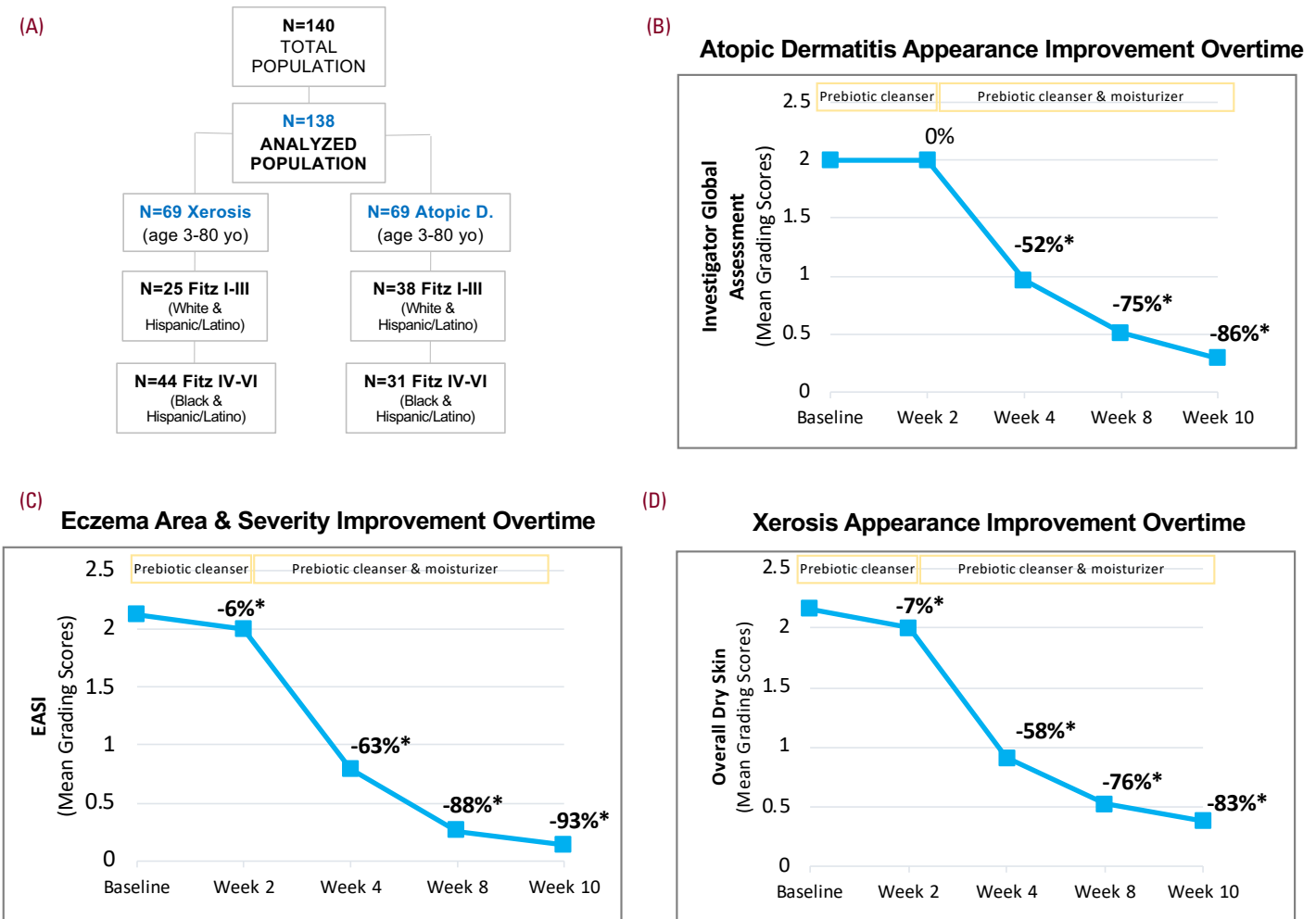
Next, we investigated the efficacy of the prebiotic regimen on skin barrier properties in AD and xerosis groups. TEWL showed no relevant change overtime in both groups (data not shown).

Starting at week 4, instrumentation demonstrated a significant increase in skin hydration and a decrease in skin pH levels on both normal and lesional skin in AD patients (Figure 2A & 2B), plus showed similar outcomes in xerosis subgroup (Figure 2C & 2D). These results suggest that the prebiotic skincare routine strengthens skin barrier properties overtime.

Itch Relief & Quality-of-Life Improvement in AD & Xerosis Patients

To further elucidate the impact of AD and xerosis in patients, plus perceived benefits of the prebiotic skincare regimen, we assessed itching symptoms and quality-of-life using self-assessment questionnaires. AD subjects perceived significant reduction in itching sensation with cleanser at week 2, reaching complete relief with regi-

FIGURE 1. Prebiotic cleanser and moisturizer routine reduces atopic dermatitis and xerosis severity. (A) Patient demographics included into study. Clinical assessments of AD severity using **(B)** IGA and **(C)** EASI scales, plus **(D)** xerosis severity using ODS scale.



*denotes $P < .05$ vs. Baseline.

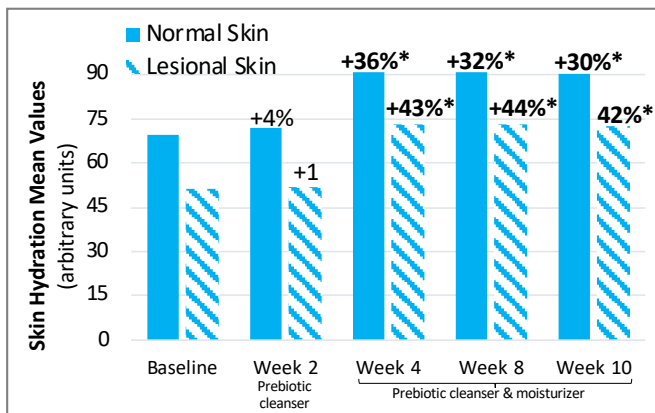
men by week 10 (Figure 3A). Interestingly, AD patients of color (Fitz IV-VI, $n=31$) showed earlier reduction in itching sensation with cleanser at week 2, despite experiencing greater sensation at baseline compared to white counterparts (Fitz I-III, $n=38$) (Figure 3B). These results were consistent with the significant improvement in quality-of-life perceived by all AD subjects (Figure 4A & 4B). Xerosis subjects perceived significant increase in itching sensation with cleanser alone at 2 weeks, reaching complete relief with regimen by week 8 (Figure 3A). Despite

experiencing this initial increase in itch sensation, xerosis patients perceived a significant reduction in itching intensity levels with cleanser alone at week 2, and with regimen by week 10 (Figure 3C). Interestingly, xerosis patients of color (Fitz IV-VI, $n=25$) showed earlier reduction in itching intensity (Figure 3D), while white counterparts (Fitz I-III, $n=44$) showed greater improvement in quality-of-life with cleanser alone and with regimen overtime (Figure 4A & 4C).

FIGURE 2. Prebiotic cleanser and moisturizer routine strengthens skin barrier properties in atopic dermatitis and xerosis patients. Change in (A) skin hydration and (B) pH in AD and in xerosis patients (C & D) overtime.

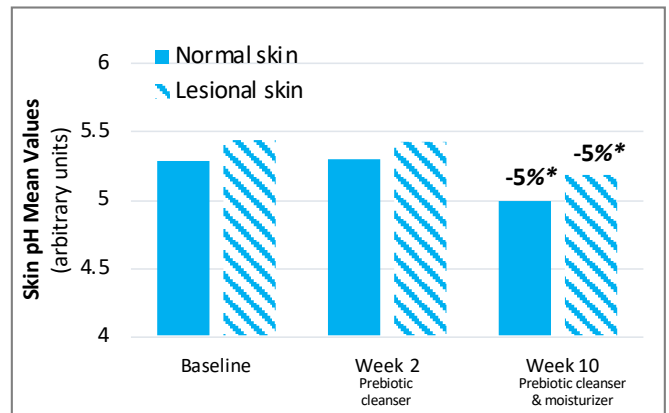
(A)

Skin Hydration in Atopic Dermatitis Patients Overtime



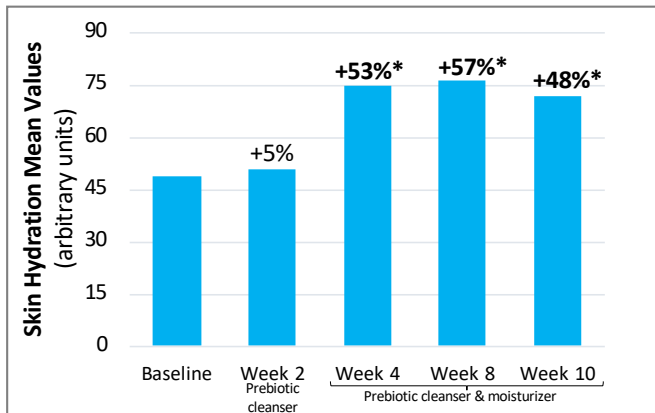
(B)

Skin pH in Atopic Dermatitis Patients Overtime



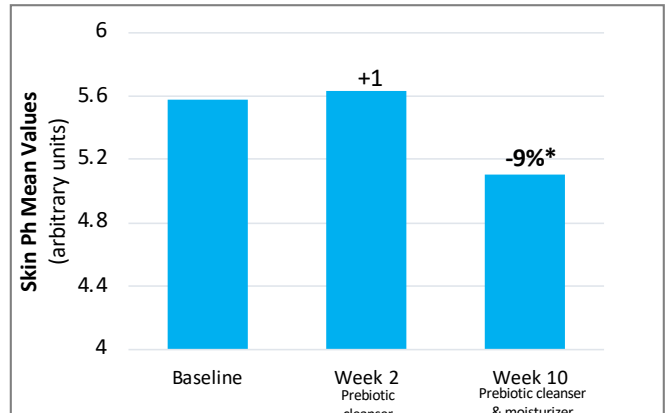
(C)

Skin Hydration in Xerosis Patients Overtime



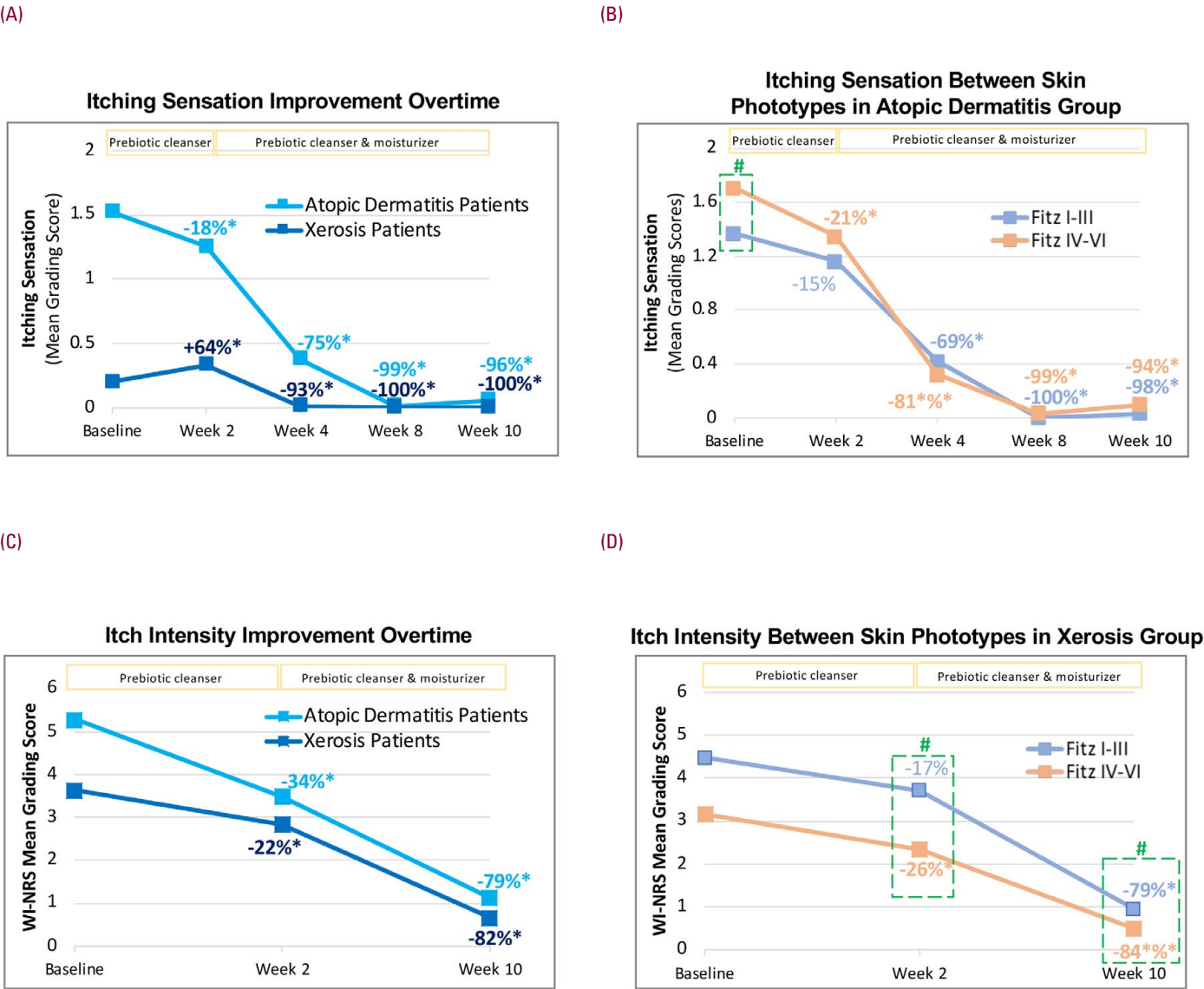
(D)

Skin pH in Xerosis Patients Overtime



*denotes $P < .05$ vs. Baseline.

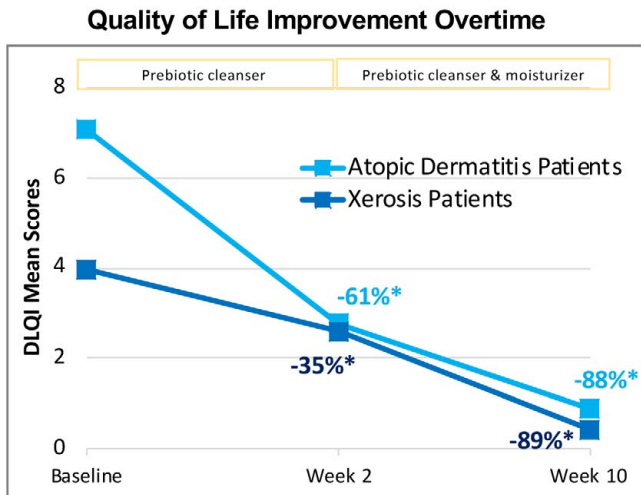
FIGURE 3. Prebiotic cleanser and moisturizer routine provides itch relief in atopic dermatitis and xerosis patients. Improvement in (A & C) itch sensation & (B & D) intensity between skin conditions and by skin phototype subgroups overtime.



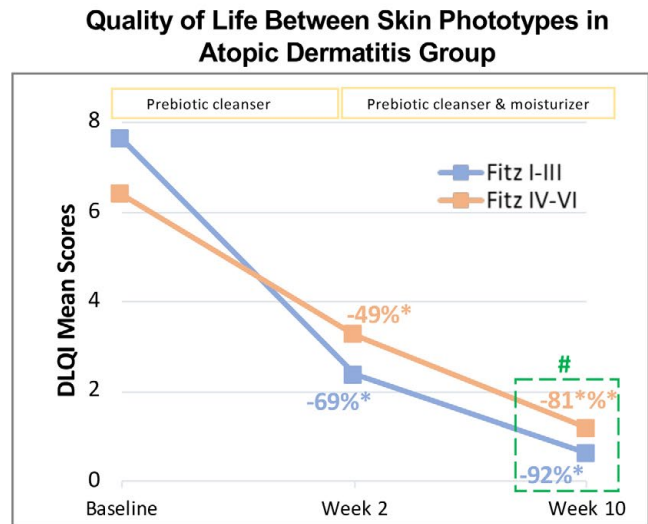
*denotes $P < .05$ vs. Baseline, and # denotes $P < .05$ between Fitz IV-VI vs. Fitz I-III.

FIGURE 4. Prebiotic cleanser and moisturizer routine improves quality-of-life in atopic dermatitis and xerosis patients. (A) Improvement in quality-of-life between skin conditions and by skin phototype subgroups for (B) AD and (C) xerosis patients overtime.

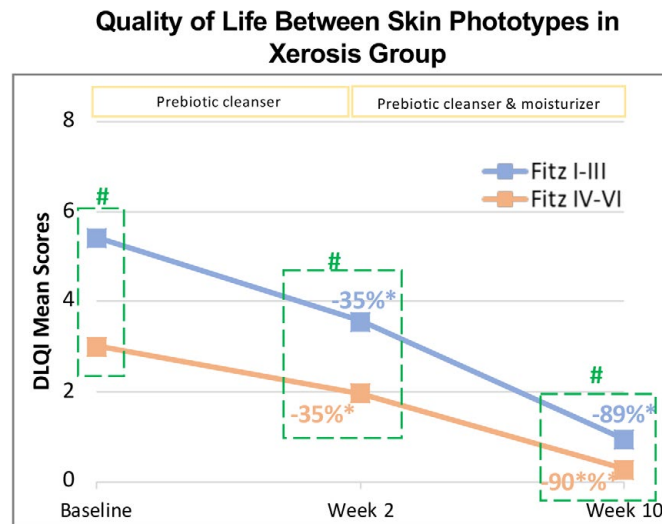
(A)



(B)

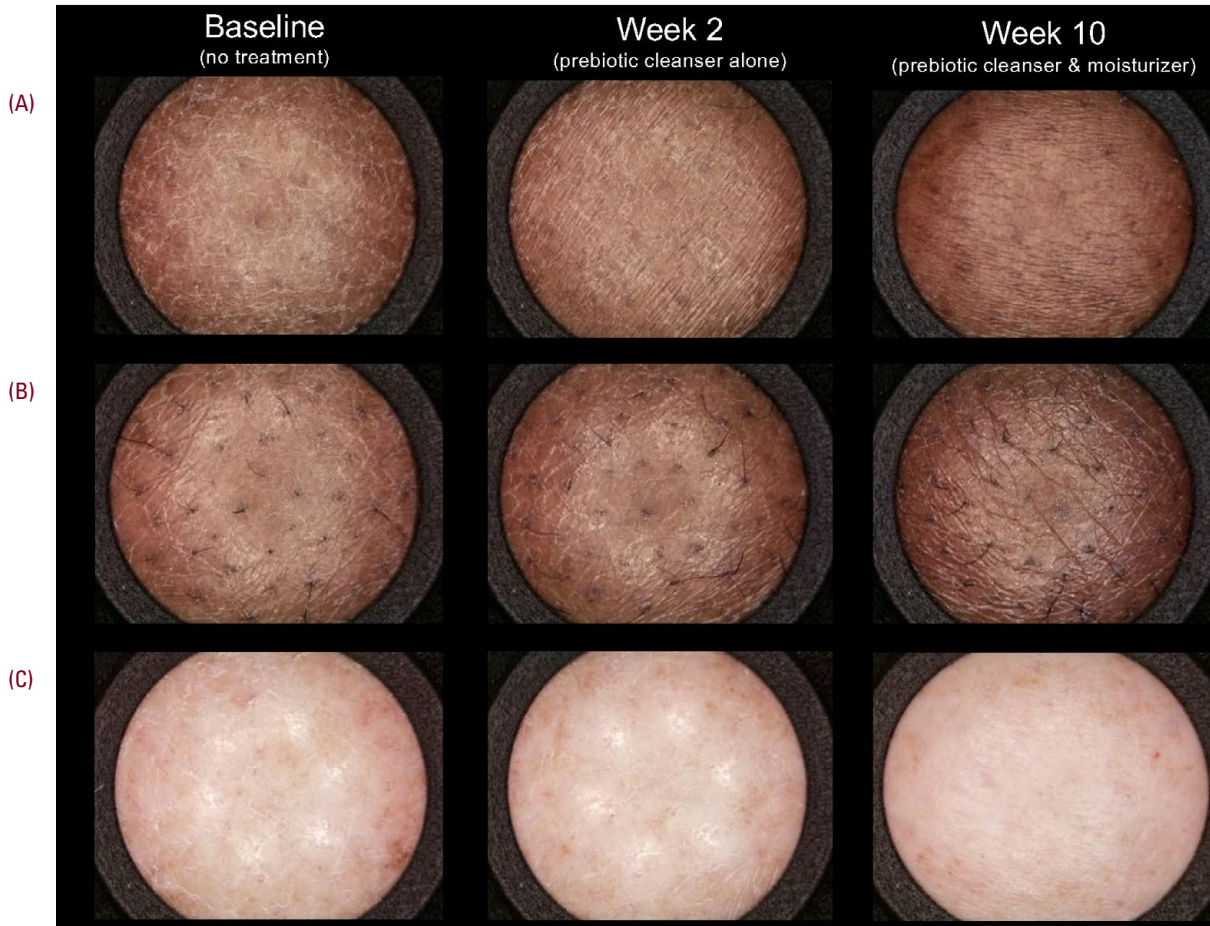


(C)



*denotes $P<.05$ vs. Baseline, and # denotes $P<.05$ between Fitz IV-VI vs. Fitz I-III.

FIGURE 5. Representative images of atopic dermatitis and xerosis patients captured by SkinCam®. (A) Improvement of xerosis and **(B & C)** AD in ethnically diverse patients following 10 weeks of prebiotic skincare routine treatment.



DISCUSSION

Variations in AD epidemiology, clinical presentation, and disease course between racial/ethnic sub-populations have been reported.⁴⁻¹² Despite higher incidence, SOC patients are under-represented in AD clinical trials.³⁷ Epidermal skin barrier impairment and imbalance in skin microbiome composition are known to play an essential role in AD pathophysiology.^{19-21,24,25} Prebiotic emollient treatments decreased AD symptoms and severity as well as increased skin barrier function by normalizing skin microbiota.^{21,27-34} Here, we first demonstrate the clinical efficacy of a prebiotic skincare routine, consisting of a cleanser and moisturizer, in improving mild-AD and severe xerosis in ethnically diverse patients.

Depending on the patient's age and AD severity, lesion distribution and appearance greatly vary.^{1,13,25} In individuals with melanin-rich skin, hyper- or hypopigmentation, plus greater visibility of scaling and dryness are distinct features of AD and xerosis.^{4-12,26} The lack of visible erythema on darker skin may challenge a proper diagnosis and undercount the severity of the disease.³⁹⁻⁴¹ In our study, we included two validated scales to assess AD severity, plus clinical imaging (Figure 5A-C) to document changes overtime. Dermatological evaluations, using IGA and EASI scales, demonstrated the significant improvement of global eczema appearance by the prebiotic skincare regimen in all AD subjects, regardless of race and ethnicity (Figure 1B & 1C). Notably, we observed a small but

significant reduction in global eczema severity only with EASI scale with cleanser alone at week 2 (Figure 1C). Additionally, expert grading of both visual and tactile skin roughness showed significant improvement with prebiotic regimen in all patients starting at week 4, plus significant reduction in skin desquamation levels in xerosis group (data not shown). In alignment with prior reports, our results suggest that both scales can be used to assess AD severity in ethnically diverse patients.^{41,42}

Skin barrier dysfunction is associated with decrease skin hydration, plus elevated TEWL and skin pH levels, which all have been linked to inflammatory skin diseases, including AD and xerosis.¹⁷ Under *in vitro* conditions, higher pH levels were shown to promote *S. aureus* growth, suggesting that an acidic skin environment favors a balance skin microbiome for healthier skin.⁴³ Recently, higher TEWL and skin pH levels were observed to be associated with increased likelihood for flare-up in AD patients compared to healthy subjects.⁴⁴ Though no change in TEWL was observed, we demonstrated that the prebiotic skincare regimen significantly increased skin hydration and decreased pH levels in all xerosis subjects (Figure 2C & 2D). Interestingly, similar changes were observed in both normal and lesional skin of AD patients (Figure 2A& 2B), indicating that the prebiotic skincare regimen favors an acidic pH gradient to promote skin barrier strength and repair, plus normalize skin microbiota overtime.

Reported differences in skin barrier characteristics in racial/ethnic populations have been suggested.^{17,45-49} For instance, Young et al, showed that South African subjects had higher stratum corneum hydration and skin surface pH levels compared to Caucasian counterparts.⁴⁶ Another study demonstrated that following tape-stripping, epidermal barrier recovery was faster in individuals with skin phototype V/VI, independent of race, compared to individuals with lower skin phototypes.⁴⁸ Under our study conditions, no significant differences in assessed skin barrier properties were observed between racial/ethnic sub-populations in both AD and xerosis groups (Figure 2A-2D). Inconsistencies between studies results emphasize the need for further research to determine the variations in epithelial barrier properties between racial/ethnic groups and their clinical relevance to various skin conditions.

AD is associated with a significant patient-burden and impact on quality-of-life.¹⁻⁴ Commonly burdensome AD symptoms include itch and pain from scratching, excessive dryness/scaling, and red/inflamed skin.^{2,3} In SOC, AD-related symptoms, such as itch, pigmentary sequelae and scarring, may be more stigmatizing compared to white counterparts.^{4-9,50-52} Through a real-world cross-sectional study, Silverberg et al., demonstrated that black and Hispanic AD patients, enrolled in the CorEvitas AD Registry (July 2020-July 2021), showed significant higher itch sensation compared to white counterparts.⁵⁰ Another study demonstrated that US nonwhite veterans associated greater burning sensation and scarring with their itch, plus experienced greater emotional impact than white counterparts.⁵¹ Consistent with these reports, we found that AD patients of color experienced greater itching sensation than white counterparts at baseline (Figure 3B), while xerosis patients of color observed greater reduction in itching intensity levels with prebiotic cleanser alone and regimen overtime (Figure 3D). Additionally, though all subjects perceived significant improvement in quality-of-life with prebiotic cleanser alone and regimen (Figure 4A), xerosis white patients experienced worse quality-of-life at baseline and greater improvement overtime than SOC counterparts (Figure 4C). These interesting findings could be attributed to the variations in skin barrier properties between racial/ethnic group, contributing to itch and xerosis, and to the cultural norms and preferences influencing the patient's coping strategy to manage and treat skin condition.^{45,50,53,54}

CONCLUSION

Collectively, our results demonstrate that a prebiotic skincare routine can effectively manage AD and xerosis-related symptoms to prevent long-term sequelae in diverse ethnically patients by reducing condition severity, strengthening skin barrier properties in both lesional and normal skin, while providing relief from itching sensation and improving patients' quality of life. The nuances observed in our study between racial/ethnic populations help support clinicians on disease management strategies to consider, plus advocate for patient preferences for better treatment outcomes, particularly for patients of color.

DISCLOSURES

Dr Zoe Diana Draelos MD is a researcher and consultant for L’Oreal.

All other authors are employees of La Roche-Posay Laboratoire Dermatologique.

ACKNOWLEDGMENT

We thank Dr. Stephen Lynch, Mohammedali Sajun, and Komal Patel for their partnerships, plus Dr. Chesahna Kindred, Dr. Cheri N. Frey, Dr. George Han, Dr. Neal Bhatta and Dr. Katrina Abuabara for their valuable feedback on study design.

REFERENCES

- Silverberg JI, Nelson DB, Yosipovitch G. Addressing treatment challenges in atopic dermatitis with novel topical therapies. *J Dermatolog Treat.* 2016 Nov;27(6):568-576.
- Silverberg JI, Gelfand JM, Margolis DJ, et al. Patient burden and quality of life in atopic dermatitis in US adults A population-based cross-sectional study. *Ann Allergy Asthma Immunol.* 2018;121(3):340-347.
- Silverberg JI. Comorbidities and the impact of atopic dermatitis. *Ann Allergy Asthma Immunol.* 2019;123(2):144-151
- Brunner PM, Guttman-Yassky E. Racial differences in atopic dermatitis. *Ann Allergy Asthma Immunol.* 2019;122(5):449-455.
- Kaufam BP, Guttman-Yassky E, Alexis AF. Atopic dermatitis in diverse racial and ethnic groups—Variations in epidemiology, genetics, clinical presentation and treatment. *Exp Dermatol.* 2018;27(4):340-357
- Sanfilippo E, Iyer S, Patel N, et al. Assessment of racial and ethnic differences of atopic dermatitis severity and treatment patterns in a diverse outpatient cohort in the United States: a retrospective observational study. *Arch Dermatol Res.* 2023;315(10):2829-2832. doi: 10.1007/s00403-023-02696-1.
- Gan C, Mahil S, Pink A, et al. Atopic dermatitis in skin of colour. Part 1: new discoveries in epidemiology and pathogenesis. *Clin Exp Dermatol.* 2023;48(6):609-616.
- Mei-Yen Young A, Tay Y. Atopic Dermatitis: Racial and Ethnic Differences. *Dermatol Clin.* 2017;35(3):395-402.
- Croce EA, Levy ML, Adamson AS, et al. Reframing racial and ethnic disparities in atopic dermatitis in Black and Latinx populations. *J Allergy Clin Immunol.* 2021;148(5):1104-1111.
- Shaw TE, Currie GP, Koudelka CW, et al. Eczema prevalence in the United States: data from the 2003 National Survey of Children's Health. *J Invest Dermatol.* 2011;131(1):67-73.

- Janumpally SR, Feldman SR, Gupta AK, et al. In the United States, blacks and Asian/Pacific Islanders are more likely than whites to seek medical care for atopic dermatitis. *Arch Dermatol.* 2002;138(5):634-7.
- Narla S, Hsu DY,Thyssen JP,et al. Predictors of hospitalization, length of stay, and costs of care among adult and pediatric inpatients with atopic dermatitis in the United States. *Dermatitis.* 2018;29(1):22-31.
- Czarnowicki T, He H, Krueger JG, et al. Atopic dermatitis endotypes and implications for targeted therapeutics. *J Allergy Clin Immunol.* 2019;143(1):1-11.
- Kabashima-Kubo R, Nakamura M, Sakabe J, et al. A group of atopic dermatitis without IgE elevation or barrier impairment shows a high Th1 frequency: possible immunological state of the intrinsic type. *J Dermatol Sci.* 2012;67(1):37-43.
- Park J, Choi Y, Namkung J, et al. Characteristics of extrinsic vs. intrinsic atopic dermatitis in infancy: correlations with laboratory variables. *Br J Dermatol.* 2006;155(4):778-83.
- Paller AS, Kong HH, Seed P, et al. The microbiome in patients with atopic dermatitis. *J Allergy Clin Immunol.* 2019;143(1): 26–35.
- Baldwin HE, Bhatia ND, Friedman A, et al. The role of cutaneous microbiota harmony in maintaining a functional skin barrier. *J Drugs Dermatol.* 2017;16(1):12-18.
- Byrd AL, Belkaid Y, Segre JA. The human skin microbiome. *Nat Rev Microbiol.* 2018;16(3):143-155.
- Bjerre RD, Holm, JB, Palleja A, et al. Skin dysbiosis in the microbiome in atopic dermatitis is site-specific and involves bacteria, fungus and virus. *BMC Microbiol.* 2021;21(1):256.
- Simpson EL, Villarreak M, Jepson B, et al. Atopic dermatitis subjects colonized with staphylococcus aureus have a distinct phenotype and endotype. *J Invest Dermatol.* 2018; 138(10): 2224–2233.
- Seite S, Flores GE, Henley JB, et al. Microbiome of affected and unaffected skin of patients with atopic dermatitis before and after emollient treatment. *J Drugs Dermatol.* 2014;13(11):1365-72.
- Meylan P, Lang C, Mermoud S, et al. Skin colonization by Staphylococcus aureus precedes the clinical diagnosis of atopic dermatitis in infancy. *J Invest Dermatol.* 2017;137(12):2497–504.
- Kennedy EA, Gallagher A, Hourihane JO, et al. Skin microbiome alterations in infants before clinical atopic dermatitis. *J Invest Dermatol.* 2016;136(5):S84.
- Chandra J, Retuerto M, Seite S, et al. Effect of an emollient on the mycobiome of atopic dermatitis patients. *J Drugs Dermatol.* 2018;17(10):1039-1048.
- Del Rosso JQ, Harper J, Kircik L, et al. Consensus recommendations on adjunctive topical management of atopic dermatitis. *J Drugs Dermatol.* 2018;17(10):1070-1076.
- Alexis a, Woolery-Lloyd H, Andriessen A, et al. Insights in skin of color patients with atopic dermatitis and the role of skincare in improving outcomes. *J Drugs Dermatol.* 2022;21(5):462-470.
- Mahe YF, Perez M, Tacheau C, et al. A new Vitreoscilla filiformis extract grown on spa water-enriched medium activates endogenous cutaneous antioxidant and antimicrobial defenses through a potential Toll-like receptor 2/protein kinase C, zeta transduction pathway. *Clin Cosmet Investig Dermatol.* 2013;6:191-6.
- Volz T, Skabytska Y, Guenova E, el al. Nonpathogenic bacteria alleviating atopic dermatitis inflammation induce IL-10-producing dendritic cells and regulatory Tr1 cells. *J Invest Dermatol.* 2014;134(1):96-104.

29. Gueniche A, Knaudt B, Schuck E, et al. Effects of nonpathogenic gram-negative bacterium *Vitreoscilla filiformis* lysate on atopic dermatitis: a prospective, randomized, double-blind, placebo-controlled clinical study. *Br J Dermatol*. 2008;159(6):1357-63.
30. Seite S, Zelenkova H, Martin R. Clinical efficacy of emollients in atopic dermatitis patients' relationship with the skin microbiota modification. *Clin Cosmet Investig Dermatol*. 2017;10:25-33
31. Zelenkova H, Kerob D, Salah S, et al. Impact of daily use of emollient 'plus' on corticosteroid consumption in patients with atopic dermatitis: An open, randomized controlled study. *J Eur Acad Dermatol Venereol*. 2023 Jun;37 Suppl 5:27-34.
32. Magnolo N, Jaenicke T, Tsianakas A, et al. Comparison of different skin care regimens in patients with moderate to severe atopic dermatitis receiving systemic treatment: A randomized controlled trial. *J Eur Acad Dermatol Venereol*. 2023;37 Suppl 5:18-26.
33. Wollenberg A, Kinberger M, Arents B, et al. European guideline (EuroGuiDerm) on atopic eczema: part I - systemic therapy. *J Eur Acad Dermatol Venereol*. 2022;36(9):1409-1431.
34. Wollenberg A, Kinberger M, Arents B, et al. European guideline (EuroGuiDerm) on atopic eczema - part II: non-systemic treatments and treatment recommendations for special AE patient populations. *J Eur Acad Dermatol Venereol*. 2022;36(11):1904-1926.
35. Bieber T, D'Erme AM, Akdis CA, et al. Clinical phenotypes and endo-phenotypes of atopic dermatitis: Where are we, and where should we go? *J Allergy Clin Immunol*. 2017;139(4S):S58-S64
36. Merriman JA, Mueller EA, Cahill MP, et al. Temporal and racial differences associated with atopic dermatitis staphylococcus aureus and encoded virulence factors. *mSphere*. 2016;1(6):e00295-16.
37. Hirano SA, Murray SB, Harvey VM. Reporting, representation, and subgroup analysis of race and ethnicity in published clinical trials of atopic dermatitis in the United States Between 2000 and 2009. *Pediatr Dermatol*. 2012 Nov-Dec;29(6):749-55.
38. Maudet A, Le Bec J, Flament F, et al. Analysis of images supplied by Skincam® can record the changes of some scar features that occur over time. Comparisons with the assessments of dermatologist and patients' perception. *J Cosmet Dermatol*. 2023;22(4):1334-1343.
39. Chansky PB, Mittal L, Werth VP. Dermatological evaluation in patients with skin of colour: the effect of erythema on outcome measures in atopic dermatitis. *Br J Dermatol*. 2017;176(4):853-854.
40. Wilson BN, Alexis A, Murase JE. Art of prevention: Atopic dermatitis in women and families of color-prevalence, recognition, and prevention. *Int J Womens Dermatol*. 2022;8(1):e014.
41. Zhao CY, Hao EY, Oh DD, et al. A comparison study of clinician-rated atopic dermatitis outcome measures for intermediate- to dark-skinned patients. *Br J Dermatol*. 2017;176(4):985-992.
42. Schmitt J, Langan S, Deckert S, et al. Assessment of clinical signs of atopic dermatitis: a systematic review and recommendation. *J Allergy Clin Immunol*. 2013;132(6):1337-47.
43. Iyer V, Raut J, Dasgupta A. Impact of pH on growth of *Staphylococcus epidermidis* and *Staphylococcus aureus* in vitro. *J Med Microbiol*. 2021;70(9).
44. Marini A, Aue N, Demessant A, et al. Increased skin pH and transepidermal water loss may serve as predictor for atopic dermatitis flares. *J Eur Acad Dermatol Venereol*. 2023;37(2):e252-e254.
45. Wan DC, Wong VW, Longaker MT, et al. Moisturizing different racial skin types. *J Clin Aesthet Dermatol*. 2014;7(6):25-32.
46. Young MM, Franken A, du Plessis JL. Transepidermal water loss, stratum corneum hydration, and skin surface pH of female African and Caucasian nursing students. *Skin Res Technol*. 2019;25(1):88-95.
47. Berardesca E, Pirot F, Singh M, et al. Differences in stratum corneum pH gradient when comparing white Caucasian and black African-American skin. *Br J Dermatol*. 1998;139(5):855-7.
48. Reed JT, Ghadially R, Elias PM. Skin type, but neither race nor gender, influence epidermal permeability barrier function. *Arch Dermatol*. 1995;131(10):1134-8.
49. Muizzuddin N, Hellemans L, Van Overloop L. Structural and functional differences in barrier properties of African American, Caucasian and East Asian skin. *J Dermatol Sci*. 2010;59(2):123-8.
50. Silverberg JI, Shi VY, Alexis A, et al. Racial and ethnic differences in sociodemographic, clinical, and treatment characteristics among patients with atopic dermatitis in the United States and Canada: real-world data from the CorEvitas atopic dermatitis registry. *Dermatol Ther (Heidelb)*. 2023;13(9):2045-2061.
51. Shaw FM, Luk KMH, Chen KH, et al. Racial disparities in the impact of chronic pruritus: A cross-sectional study on quality of life and resource utilization in United States veterans. *J Am Acad Dermatol*. 2017;77(1):63-69.
52. Ingrasci G, El-Kashlan N, Alexis A, et al. Chronic itch in African Americans: an unmet need. *Arch Dermatol Res*. 2022;314(5):405-415.
53. Alexis AF, Woolery-Lloyd H, Williams K, et al. Racial/Ethnic variations in skin barrier: implications for skin care recommendations in skin of color. *J Drugs Dermatol*. 2021;20(9):932-938.
54. Crudele J, Kim E, Murray K, et al. The importance of understanding consumer preferences for dermatologist recommended skin cleansing and care products. *J Drugs Dermatol*. 2019;18(1s):s75-79

AUTHOR CORRESPONDENCE

Hawasatu Dumbuya PhD

E-mail:..... hawasatu.dumbuya@loreal.com

