

A SUPPLEMENT TO

JOURNAL OF DRUGS IN DERMATOLOGY

JDD

DRUGS • DEVICES • METHODS

REAL-WORLD PATIENT CASES
USING BOTANICAL SERUM-CONTAINING
CORRECTIVE GEL AS AN ADJUNCT
TO AESTHETIC FACIAL ENERGY-BASED
DEVICE TREATMENTS

This supplement to the *Journal of Drugs in Dermatology* is supported by SkinCeuticals International- L'Oréal Groupe.

Real-World Patient Cases Using Botanical Serum-Containing Corrective Gel as an Adjunct to Aesthetic Facial Laser or Microneedling Radiofrequency (MRF) Treatment

Michael Gold MD FAAD,^a Sonya Abdulla MD FAAD,^b Anneke Andriessen PhD,^c Vivian Bucay MD FAAD,^d Ariel Haus MD,^e Qin Xiaolei MD,^f Todd Schlesinger MD FAAD,^g Weimin Song MD,^h Hua Zhong MDⁱ

^aGold Skin Care Center, Nashville, TN

^bDermatology on Bloor, Toronto, Ontario, Canada;

^cUMC Radboud, Nijmegen, Andriessen Consultants, Malden, The Netherlands; ^dBucay Dermatology and Aesthetics, San Antonio, TX;

^eDr Haus Dermatology, London, UK; ^fDEYI SKIN Dermatology Clinic, Shenzhen, China;

^gClinical Research Center of the Carolinas, Charleston, SC; ^hYes Skin Clinic Chain, Hangzhou, Zhejiang, China;

ⁱDermatology and Aesthetics Center of Distinct Health Care, China

ABSTRACT

Integrated skin care is defined as the complementary use of topical treatments to nonsurgical facial rejuvenation procedures, such as lasers and radiofrequency microneedling devices, to produce pleasing aesthetic results. Real-world experience from expert dermatologists is invaluable in guiding patient treatment plans, as there are limited clinical trials on the efficacy of integrated skincare regimens. The SkinCeuticals (New York, NY) Phyto Corrective gel (botanical serum-containing corrective gel) contains a lightweight botanical serum that hydrates, calms, and soothes skin. It contains antioxidant and anti-inflammatory ingredients derived from plant and fruit extracts, making it an appealing option for adjunctive treatment of post-procedure erythema and swelling.

J Drugs Dermatol. 2024;23:3(Suppl 2):s3-14.

INTRODUCTION

Skin aging is a natural process that occurs due to oxidative stress and cumulative DNA damage in cells that leads to unwanted changes in the skin, such as atrophy, laxity, wrinkling, dryness, abnormal pigmentation, and overall reduced brightness.¹ Changes to aging skin occur as a result of a combination of exogenous and endogenous factors. Endogenous factors include genetic background, decreased estrogen, androgen, and growth hormones, decreased collagen production, and breakdown of the elastin network, whereas exogenous factors include sun exposure, smoking, inflammation, psychological stress, diet, medications, air pollutants, and comorbid illness.¹

Molecular Mechanisms of Skin Aging

While fundamental mechanisms of aging are poorly understood, inflammation and oxidative stress processes are known to play a significant role in the skin aging process. Intrinsic, chronological aging is generally associated with thinning of

the epidermis and dermis as well as loss of sensibility due to a reduction in sex hormones and a number of nerve endings. It is caused by the build-up of reactive oxygen species (ROS) that are produced through cellular oxidative metabolism. Solar radiation can accelerate the process by degrading skin matrix material, leading to wrinkles.² Antioxidants such as ubiquinol, vitamin E, and vitamin C are present in the skin to bind and reduce ROS; however, the skin's natural antioxidant defense system also diminishes with age.³ For these reasons, skin rejuvenation is achieved using treatments that stimulate neocollagenesis, neoelastinogenesis, and replenish antioxidants, to achieve fuller and brighter skin.

Combating Skin Aging

Cosmetic rejuvenation and enhancement in dermatology has seen a dramatic expansion in use and popularity in recent decades.⁴ Interestingly, all patient age groups demonstrate equal interest in nonsurgical facial rejuvenation procedures

TABLE 1.

Botanical Corrective Gel Blend Composition	
Botanical Extract	Active Ingredient & Mechanism
Cucumber (<i>Cucumis sativus</i>)	Fruit extract with high vitamin C and amino acid content that nourishes and hydrates skin
Thyme (<i>Thymus vulgaris</i>)	Flower/leaf extract contains thymol, a strong antioxidant with free radical scavenging action
Olive (<i>Olea europaea</i>)	Leaf extract rich in antioxidants with anti-inflammatory effects in vitro
Mulberry (<i>Morus alba</i>)	Root extract is rich in flavones with tyrosinase inhibitor actions that help lighten skin
Grapefruit (<i>Citrus grandis</i>)	Fruit extract that is rich in vitamin A and C that impart astringent properties to skin
Rosemary (<i>Rosmarinus officinalis</i>)	Leaf extract enriched in polyphenols and shown to have antioxidant and anti-inflammatory activity in vitro

such as chemical peels, laser rejuvenation, and neuromodulator injections.⁵ While younger patients historically have sought care, primarily for acne scarring and tattoo removal, they are increasingly seeking non-invasive enhancement procedures that will fight the earliest signs of aging and brighten skin while accommodating busy lifestyles that do not allow for downtime after procedures.⁵ Having few existing algorithms, cosmetic dermatology requires personalized treatment plans for each patient case.

Integrated skin care is the personalized and complementary use of topical treatments and nonsurgical facial rejuvenation procedures such as lasers and microneedling radiofrequency (MRF) to produce optimal aesthetic results. Ablative, non-ablative, and fractional lasers are the most commonly used lasers in facial skin rejuvenation.⁶ Lasers generally heat the skin layers to resurface the epidermis and stimulate collagen synthesis in the dermis.⁴ Ablative lasers (CO₂, Er: YAG) are more aggressive treatments that thermally ablate and vaporize the epidermis, heat the dermis to tighten the skin bed, and treat severe facial wrinkles and pigmentation.⁴ Non-ablative lasers (intense pulsed light [IPL]), infrared, vascular, ultrasound, and radiofrequency [RF] devices) target the dermis to stimulate collagen synthesis without affecting the epidermis.⁴ Fractional lasers may be ablative or non-ablative and work by delivering small columns of epidermal destruction while sparing injury to spaces between columns.⁴ MRF delivers RF currents through insulated needles to produce thermal zones in the skin without damaging the overlying epidermis. MRF leads to lasting dermal remodeling, elastin, and collagen synthesis.¹

Complications of Skin Rejuvenation Techniques and Integrated Skin Care

Common complications of laser and MRF treatments include bruising, edema, itching, crusting, erythema, and pigment changes.⁴ Erythema is to be expected after almost any procedure using an energy device and can be worse in more aggressive treatments or patients with a history of rosacea or “sensitive skin.”⁴ The risk of adverse events depends on the type of laser used, the area treated, patient skin type, and treatment goals.

In general, ablative and fractional lasers carry a greater risk of adverse events than non-ablative ones. Combining topical treatments as adjunctive therapy can help mitigate the adverse effects of lasers and provide supportive skincare practices to improve patient quality of life and results.¹ In this way, the integrated skincare approach optimizes clinical outcomes and increases patient comfort, satisfaction, and commitment to treatment goals.

Botanical Serum-Containing Corrective Gel

The botanical serum-containing corrective gel (botanical corrective gel) (Phyto Corrective gel, SkinCeuticals) is a lightweight botanical serum composed of 9.5% glycerin, 4.5% botanical extracts, and 0.2% hyaluronic acid, that hydrates, calms and soothes irritated skin to help reduce visible redness. The botanical corrective gel blend combines 6 botanical extracts, cucumber, thyme, and extracts of olive and mulberry leaves, to decrease inflammation, draw in moisture, and support the skin's barrier function (Table 1). Combining these ingredients produces synergistic anti-inflammatory and antioxidant effects on the skin. In vitro studies have demonstrated significant downregulation of inflammatory cytokine IL-8 expression in botanical corrective gel blend-treated cells (unpublished data). This suggests efficacious disruption of an inflammatory axis by the botanical corrective gel blend ingredients. Clinically, the botanical corrective gel has been shown to ameliorate inflammation and redness after rejuvenating procedures, thereby reducing post-procedure healing times.⁷ The anti-inflammatory antioxidant properties of the botanical corrective gel make it an appealing option for an integrated skincare plan in patients undergoing energy-based rejuvenation procedures.

As more treatments become available, it will be important for clinicians to partner with their patients to develop integrated skincare plans to optimize outcomes and support desired enhancement treatment goals. Herein, selected real-world cases are presented to illustrate how adding botanical corrective gel as an adjunct to laser or MRF treatments leads to improved outcomes in a variety of patients.

MATERIALS AND METHODS**Aim of the Project**

This real-world case series was composed to highlight integrated skincare regimens with the botanical corrective gel. The cases demonstrate how expert dermatologists choose botanical corrective gel as an adjunct treatment to laser and MRF procedures to help accelerate post-procedure healing. The clinical reasoning and rationale from a panel of experts are detailed in the following patient cases to guide cosmetic dermatologists seeking to apply integrated skincare practices in their patients.

Steps in the Process

The real-world cases were compiled and selected in the following steps: 1) project definition and expert panel selection, 2) data collection and preparation of patient cases, 3) patient case discussion and selection for publication, 4) literature review to support selected cases, e) drafting, review, and finalization of the manuscript.

Role of the Panel

The selected expert panel consisted of 8 licensed dermatologists with collective worldwide experience in cosmetic and enhancement procedures. Panelists represented clinical practices from 3 different countries and have treated diverse patient populations in order to capture a wide variety of integrated skincare practices. During the World Congress of Dermatology in Singapore on July 8th, 2023, panelists met to report on and discuss patient cases where cosmetic procedures benefited from adjunctive use of botanical corrective gel. These real-world cases highlight experience with botanical corrective gel for cutaneous healing post-facial laser or MRF treatment.

The panel used the following template to gather insight through a case-based approach:

- a) Cosmetic Evaluation and Alignment of Treatment Goals
- b) Treatment Options (Device vs Topicals)
- c) Post-Procedure Recovery
 - a. Physician Clinical Assessment
 - b. Patient Self-Assessment and Impact on Patient Quality of Life
- d) Special Considerations

Integrated Skincare Regimen

After each rejuvenation procedure, physicians discussed skincare regimens with their patients. At this time, all patients were supplied with the products of interest: gentle cleanser, daily moisturizer, and botanical corrective gel. In general, patients were instructed to start applying the botanical corrective gel immediately after laser or MRF treatment. The skincare regimen included daily use of a gentle, non-irritating facial cleanser and moisturizer in addition to twice-daily application of the botanical corrective gel. The use of a daily, neutral broad-spectrum sunscreen was encouraged.

Data Gathering and Outcome Measures

Suggested information to present included patient demographics, clinical features, cosmetic treatment goals, and qualitative and quantitative outcome measures. Post-facial laser treatment patient outcome was tracked over 28 days at days 0, 2 (+/- 3 days), 7 (+/- 3 days), 14(+/- 3 days), and 28 (+/- 3 days). Outcome was evaluated based on physician assessment of facial erythema, oozing/crusting, discoloration, and epithelialization scores on a scale of 0 (none) to 4 (severe) (Table 2). Patients also self-evaluated their recovery in the following categories:

TABLE 2.

Post-Facial Laser or MRF Treatment- Physician Assessment							
Erythema		Oozing/Crusting Score		Discoloration		Epithelialization	
Item	Score	Item	Score	Item	Score	Item	Score
0 = None	--	0 = None	--	0 = None	--	0 = None	--
1 = Minimal - scant rare erythema	--	1 = Minimal - a single area of oozing or crusting	--	1 = Minimal	--	1 = minimal (small areas)	--
2 = Mild - pink coloration in some of the treatment area	--	2 = Mild - more than a single area of oozing or crusting	--	2 = Mild	--	2 = mild (1/4 of the face)	--
3 = Moderate - bright red color involving some of the treatment area or pink color involving all of the treatment area	--	3 = Moderate - one or more areas of oozing and crusting	--	3 = Moderate	--	3 = moderate (3/4 of the face)	--
4 = Severe - areas of very red coloration or bright red coloration of all of the treatment area	--	4 = Severe - congruent areas of oozing and crusting	--	4 = Severe	--	4 = complete (skin is healed)	--

TABLE 3.

Post-Facial Laser or MRF Treatment- Patient Assessment							
Redness		Oozing		Crusting		Downtime after the first treatment	
Item	Score	Item	Score	Item	Score	Item	Score
0 = None	--	0 = None	--	0 = None	--	0 = None	--
1 = Minimal	--	1 = Minimal	--	1 = Minimal	--	1 = 1 day	--
2 = Mild	--	2 = Mild	--	2 = Mild	--	2 = 2 days	--
3 = Moderate	--	3 = Moderate	--	3 = Moderate	--	3 = 5 days	--
4 = Severe	--	4 = Severe	--	4 = Severe	--	4 = >7 days	--
Skin discomfort	yes/no If yes, please provide details _____						
Impact of Post-Laser Facial Skin Condition	Impact: daily activities (yes/no), professional life (yes/no), social life (yes/no), self-image (yes/no) If answered yes, please provide details _____						
Skin condition has improved since last visit:	1 = Strongly Disagree, 2 = Disagree, 3 = Neutral, 4 = Agree, 5 = Strongly agree						

redness, oozing, crusting, skin discomfort, and recovery time on a scale from 0 (none) to 4 (severe). Qualitative responses were collected from patients on perceived post-facial laser skin condition and improvement over the follow-up period (Table 3).

RESULTS

Selected Real-World Cases

The expert panel selected 8 cases to illustrate real-world, integrated skincare regimens using botanical corrective gel in a diverse group of patients with varying cosmetic enhancement concerns and goals. These patient outcomes reflect real-world clinical use of botanical corrective gel as an adjunct therapy to laser and MRF therapy.

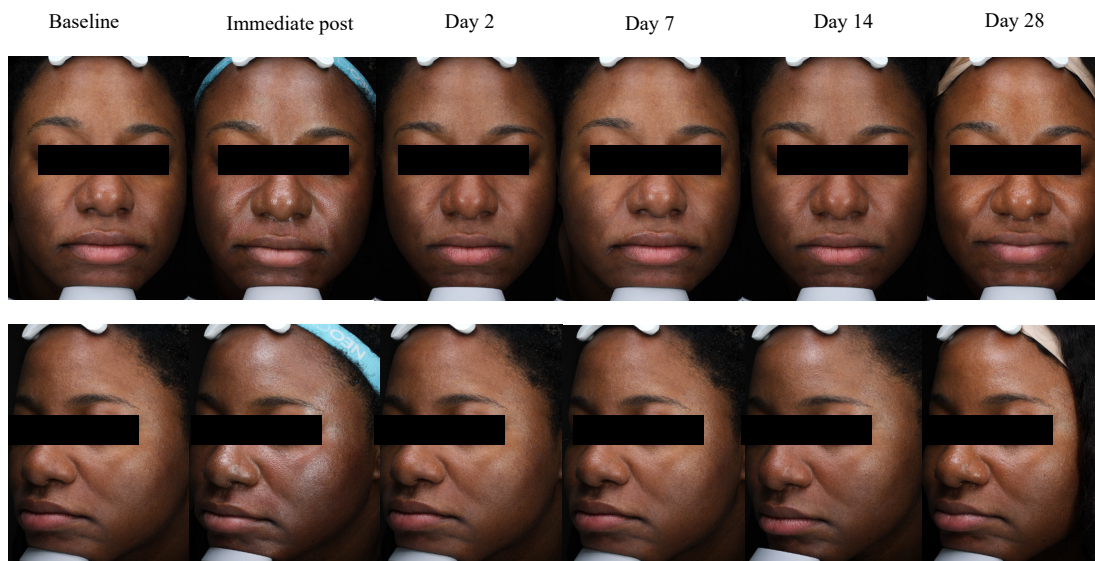
CASE 1

Laser/Energy-Based Procedure: Clear + Brilliant Non-Ablative Fractional Laser

Skin Care Complement: Botanical Corrective Gel

A 28-year-old female with Fitzpatrick Skin Type VI, presented with a concern of dull complexion. Without any notable past medical history, she was treated with Clear + Brilliant® laser to help with skin brightening. Immediately after treatment on day 0, the patient had mild erythema on her malar cheek surfaces. The botanical corrective gel was applied immediately after treatment and the patient was instructed to continue applying the gel twice daily in conjunction with her normal skin care.

FIGURE 1. Use of Clear + Brilliant non-ablative fractional laser and botanical corrective gel in the treatment of dull skin. *Photo Courtesy of Sonya Abdulla MD*



The patient saw complete resolution of redness by day 7 and saw a significant reduction in swelling by day 2 (Figure 1). She reported only 2 days of downtime due to mild edema and redness and felt that her skin had improved by day 7 post-laser treatment. After 14 days, the patient felt that her skin had improved significantly and reported high satisfaction with the laser and botanical corrective gel combination. She felt that her skin had “extra luminosity” and strongly agreed that her condition had improved.

CASE 2

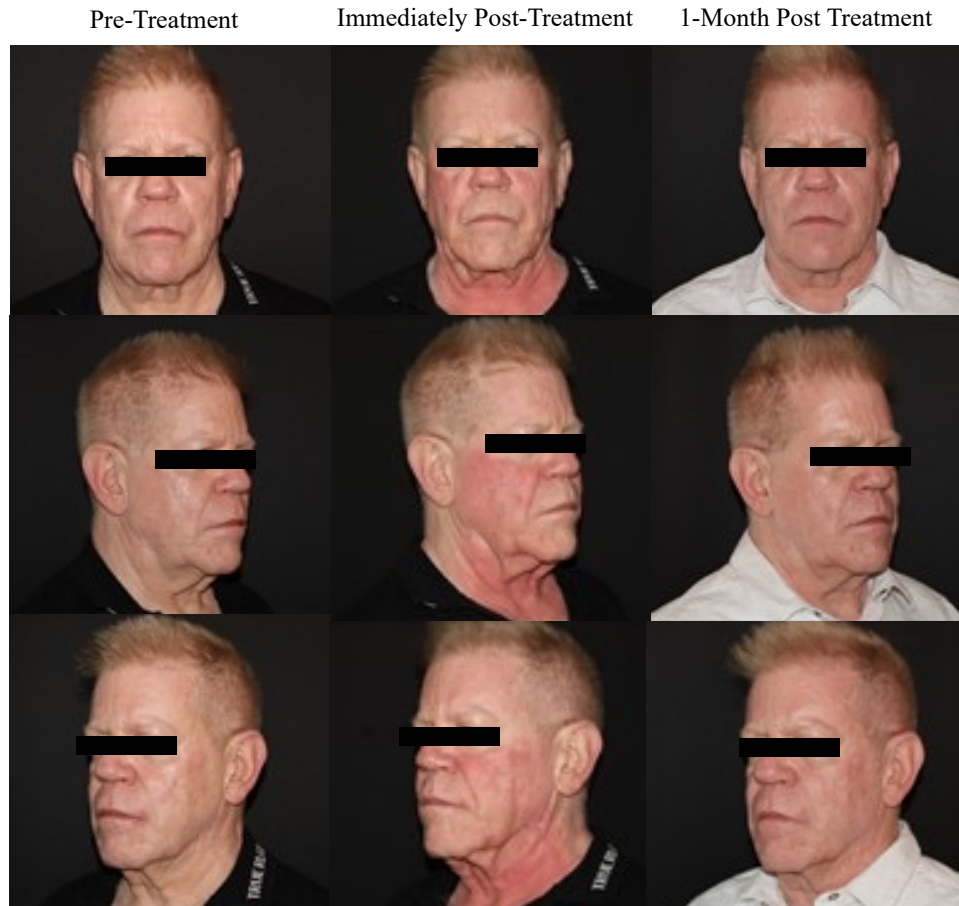Laser/Energy-Based Procedure: MRF, Fractional Thulium Fiber Laser

Skin Care Complement: Botanical Corrective Gel

A 66-year-old male, Fitzpatrick Skin Type II, presents for a cosmetic consultation with a concern of uneven skin, acne scarring, and facial rejuvenation. He also had a history of well-controlled seborrheic dermatitis. After counseling the patient

on the risks and benefits of the procedure, the patient decided on a combination MRF and fractional thulium fiber laser (FTL) at 1927 nm for treatment of his acne scarring and skin laxity. MRF and FTL offer synergistic skin rejuvenation; however, the combination is associated with post-procedure swelling and redness.⁸ Given this patient's skin type, it was recommended to combine the MRF/FTL treatment with adjuvant phyto corrective gel. After the procedure, the patient had significant erythema in the treated areas, to which botanical corrective gel was immediately applied. At day 0, he was given an erythema score of 3, oozing/crusting score of 1, and a discoloration score of 0 (refer to Table 2). Continuing to apply the phyto corrective gel twice daily, his erythema score decreased to 1 by day 2 and 0 by day 28 (Figure 2). At 1 month, the patient felt that his skin condition had strongly improved and reported no downtime after the procedure while using the phyto corrective gel. His skin felt tighter and he reported a healthier glow.

FIGURE 2. Cutaneous healing Post-MRF, fractional thulium fiber laser treatment with Botanical Corrective Gel with 66-year-old male with ST 2. *Photo Courtesy of Vivian Bucay MD*



CASE 3**Laser/Energy-Based Procedure: Fractional CO₂ Laser***Skin Care Complement: Botanical Corrective Gel*

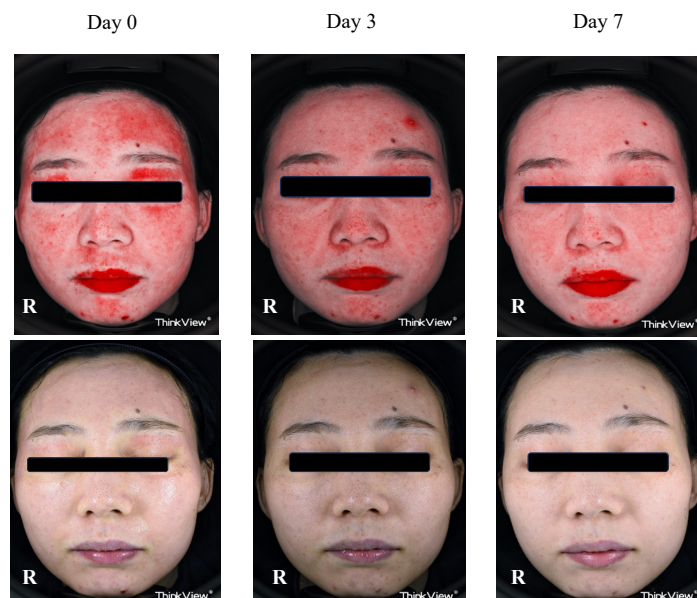
A 41-year-old male with Fitzpatrick Skin Type V presents with a history of cystic acne. He had no other relevant past medical history and requested treatment of his acne scars and large pores. The patient underwent fractional CO₂ laser for treatment and was counseled on adjunctive therapy with botanical corrective gel. On day 0, after his procedure, he had mild erythema (erythema score 1) with no oozing or discoloration. Botanical corrective gel was immediately applied post-procedure and by day 2, his erythema had resolved. He continued to apply the botanical corrective gel twice daily and reported rapid resolution of his erythema. In total, he only required 1 day of downtime after his treatment and appreciated the adjunctive use of the botanical corrective gel to help with reducing the symptoms of erythema and swelling. At the end of the 28 days, he felt that his skin condition had significantly improved.

CASE 4**Laser/Energy-Based Procedure: Clear + Brilliant® Non-Ablative Fractional Laser***Skin Care Complement: Botanical Corrective Gel*

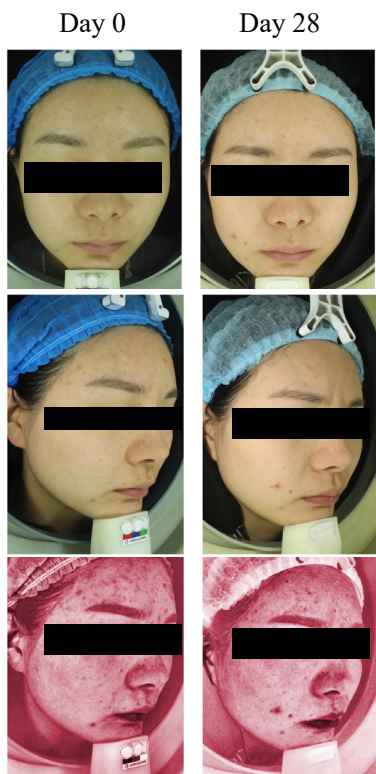
A 32-year-old woman, Fitzpatrick Skin Type III, presents with uneven skin and melasma. In the past, she had tried chemical peels, which were only minimally effective. At this time, the dermatologist proposed a more aggressive treatment with the Clear + Brilliant® non-ablative fractional laser. She received treatment with a 1927-nm laser at 5 mJ with 4-pass coverage. Using an integrated skincare approach, the clinician suggested the patient try botanical corrective gel on the right side of her face, twice daily for 1 week. After 1 week, the right side of the face receiving the botanical corrective gel had an erythema and crusting score of 0 while the non-treated side had an erythema and crusting score of 1. After 1 week, she was instructed to use the botanical corrective gel on her entire face with broad-spectrum sunscreen.

FIGURE 3. Fractional CO₂ laser in conjunction with botanical corrective gel in the treatment of acne scars in a 41-year-old male with Fitzpatrick Skin Type V. *Photo Courtesy of Ariel Haus MD*

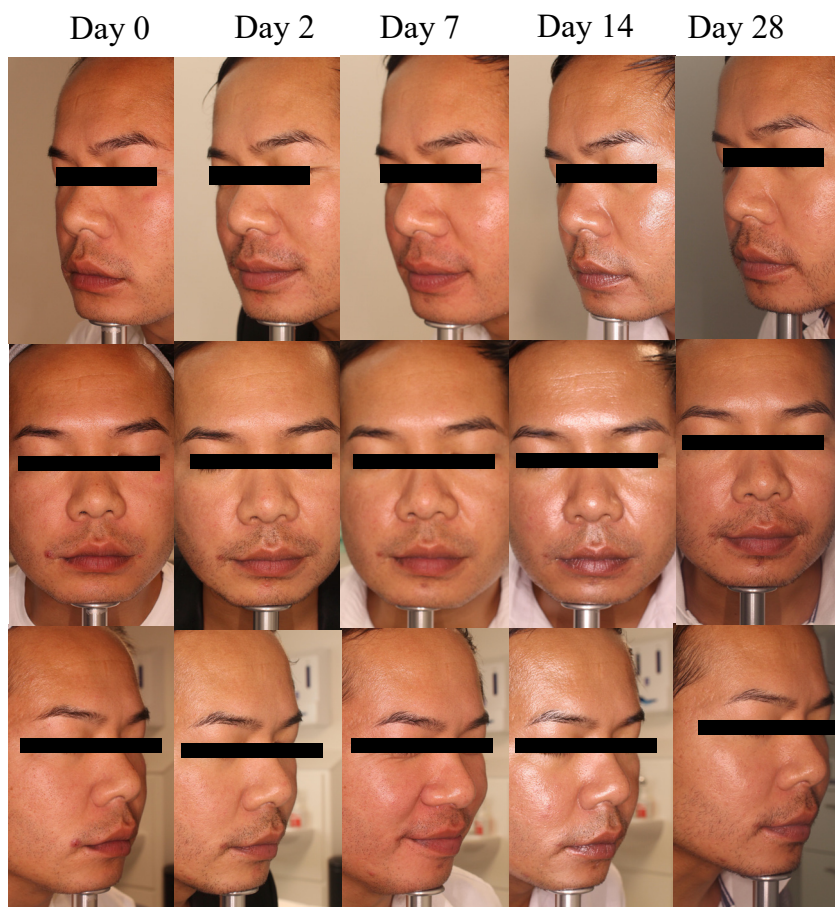

FIGURE 4. Split-face application of Botanical Corrective Gel over 7 days. *Photo Courtesy of Qin Xiaolei MD*

Right side (labeled R) received phyto corrective gel twice daily for 7 days post-facial laser treatment while the left side received only broad-spectrum sunscreen.

FIGURE 6. Use of M22™ IPL and Botanical Corrective Gel for treatment of comedonal acne. *Photo Courtesy of Weimin Song MD*

Right face is shown in the bottom two rows.

The botanical corrective gel visibly reduced erythema, edema, and crusting on treated skin. In addition, it notably reduced skin discomfort throughout the post-procedure period and provided a soothing sensation when applied.

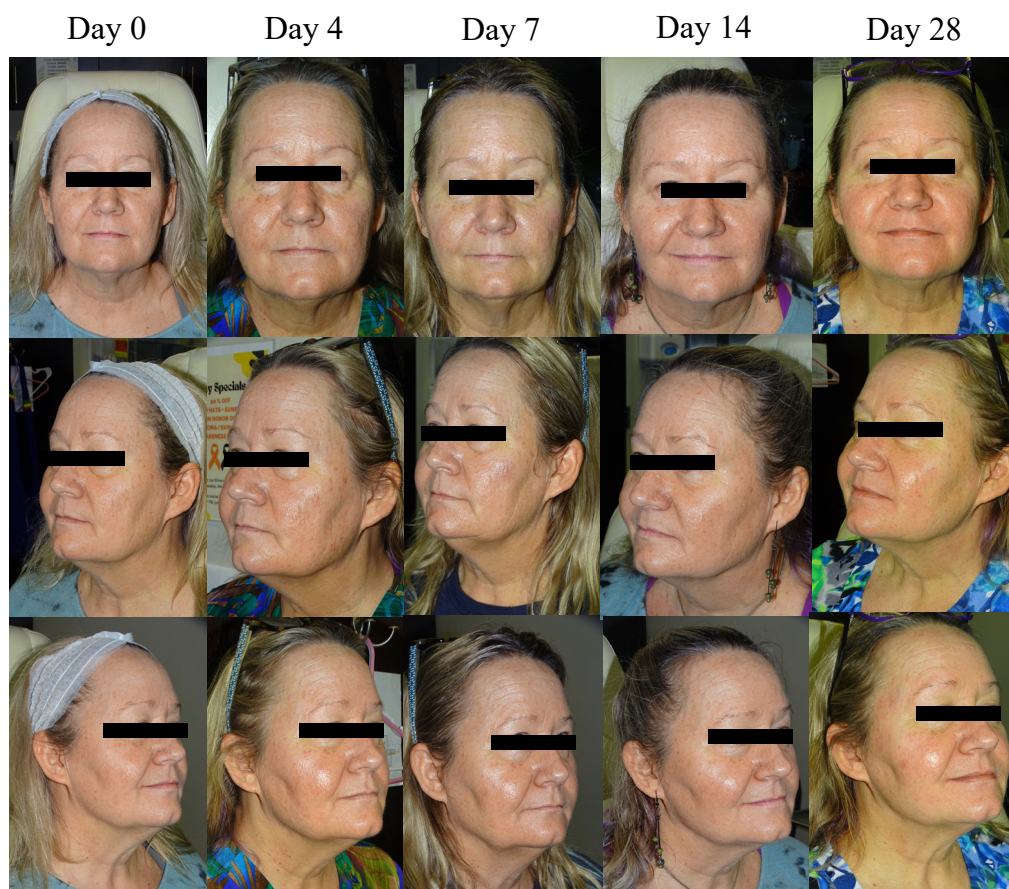Further, the patient reported feeling more comfortable having an adjunctive treatment that she could apply at home. In total, the patient had about 7 days of downtime until her skin was fully recovered. She denied any impact on her daily life, but refrained from her professional activities for 3 days and her social activities for 7 days. Overall, the patient reported great satisfaction with treatment results feeling that her skin was lightening 1-week post-laser treatment. At 1 month, she reported improved skin texture and reduced melasma.

CASE 5

Laser/Energy-Based Procedure: Palomar Icon™ IPL and Vbeam® Pulsed-Dye Laser

Skin Care Complement: Botanical Corrective Gel

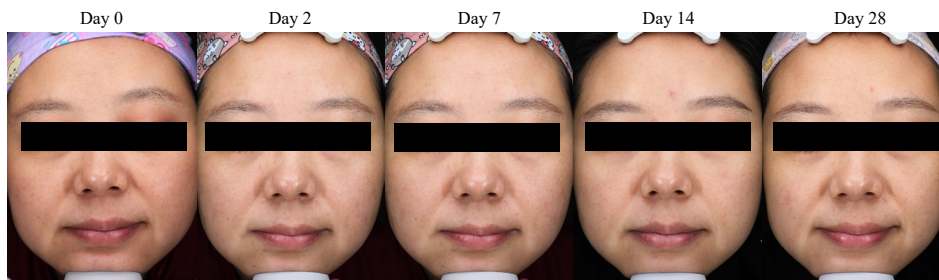
A 57-year-old woman with Fitzpatrick Skin Type II presents with sun-damaged skin. Her skin was notable for multiple seborrheic keratosis and telangiectasias. To treat the patient's extensive photodamage and photo-aged skin, the dermatologist proposed an integrated skincare regimen composed of Palomar Icon™ IPL laser and Vbeam® pulsed-dye laser with twice-daily botanical corrective gel for anti-inflammatory and antioxidant support.

FIGURE 5. Palomar Icon™ IPL and Vbeam® pulsed-dye laser with Botanical Corrective Gel for photoaged skin. *Photo Courtesy of Todd Schlesinger MD*

On day 0 following laser treatment, the patient had an erythema and discoloration score of 2. Her oozing and crusting score was 0. She continued to use botanical corrective gel twice daily but continued to have redness. On day 2, she strongly disagreed that there had been any improvement in her condition; however, she found relief in applying the botanical corrective gel, which relieved the skin discomfort and swelling. At 1 week, the physician assessed her and found her erythema and discoloration score decreased to 1 accompanied by 75% re-epithelization of her face. At this time, she felt that her skin had markedly improved since her last visit and reported no downtime from her procedure. During her 1-month follow-up, she was found to have some scant erythema; however, her skin had completely healed. It was recommended that she continue using the botanical corrective gel to help with the redness. Supported by her skincare regimen, the patient continues to improve with botanical corrective gel.

CASE 6**Laser/Energy-Based Procedure: Advanced Optimal Pulse Technology (AOPT) IPL****Skin Care Complement: Botanical Corrective Gel**

A 29-year-old female with Fitzpatrick Skin Type III presents with post-inflammatory erythema and scarring secondary to an extensive history of comedonal acne. Her treatment goal was to reduce acne pustules and scarring. In addition to laser treatment, the patient expressed interest in complimentary skin care regimens that would help reduce skin redness. The botanical corrective gel was recommended to treat her facial redness simultaneously and serve as an aftercare post-facial laser procedure. She was treated with Advanced Optimal Pulse Technology (AOPT) IPL and advised to use the botanical corrective gel twice daily with the provided gentle cleanser and daily moisturizer on the right side of her face. On the left side of

FIGURE 7. Use of IPL Therapy and Botanical Corrective Gel in facial rejuvenation. *Photo Courtesy of Hua Zhong MD*

her face, she was instructed to use only her usual moisturizer. The treatment was successful in reducing her acne scarring and the number of visible comedones. At her 1-month follow-up appointment, the patient had markedly reduced acne and brighter skin on her right side compared to her left. The patient was enthusiastic to continue the treatment regimen prescribed. She appreciated the cooling effect of the botanical corrective gel that was comforting post-laser treatment. In addition, the botanical corrective gel reduced her facial redness and brightened and moisturized her skin.

CASE 7**Laser/Energy-Based Procedure: IPL****Skin Care Complement: Botanical Corrective Gel**

A 37-year-old female with Fitzpatrick Skin Type IV presented with a concern of dull, photoaged skin and visible telangiectasias. She was treated with IPL therapy followed by botanical corrective gel for facial rejuvenation and skin brightening. Immediately after treatment, she had mild pinkish redness on treatment surfaces. Her post-procedure day 0 erythema score was 3. The botanical corrective gel was applied immediately after treatment

FIGURE 8. Reverso Fractional RF device and Botanical Corrective Gel for treatment of acne scarring. *Photo Courtesy of Michael Gold MD*

along with a cold compress. Within 20 minutes, the patient's redness and swelling had resolved and the patient returned to work. The patient reported no downtime and had fully resolved erythema by day 2. The treatment was successful in brightening her skin and stimulating collagenases for facial rejuvenation. The procedure had no impact on her daily activities and the patient reported complete satisfaction with her integrated skincare plan. Combined use of the botanical corrective gel after IPL greatly helped relieve post-treatment erythema and edema and helped the patient feel more comfortable returning to work and her usual activities.

CASE 8**Laser/Energy-Based Procedure: Reverso Fractional RF Device****Skin Care Complement: Botanical Corrective Gel**

A 29-year-old patient of Cherokee heritage, Fitzpatrick Skin Type IV, presented to the clinic for treatment of her uneven, scarred skin secondary to a history of acne. She was significantly impacted by the scarring in her daily life and expressed that she felt "unable to do her daily activities such as working out." In a joint decision-making process, the treating dermatologist decided to implement integrated skin care with the Reverso Fractional RF device and twice-daily botanical corrective gel

TABLE 4.

Overview of Integrated Skincare Regimens With Botanical Corrective Gel					
Case	Laser/Energy-Based Procedure	Gender & Age, Skin Type (Fitzpatrick)	Botanical Corrective Gel	Downtime/ Erythema	Outcome
1	Clear & Brilliant	F28, Fitzpatrick 6.	Immediately after treatment and the patient was instructed to continue twice a day	Reported only 2 days of downtime and saw resolution of redness by day 7	She felt that her skin had "extra luminosity" and strongly agreed that her condition has improved
	Non-Ablative Fractional Laser	<i>Concern of dull complexion</i>			
2	MRF, Fractional Thulium Fiber Laser	M66, Fitzpatrick 2	Botanical corrective gel was immediately applied	Significant erythema score decrease at day 2	At one month, the patient felt that his skin condition had strongly improved
		<i>Concern of uneven skin, acne scarring, and facial rejuvenation</i>			
3	Fractional CO2 Laser	M41, Fitzpatrick 5	Botanical corrective gel was immediately applied	Rapid resolution of erythema day 2. Only 1 day of downtime.	He felt that his skin condition had significantly improved
	Ablative Fractional Laser	<i>Concern of acne scarring</i>			
4	Clear & Brilliant®	F32, Fitzpatrick 3	Botanical corrective gel was immediately applied, and used twice a day	Patient had 7 days of downtime	She reported improved skin texture and reduced melasma
	Non-Ablative Fractional Laser	<i>Concern of uneven Skin and Melasma</i>			
5	Palomar Icon™ IPL and VBeam® Pulse Dye Laser	F57, Fitzpatrick 2	Botanical corrective gel was immediately applied, and used twice a day	At 7 days, she reported zero downtime from her procedure	Patient had markedly improved since her visit. She felt that the botanical corrective gel helped relieved post-procedure skin discomfort.
	Non-Ablative Laser	<i>Concern of sun-damaged skin. Her skin was notable for multiple seborrheic keratosis and telangiectasias</i>			
6	M22™ Advance Optimal Pulse Technology (AOPT) IPL	F29, Fitzpatrick 3	Split face, treatment was used twice daily and half of the face for 1 week	--	The patient had markedly reduced acne and brighter skin on her right side compared to her left
	Non-Ablative Laser	<i>Concern of post-inflammatory erythema and scarring secondary to an extensive history of comedonal acne</i>			
7	IPL	F37, Fitzpatrick 4	Botanical corrective gel was immediately applied with cold compress	Fully resolved erythema by day 2. 0 days of downtime.	Felt the treatment was successful in skin rejuvenation
	Non-Ablative Laser	<i>Concern of dull, photoaged skin and visible telangiectasias</i>			
8	Reverso Fractional RF Device	F29, Fitzpatrick 4	Botanical corrective gel was immediately after treatment and patient continued twice daily use	Fully resolved crusting by day 2 and erythema resolved by day 7. 1 day of downtime.	Patient felt that her skin condition had significantly improved. She continues to use botanical corrective gel and moisturizer routine to maintain results
		<i>Concern of uneven, scarred skin secondary to a history of acne</i>			

application. On day 0, the patient had mild, pink coloration in the treatment areas with an erythema score of 2 and a mild crusting score of 2. The botanical corrective gel was immediately applied after treatment to soothe the patient's skin. On day 2, she had a reduction in erythema and crusting with a score of 1 and 0, respectively. She also reported skin tightness, which was relieved with the botanical corrective gel and provided moisturizer. At her 1-week follow-up, she had almost complete healing of her skin with no residual erythema or crusting. The patient felt that her skin condition had significantly improved and reported only 1 day of downtime. By 1-month, the patient was completely healed and continued using the botanical corrective gel and moisturizer regimen to maintain her results.

Table 4 shows an overview of integrated skincare regimens with botanical corrective gel.

DISCUSSION

Integrated skincare regimens are evolving to be recognized as a key component for optimal outcomes in dermatology. By incorporating clinically proven, effective topical formulas into procedure-based treatment plans, integrated skin care helps to maintain and improve clinical outcomes, increase patient satisfaction, and strengthen patient commitment to the results of their procedures.

Real-world cases can help provide expert, anecdotal evidence for effective skincare regimens that may complement dermatologic procedures performed in the clinic. In addition, integrated skincare regimens return autonomy to patients and allow them to play an active role in their treatment plans. The patient cases discussed illustrate an integrated skincare regimen using botanical corrective gel combined with an energy-based laser procedure to ameliorate the rate of cutaneous healing post-facial laser or MRF. The botanical corrective gel contains antioxidant and anti-inflammatory ingredients in a medical-grade skincare product that can help enhance cosmesis and further improve patient satisfaction.

While laser procedures yield excellent results in skin rejuvenation and scar treatment, the procedure has known complications and may be relatively invasive.⁴ For example, facial swelling can be expected for up to 1 week after fractional CO₂ laser, and bruising and redness may occur for up to 3 days after fractional laser skin resurfacing.⁴ In the cases presented, the botanical corrective gel was added to combat the redness, swelling, and discomfort that often occur after laser procedures. Having antioxidant and anti-inflammatory properties, the botanical corrective gel was an effective adjunct therapy in the 8 patient cases presented. In addition, the botanical corrective gel's green color (complementary to red) helps to camouflage the red appearance of inflamed skin.⁹

The panel presented 8 cases that exemplified the successful use of an integrated skincare regimen, including botanical corrective gel across all 6 Fitzpatrick Skin Types. There were 5 presented patient cases of non-ablative laser use, 1 case of ablative laser use, and 2 cases of MRF used in combination with the botanical corrective gel. The skincare regimen contributed to increased patient satisfaction with clinical outcomes in all the presented cases. The most common adverse event after the procedure was erythema. Using the botanical corrective gel twice daily, 75% of patients had no residual erythema by day 7 post-laser or energy-based procedure. Importantly, many patients reported a soothing sensation upon gel application, which contributed to the reduction in downtime and improvement of post-procedure quality of life.

The combination of ingredients: glycerin, hyaluronic acid, and the botanical blend, calms and soothes irritated skin and reduces visible redness. In the botanical blend, the cucumber extracts contribute to soothing irritation, while the thyme is an antioxidant that helps repair and reduce skin infection. The botanical blend rapidly reduced redness in patients treated with IPL. This is supported by literature demonstrating reduced erythema and procedure-associated adverse effects in patients treated with topical phenolic antioxidant after IPL.¹⁰ Backed by real-world evidence, the diverse application of the botanical corrective gel makes it an ideal candidate for adjunct therapy in laser and energy-based procedures.

Patient satisfaction and treatment expectations are important issues in cosmetic dermatology. Our expert panel has demonstrated 8 cases in which patient satisfaction was bolstered by the use of a skincare product that enhanced the clinical outcome of procedures. The botanical corrective gel appears to reduce postoperative inflammatory response, reduce postoperative erythema, and reduce the risk of post-inflammatory hyperpigmentation with fractional lasers, especially in Fitzpatrick Skin Types III-VI. Given the few clinical trials available on integrated skincare regimens, real-world expert opinion is invaluable in guiding treatment plans to improve patient outcomes after cosmetic procedures.

Future Directions

The panel experts agreed that future randomized, controlled studies will be important to elucidate the efficacy of botanical corrective gel in integrated skincare regimens. Side-by-side comparison studies may be conducted in the future under controlled environments, which would allow for the direct comparison of individual participants. In addition, evaluation of other adjunctive therapies such as moisturizers and cleansers may also help in building the ideal, integrated skincare regimens for each patient and procedure. In the same vein, it may also be helpful to distinguish which laser procedure and botanical

corrective gel works best to refine integrated skincare regimens to be procedure-specific.

CONCLUSION

The real-world case series presented highlights an expert panel's clinical experience with botanical corrective gel for cutaneous healing post-facial laser or MRF treatment in clinical practice under real-world conditions. The panel's cumulative insight suggests that the botanical corrective gel is a desirable and effective complementary skincare treatment for laser procedures and is well-tolerated in a wide variety of skin types. These cases illustrate the successful use of botanical corrective gel in an integrated skincare model that dermatologists may use in the future.

Limitations

The presented cases represent real-world examples of the combination use of laser/energy-based procedures and botanical corrective gel. All outcome measures were reported by physicians in the clinic and reflect real-life data rather than data from a controlled, clinical trial environment. Experience with botanical corrective gel may differ with each patient, physician, and procedure. In addition, the botanical corrective gel with anti-inflammatory and antioxidant properties does not contain active ingredients to treat serious adverse events and complications related to laser therapies.

DISCLOSURES

The real-world case series was supported by an unrestricted educational grant from SkinCeuticals International- L'Oréal Groupe, which supplied the botanical serum-containing corrective gel. All authors contributed to the cases and development of the manuscript, reviewed it, and agreed with its content.

ACKNOWLEDGMENT

The authors acknowledge and thank Sophie Guénin, MSc, for her assistance in preparing this manuscript.

REFERENCES

1. Gold MH, Sensing W, Biron JA. A topical regimen improves skin healing and aesthetic outcomes when combined with a radiofrequency microneedling procedure. *J Cosmet Dermatol*. 2019;18(5):1280-1289.
2. Kafi R, Kwak HSR, Schumacher WE, et al. Improvement of naturally aged skin with vitamin A (retinol). *Arch Dermatol*. 2007;143(5):606-612.
3. Papaccio F, D Arino A, Caputo S, Bellei B. Focus on the contribution of oxidative stress in skin aging. *Antioxidants (Basel)*. 2022;11(6):1121.
4. Vanaman M, Fabi SG, Carruthers J. Complications in the cosmetic dermatology patient: A review and our experience (part 2). *Dermatol Surg*. 2016;42(1):12-20.
5. Maisel A, Waldman A, Poon E, Alam M. Types of cosmetic procedures requested by different types of patients and the reasons for these preferences. *Dermatol Surg*. 2020;46(12):1728-1732.
6. Beigvand HH, Razzaghi M, Rostami-Nejad M, et al. Assessment of laser effects on skin rejuvenation. *J Lasers Med Sci*. 2020;11(2).
7. Barbarino SC, Bucay VW, Cohen JL, Gold MH. Integrative skincare trial of intense pulsed light followed by the phyto-corrective mask, phyto-corrective gel, and resveratrol BE for decreasing post-procedure downtime and improving procedure outcomes in patients with rosacea. *J Cosmet Dermatol*. 2022;21(9):3759-3767.
8. Chun S. Fractional microneedling radiofrequency and fractional 1927 nm thulium laser treatment offer synergistic skin rejuvenation: A pilot case series. *Laser Ther*. 2018;27(4):283-291.
9. Draelos ZD. Cosmeceuticals for rosacea. *Clin Dermatol*. 2017;35(2):213-217.
10. Freedman BM. Topical antioxidant application augments the effects of intense pulsed light therapy. *J Cosmet Dermatol*. 2009;8(4):254-259.

AUTHOR CORRESPONDENCE

Anneke Andriessen PhD

E-mail:..... ti016762@telfort.nl

