

Pediatric Acne Patients' Treatment Real-World Case Series Using Skincare as Monotherapy, Adjunctive, and Maintenance Treatment

Lawrence A. Schachner MD FAAD FAAP,^a Anneke Andriessen PhD,^b Latanya Benjamin MD FAAD FAAP,^c Madelyn Dones MD FAAP,^d Ayleen Pinera-Llano MD FAAP,^e Linda Keller MD FAAP,^f Leon Kircik MD FAAD,^g Adelaide A. Hebert MD FAAD^h

^aDivision of Pediatric Dermatology, Department of Dermatology and Cutaneous Surgery, Department of Pediatrics, Leonard M. Miller School of Medicine, University of Miami, FL

^bRadboud UMC, Nijmegen and Andriessen Consultants, Malden, The Netherlands

^cDepartment of Women's and Children's Health, Florida Atlantic University, Boca Raton, FL

^dBaptist Health Hospital, Nicklaus Children's Hospital, Miami, FL

^eKing Bay Pediatrics, Maimi, FL, General Pediatrics, Nicklaus Children's Hospital, Miami, FL

^fBaptist Health Baptist Hospital, Baptist Health South Miami Hospital, Miami, FL

^gIcahn School of Medicine at Mount Sinai, New York, NY; Indiana University Medical Center, Indianapolis, IN; Physicians Skin Care, PLLC Louisville, KY; DermResearch, PLLC Louisville, KY; Skin Sciences, PLLC Louisville, KY

^hDepartment of Dermatology and Pediatrics, McGovern Medical School, Houston, TX; Children's Memorial Hermann Hospital, Houston, TX

ABSTRACT

Background: Pediatric acne is a common, complex, multifactorial inflammatory skin disease with various expressions in childhood that can be categorized by age, severity, and pubertal status. A pediatric acne case series is presented to educate health care providers treating children with acne to tailor acne prescription, nonprescription acne therapy, skin care, and maintenance treatment to improve patient outcomes.

Methods: A panel of 8 advisors in pediatric dermatology, dermatology, and pediatrics who treat pediatric patients with acne reported on clinical cases from their practice. During the meeting, the advisors discussed 17 pediatric acne cases and agreed to select 8 cases covering various presentations of pediatric acne, patient ages, and skin types. The case series gives a logical flow from youngest to oldest pediatric patients with acne.

Results: The 8 cases covered neonatal acne: birth to ≤ 8 weeks; preadolescent acne: ≥ 7 to 12 years; and adolescent acne: ≥ 12 to 19 years or after menarche for girls. It is to be noted that acne eruptions in children ages 1 to 6 years old are unusual and often associated with underlying endocrine and tumor issues. They are not included in this work. The advisors discussed why they selected the case, previous treatment, type of prevention and education provided, skin care as mono or adjunctive treatment, prescription and nonprescription therapy and maintenance treatment, key takeaways, and clinical pearls from the case. Skincare products containing lipids such as ceramides promote a healthy skin barrier in acne monotherapy, adjunctive, and maintenance treatment. However, their role in pediatric acne is not well defined and requires more studies.

Conclusion: Sharing best practices in acne therapy and maintenance treatment for pediatric patients with acne may support health care providers treating children to improve clinical outcomes.

J Drugs Dermatol. 2023;22:2(Suppl):s3-14.

INTRODUCTION

Acne vulgaris (acne) is a multifactorial inflammatory chronic skin disease with a prolonged course of acute outbreaks, relapses, and recurrences with significant social, psychological, and physical consequences.¹⁻⁶ The expressions of pediatric acne depend on age (neonatal, infantile,

mid-childhood, preadolescent, and adolescent), severity (mild, moderate, severe), type (eg, comedonal, papules, pustules, nodular), and other characteristics (eg, oily skin, pomade acne).⁵⁻⁸ Post-inflammatory hyperpigmentation (PIH) and scar formation may occur in some patients making it necessary to initiate timely and effective treatment.^{9,10}

Triggered by a pattern of innate inflammation, pediatric acne may manifest underlying pathology.^{5,6} Workup, when necessary, is based on age and physical findings, including morphology and distribution of acne lesions and age-related physical conditions.^{5,6,10}

The pathogenesis of acne is thought to be similar at all ages, including pediatric acne.^{5,6,10-17} However, treatment and maintenance may differ due to the state of skin maturity and concerns about the safety and efficacy of various therapies in young age groups.^{5,6,10-17}

Mild pediatric acne treatment may start with topical benzoyl peroxide (BPO) or a low-strength topical retinoid. Other options are topical fixed combination therapy such as BPO plus antibiotic, BPO plus retinoid, or a combination of BPO, antibiotic, and retinoid.^{5,6,10-17} Treatment recommendations for moderate pediatric acne may start with topical treatment similar to mild conditions.^{5,6,10-17} Other options may be an oral antibiotic combined with topical retinoid plus BPO.^{5,6,10-17} Inadequate response to therapy is a consideration to changing the type or the formulation of the topical-treatment.^{5,6,10-17} For females, hormonal therapy may be an option.^{5,6,10-17}

An oral antibiotic may be given together with a fixed combination topical treatment for severe pediatric acne.^{5,6,10-17} If the treatment response is inadequate, oral antibiotic or oral isotretinoin may be an option; consider hormonal therapy for females.^{5,6,10-17}

Acne prescription treatments in children younger than 12 years of age are considered off-label, though they may represent the community standard of care.¹⁰⁻¹⁷

For pediatric acne, nonprescription acne products and skin care using cleansers and moisturizers should play an essential part in acne treatment and maintenance approaches.^{5,6,10,17} However, within the available acne treatment consensuses, there is a knowledge gap on nonprescription cleansers and moisturizers for pediatric acne.^{6,10}

The advisors' previous publication¹⁰ aimed to improve outcomes in pediatric patients with acne by giving more attention to the use skincare cleansers and moisturizers to educate health care providers who treat children. The advisors defined various expressions of pediatric acne to educate and tailor nonprescription acne treatment and skin care using cleansers and moisturizers as mono or adjuncts to prescription treatment.¹⁰ The current pediatric acne patient case series describes the clinical experience with treatments, including skin care, to address the knowledge gap in prescription, nonprescription acne treatments, and skincare products for pediatric acne.

MATERIALS AND METHODS

The case series aims to meet a significant unmet need, as there is currently a lack of literature on the role of skincare in managing pediatric acne.^{6,10}

A panel of 8 advisors in pediatric dermatology, dermatology, and pediatrics who treat pediatric patients with acne convened a meeting on February 12, 2022. Each advisor presented pediatric patient cases from their practice in which a ceramide-containing skincare regime was used as adjunctive treatment or monotherapy for pediatric patients with acne. All advisors used the same template for gathering the case information. They addressed the following questions: 1) Why did you select this patient? 2) What was used previously for this patient (treatment and adjunctive skin care)? 3) What type of prevention and education was provided? 4) What type of skin care was given (monotherapy, adjunctive, or maintenance treatment)? 4) What type of therapy was given? 5) What was the treatment plan? 6) What was the status upon follow-up? 7) What are the lessons learned? 8) What are the key takeaways and clinical pearls from the case?

The advisors felt the case studies presented during the meeting are a comprehensive collection of typical presentations covering the necessary teaching points. Of the 17 cases presented during the meeting, the advisors agreed to select 8 cases covering various ages and skin types, including skin of color (SOC), and provide a logical flow from youngest to oldest patient.

Pediatric Patients With Acne Case Series

Neonatal Acne

The first 2 cases concern a 3-week-old boy and a 1-month-old boy with neonatal acne.^{5,6}

Neonatal acne occurring at 0 to 8 weeks of life is estimated to affect 20% of newborns and occurs more frequently in boys than girls.^{5,6} This type of acne usually presents with small erythematous papules and pustules on the face, rarely with comedones.^{5,6,10} Eruptions due to other causes, such as bacterial folliculitis, secondary syphilis, herpes simplex virus, and varicella-zoster virus, need to be excluded.^{5,6,10-13} Further conditions presenting eruptions include transient neonatal pustular melanosis, erythema toxicum neonatorum, eosinophilic pustular folliculitis, sebaceous gland hyperplasia, and congenital adrenal hyperplasia.^{5,6,10-13} Neonatal cephalic pustulosis presents with monomorphic red papules or pustules on the face and neck without comedones due to *Malassezia* yeasts colonization.^{5,6,10-13} Maternal medications may also cause neonatal eruptions and should be checked; for instance, lithium, phenytoin, and corticosteroids.^{5,6,10-13}

Neonatal acne rarely presents signs of sexual precocity, virilization, or growth abnormalities.^{5,6,10-13} Significant neonatal acne may be due to an underlying endocrinologic disease, tumor, or other gonadal/ovarian pathology.^{5,6} These patients require a workup and a referral to a pediatric endocrinologist.^{5,6} Neonatal acne typically resolves over a few months without scarring.⁵ For more complicated cases, off-label topical therapies may be considered.^{5,6,10-14}

CASE 1

A 3-week-old breast- and formula-fed male with neonatal acne on the face and atopic dermatitis (AD) on the scalp (Table 1). Previously, an oatmeal-containing moisturizer was used daily on the boy's face and scalp. The physician informed the parents about the hormonal influences causing the facial eruptions and the presence of AD.^{5,6,10-14,18} The aim was to establish a skincare regimen using a ceramide-containing baby wash and shampoo







and baby moisturizing lotion and cream to promote a healthy skin barrier.¹⁴⁻¹⁸ No further treatment was deemed necessary.^{5,6,10-14} The new parents were receptive to the specific skincare recommendations that cleared acne and AD. After clearance, they continued using the skincare regimen.

CASE 2

A 1-month-old male with neonatal acne on the face, mainly on the cheeks. No skin care was used upon presentation. The treatment comprised hydrocortisone acetate cream 2.5% and econazole nitrate cream 1% for 14 days. Upon follow up, the parent noted no improvement, and as a result, both creams were discontinued. The parent's education on this condition's transient and treatable nature was followed by the recommendation of a ceramide-containing baby wash and salicylic acid-containing moisturizer cream, which cleared the neonatal acne.

TABLE 1.

Case 1: A 3-Week-Old African American Boy With Neonatal Acne and Atopic Dermatitis

Before	After		
		Why:	3-week-old breast- and formula-fed male with neonatal acne The typical case shows a combination of neonatal acne and AD
		What was used previously:	*Oatmeal-containing moisturizer
		Education:	Hormonal influences and skin barrier function discussed
		Skin Care:	#Ceramide-containing baby wash and shampoo, and baby moisturizing lotion and cream
		Adjunct Therapy:	None
		Treatment Plan:	Establish a skincare regimen and treat neonatal acne
		Takeaways/ Clinical Pearls:	<ul style="list-style-type: none"> New parents are receptive to specific recommendations for skin care The skincare regime showed the ability of good moisturization to improve both acne and AD

*Oatmeal-containing moisturizer (Aveeno), #Ceramide-containing skin care (CeraVe Baby Wash and Shampoo, CeraVe Baby Moisturizing Lotion and Cream), Atopic dermatitis (AD). Case 1: Clinical case and photographs are courtesy of Dr. L. Keller. Parents' consent for the case and photographs was obtained.

When discussing this case, the advisors agreed that a combination of a ceramide-containing baby wash and salicylic acid-containing moisturizer cream cleared the neonatal acne after 2 weeks. Whether the prescription topicals' residual effects were responsible for clearing acne is unclear; nevertheless, the advisors agreed that the baby's skin condition had much

improved. Parents prefer not to use topical steroids and are willing to accept alternatives they perceive as safer for long-term use. However, the salicylic acid-containing moisturizer cream may cause an allergic reaction or skin irritation.¹⁹ Therefore, when starting treatment with this cream, a minimal amount of the cream should be applied as a "test dose" to 1 or 2 small skin

TABLE 2.

Case 2: A 1-Month-Old Boy With Neonatal Acne

Before	Mid-way	After		
			Why:	1-month-old male with neonatal acne presents a typical case
			What was used previously:	None
			Education:	Education of parents on the transient and treatable nature of this condition
			Skin Care:	Ceramide-containing baby wash and SA cream
			Adjunct Therapy:	Hydrocortisone acetate cream 2.5% + Econazole Nitrate cream 1%
			Treatment Plan:	Trial of hydrocortisone acetate cream + Econazole nitrate cream for 14 days. Upon follow up no improvement noted by the parent. Changed management, discontinued the hydrocortisone and econazole creams, and began #ceramide-containing skincare. Parents noted improvement.
			Takeaways/ Clinical Pearls:	<ul style="list-style-type: none"> The prescription therapy was discontinued after 14 days. The ceramide-containing products started at this point cleared the neonatal acne after 2 weeks. Advisors discussed whether the prescription topicals' residual effects were responsible for clearing acne; nevertheless, they agreed that the baby's skin condition had much improved. Parents prefer not to use topical steroids and are willing to accept alternatives they perceive as safer for long-term use. Parents should be informed about possible salicylate toxicity when using the cream. Before starting treatment with the SA-containing cream, parents should be instructed that a minimal amount (one fingertip) of the cream should be applied as a "test dose" to 1 or 2 small skin areas every day for 3 days in a row. Treatment is continued as the patient shows no adverse reaction to the cream. Parents should be instructed on how to apply the topical products around the eyes carefully.

*Ceramide-containing skincare (CeraVe Baby Wash and CeraVe SA Moisturizing Cream), Salicylic acid (SA). Case 2: Clinical case and photographs are courtesy of Dr. Ayleen Pinera-Llano. Parents' consent for the case and photographs were obtained.

areas every day for 3 days in a row. Treatment was continued as the patient had no adverse reaction to the cream. Currently, there is no clinical data to support safe topically applied salicylic acid usage in babies and/or demonstrating low or no risk of topical salicylate toxicity.

Preadolescent Acne

Preadolescent acne occurring in children at 7 to 12 years of age, or up to menarche for females, has become more common; however, only a few epidemiological studies are available in this population.^{13,21-26}

Children with preadolescent (≥ 7 to 12 years) acne require a directed medical history and physical examination.^{5,6} The medical history should include the age of acne onset, disease duration, growth parameters, and age of onset for any early signs of virilization.²¹ The physical examination should include height, weight, types, location of acne, and signs of puberty (body odor, axillary and pubic hair, breast buds, enlarged phallus, testis, or clitoris). Laboratory evaluation is indicated for patients with other signs of early virilization (in the US, pre-8 years of age in girls and pre-9 years of age in boys.) Hand and wrist X-ray for







bone age is a simple, practical initial examination.^{5,6} A workup and a referral to a pediatric endocrinologist are warranted for mid-childhood acne (ages 1 to < 7 years).^{5,6,21} This type of acne is uncommon, and patients need to be examined, especially if displaying secondary sexual characteristics.^{5,6} Physicians should collect patient history on their diet and consider any potential contributing factors to their acne.⁹

CASE 3

An 8-year-old girl presents with mild preadolescent acne on her face. The patient presented at the pediatric clinic as the condition bothered her (Table 3). No skin care was used until now. The patient and her parents received an acne handout informing them about the disease, treatment, and maintenance approaches. A ceramide-containing 4% BPO foaming wash with a facial moisturizing lotion was recommended to be used in the morning and the facial moisturizing lotion alone in the evening. The girl and her parents were interested in the acne skincare regimen, which also provided acne maintenance.^{27,28} The advisors agreed that when acne is addressed early on, it can set children up for later success.

TABLE 3.



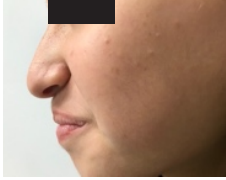



Case 3: 8-Year-Old Girl With Mild Preadolescent Acne

Before	After		
		Why:	8-year-old girl selected as a common presentation of acne in a pediatric office, mildest of cases
		What was used previously:	No products
		Education:	Acne handout
		Skin Care:	Ceramide-containing 4% BP foaming wash and, AM facial moisturizing lotion, PM facial moisturizing lotion
		Adjunct Therapy:	None
		Treatment Plan:	Acne maintenance using skin care
		Takeaways/ Clinical Pearls:	<ul style="list-style-type: none"> • No dramatic change in acne but her skin condition had improved • Young patients are interested in acne skin care • Addressing acne early on can set children up for later success

Ceramide-containing 4% benzoyl peroxide foaming wash, ceramide-containing moisturizing lotion (CeraVe 4% BP foaming wash, CeraVe AM Facial Moisturizing Lotion, CeraVe PM Facial Moisturizing Lotion) Case 3: Clinical case and photographs are courtesy of Dr. M Dones. Parents' consent for the case and photographs was obtained.

TABLE 4.

Case 4: 12-Year-Old Girl With Mild Preadolescent Acne

Before	After		
		Why:	12-year-old girl selected as a common presentation of mild acne seen in a pediatric office
		What was used previously:	An apricot facial scrub
		Education:	Acne education and a handout
		Skin Care:	AM ceramide-containing 4% BP foaming wash and facial moisturizing lotion PM ceramide-containing facial moisturizing lotion
		Adjunct Therapy:	None
		Treatment Plan:	Acne treatment and maintenance regimen to improve skin condition
		Takeaways/ Clinical Pearls:	<ul style="list-style-type: none"> • Treatment was not consistent because the patient traveled between 2 homes • After 2 weeks, products were provided for both homes improving compliance With compliance, treatment was sufficient to substantially clear the acne

Ceramide-containing 4% benzoyl peroxide foaming wash, ceramide-containing moisturizing lotion (CeraVe 4% BP foaming wash, CeraVe Facial Moisturizing Lotion)
Case 4: Clinical case and photographs are courtesy of Dr. L Keller. Parents' consent for the case and photographs was obtained.

CASE 4

A 12-year-old girl with mild preadolescent facial acne (Table 4). The case was selected to show that pediatric patients with 2 homes may struggle with compliance; samples may help to bridge the gap until both parents can acquire full-size products. The education, treatment, and maintenance were similar as shown in case 3. Treatment at first was not consistent because the patient traveled between 2 homes. After 2 weeks, the products were provided for both addresses, resulting in improved compliance. The enhanced compliance with treatment was sufficient to clear the acne substantially.

Adolescent Acne

Adolescent acne is common, and it occurs in children at 12 to 19 years of age or after menarche for girls.¹⁻⁶

CASE 5

A 13-year-old girl with adolescent facial acne and acne on her back (Table 5). The case is selected as an example of treatment of acne in various body locations. Previously a cleanser and moisturizer was used which was changed to a ceramide-containing BPO foaming cleanser and a facial moisturizing lotion in the morning and the evening. Although the acne improved a more aggressive regime was needed to clear it.





CASE 6

A 14-year-old girl who is an athlete, was selected as a common presentation in the pediatric practice of mild acne superimposed on AD (Table 6).

A matched cohort study found that the 12-month prevalence

TABLE 5.

Case 5: 13-Year-Old Girl With Face and Back Adolescent Acne

Before	After		
		Why:	13-year-old girl was selected as a common presentation of acne in a pediatric office
		What was used previously:	*Cleanser and moisturizer
		Education:	Acne handout
		Skin Care:	AM ceramide-containing 4% BP foaming wash and facial moisturizing lotion PM ceramide-containing facial moisturizing lotion
		Adjunct Therapy:	Tretinoin 0.025% Cream
		Treatment Plan:	Acne treatment and maintenance
		Takeaways/ Clinical Pearls:	<ul style="list-style-type: none"> Improvement but not the resolution of acne. Although the acne improved significantly, the treatment plan should have been more aggressive to clear the acne Skin care can help clear back acne

*Neutrogena skincare products

Ceramide-containing 4% benzoyl peroxide foaming wash, ceramide-containing moisturizing lotion (CeraVe 4% BP foaming wash, CeraVe Facial Moisturizing Lotion)

Case 5: Clinical case and photographs are courtesy of Dr. M Dones. Parents' consent for the case and photographs was obtained.

of acne in the general population was 3.7% and slightly higher with 3.9% among patients with AD. Among 12- to 18-year-old patients with AD, particularly women, the incidence rate of acne was highest.²⁹

The teen was involved in daily outdoor athletics and had "no time" to spend on a skincare regimen. Acne relapse and the response to treatments interacting with the skin barrier may be influenced by acne exposome factors (nutrition, medication, occupational factors, pollutants, climatic factors, and others).³⁰ Reducing the impact of these exposome factors benefits acne and AD.^{30,31}







The teen previously used no specific products for her face. The patient and her parents should be educated on acne combined with AD and the need for skin care and sun protection to address both conditions. The skincare regimen acts both as a treatment and maintenance regimen.^{6,15-17,28-31} A treatment plan was developed to fit the girl's busy schedule. A ceramide-containing

4% BPO foaming wash with a facial moisturizing lotion was recommended to be used in the morning and the facial moisturizing lotion alone in the evening. A sun protection factor (SPF) should be applied prior to athletics, and application should be repeated in case of heavy perspiration. No further treatment was deemed necessary. The skin condition of her forehead had markedly improved as well as the dry skin on her cheeks. The risk of developing post-inflammatory hyperpigmentation (PIH) in these facial regions is high, especially if insufficiently protected against sun exposure and a lack of moisturization.

Takeaways from this case /clinical pearls: The easy-to-follow and effective regimen encouraged compliance in the busy teen. Moisturization should be a priority in patients with both acne and AD; these patients can require more education than other patients with acne. Gentler acne regimens should be recommended in patients with acne and AD.^{6,15-17,28-31} Patients with both acne and AD require more personalization of regimens.^{6,15-17,28-31}

TABLE 6.

Case 6: 14-Year-Old Girl With Mild Comedonal Adolescent Acne/Atopic Dermatitis and a Busy Schedule

Before	After		
		Why:	The 14-year-old girl who is an athlete was selected as a common presentation of mild acne super-imposed on atopic dermatitis in pediatric practice. The busy teen involved in daily athletics has no time to spend on a skincare regimen.
		What was used previously:	No-specific products
		Education:	Acne and sun protection were discussed
		Skin Care:	AM ceramide-containing 4% BP foaming wash and facial moisturizing lotion. PM ceramide-containing facial moisturizing lotion, and sunscreen was recommended before athletics
		Adjunct Therapy:	None
		Treatment Plan:	To establish an acne and atopic dermatitis treatment and maintenance regimen aimed to fit into a busy schedule
		Takeaways/ Clinical Pearls:	<ul style="list-style-type: none"> • The forehead skin condition and the dryness on the cheeks significantly improved • Regimens that are easy to follow and effective encourage compliance in busy teens • Moisturization should be a priority in patients with both acne and atopic dermatitis; these patients can require more education than other patients with acne • Gentler acne regimens should be used in patients with acne and atopic dermatitis • Patients with both acne and atopic dermatitis require more personalization of regimens

Ceramide-containing 4% benzoyl peroxide foaming wash, ceramide-containing moisturizing lotion (CeraVe 4% BP foaming wash, CeraVe Facial Moisturizing Lotion)
Case 6: Clinical case and photographs are courtesy of Dr. L Keller. Parents' consent for the case and photographs was obtained.

Although evidence is scarce, researchers are increasingly interested in follicular epithelial barrier dysfunction in patients with acne.^{6,15-17,28-31} A consensus paper stated that dryness and skin irritation resulting from acne treatment could be improved using ceramide-containing cleansers and moisturizers, enhancing treatment adherence.¹⁶ The authors stated that the skincare regimen should be an essential part of the acne prevention, treatment, and maintenance care regimen.¹⁶ Skin care is necessary for acne treatment and is part of various acne guidelines and consensus papers.^{6,15-17,28-31}

Newer, nonsteroidal, or low-potency steroid topicals can address intermittent AD flares in these patients; parents should be instructed not to use leftover mid- or high-potency topical or oral steroids.^{29,30}

CASE 7

A 15-year-old girl with SOC and moderate adolescent acne and PIH (Table 7). This case highlights the issues patients with SOC and acne may face. Many pediatric and adult patients with richly pigmented skin and acne are more concerned with PIH than with acne; these patients should be instructed that the key to preventing PIH is to prevent and effectively treat acne.^{9,14,27,36,37}

Acne prevalence and sequelae are considered more common in SOC populations.^{9,32-37} PIH may be due to inflammation-inducing excessive melanin production or irregular pigment dispersion, although the mechanism is yet to be elucidated.^{33,34} Early and effective acne treatment with topical adapalene combined with BPO can prevent the risk of future PIH and acne-related scars.^{14,30-37}

TABLE 7.**Case 7: 15-Year-Old Girl With SOC, PIH, and Moderate Adolescent Acne**

Why:	Many pediatric patients with SOC are more concerned with discolorations than with acne lesions
What was used previously:	Previously treated with generic topical prescription tretinoin, which worsened PIH
Education:	Education on acne-related PIH and a handout on acne and PIH
Skin Care:	AM 4% BP foaming wash and facial moisturizing lotion *PM ceramide-containing facial moisturizing lotion
Adjunct Therapy:	Prescription therapy with 20% azelaic acid cream*, after discontinuing the generic tretinoin, which had worsened the PIH
Treatment Plan:	To establish an acne treatment and maintenance regimen addressing SOC and PIH, negotiate around cultural practices, and find a tailored solution. Treatment aimed to fit the patient's individual requirements
Takeaways/ Clinical Pearls:	<ul style="list-style-type: none"> Many pediatric patients with SOC are more concerned with PIH than with acne; these patients should be instructed that the key to preventing PIH is to prevent acne and to effectively treat it early. Education of patients with PIH takes significantly longer than other acne patients; a handout on PIH that accompanies acne 101 may help. Negotiation around cultural practices may be necessary; if patients do not discontinue the use of oily hair products, they can put a towel on their pillow to prevent the face from absorbing the product. Some retinoids are more appropriate than others for treating patients with PIH, but providers have little control over what products patients receive because of insurance coverage.

Skin of color (SOC), Post-inflammatory hyperpigmentation (PIH), *Prescription therapy with 20% azelaic acid cream (AZELEX®)

*Ceramide-containing 4% benzoyl peroxide foaming wash, ceramide-containing moisturizing lotion (CeraVe 4% BP foaming wash, CeraVe Facial Moisturizing Lotion)

Case 7: Clinical case is courtesy of Dr. L Kircik. Parents' consent for the case but not the photographs.

Tan and colleagues showed that 43% of 1942 patients with SOC and acne had acne-related scarring and that most acne scars (99%) originated from inflammatory and post-inflammatory acne lesions.³⁵

The clinician should inform the patient and parents about PIH and acne-related scarring to help them understand why they occurred.^{9,37} Both the patient and the parents were educated on acne-related PIH, and a handout on acne and PIH was given. The 15-year-old girl initially received prescription therapy with topical tretinoin, which had worsened her PIH. The treatment was changed to prescription therapy with 20% azelaic acid cream after discontinuing the generic tretinoin. Adjunctive skin












care was recommended with ceramide-containing 4% BPO foaming wash, facial moisturizing lotion in the morning, and ceramide-containing facial moisturizing lotion in the evening.

The patient was counseled to avoid abrasive scrubs, rubbing the skin, and topical alcohol, which leads to irritation and thus inflammation.^{9,37,38} Gentle skin care, decreasing washing, increasing moisturizer, and sunscreen use are beneficial for richly pigmented skin.^{5,6,9,37,38}

Takeaways/clinical pearls: The concern for PIH should be addressed; education of patients with PIH takes significantly longer than other acne patients; a handout on PIH that

TABLE 8.

Case 8: 17-Year-Old Boy Eventually Treated With Oral Isotretinoin

Before starting with isotretinoin		Why:	A typical case of severe acne and treatment with oral isotretinoin and optimal skincare. The 17-year-old boy with severe facial acne requires oral isotretinoin. He and his mother needed guidance on the safety and efficacy of the treatment to overcome their toxicity concerns.
Before	After		
		What was previously used:	Prior treatment with oral Abx, last use one year ago. Topical Retin A (tolerated well w/ mild peeling during 1st week of use) and clindamycin gel (+). Currently, he is washing his face with a ceramide-containing cleanser* and another OTC product.
			
After starting with isotretinoin: Interval Purging and Complication- s/p Isotretinoin x 1 month		Education:	Education on safe and effective oral isotretinoin therapy and skincare that won't aggravate the existing skin barrier condition
		Skin Care:	Morning and evening ceramide-containing facial cleanser and facial moisturizing lotion and healing ointment for the lips#
End Result:		Adjunct Therapy:	Previous acne regimen with various antibiotics was ineffective; oral isotretinoin was initiated after several visits and successfully cleared the acne.
Before	After	Treatment Plan:	To establish an acne treatment and maintenance regimen designed to fit the patient's requirements and overcome concerns with oral isotretinoin
			
		Takeaways/ Clinical Pearls:	<p>Tips for educating/informing patients/families to try/continue oral isotretinoin:</p> <ul style="list-style-type: none">• Isotretinoin can be started "low and slow" for patients worried about its toxicity• Ask patients if they have seen friends at school have success with oral isotretinoin or if their friends have noticed a difference in their skin• Patients can experience a "purging effect" after initiating oral isotretinoin• Patients may need re-education on basic skin care to prevent irritation• How to address residual erythema after successful oral isotretinoin treatment is a knowledge gap
Residual erythema and scarring			
			

Antibiotics (Abx), *Cleanser with ceramides (Cetaphil), #Ceramide-containing cleanser and healing ointment (CeraVe Hydrating Facial Cleanser and Healing Ointment).
Case 8: Clinical case is courtesy of Dr. Latanya Benjamin. Parents' and patients' consent for the case and the photographs.

accompanies acne 101 may help; and, early and effective acne treatment may prevent PIH.^{9,37}

Pediatricians recognize the importance of PIH in patients with acne and typically refer these cases to a dermatologist.^{5,6,9,37} Negotiation around cultural practices in skin and hair care may be necessary; if patients do not discontinue oily hair products, they can put a towel on their pillow to prevent the face from absorbing the product.^{9,38}

The advisors agreed that some retinoids are more appropriate than others for treating patients with PIH, but providers have little control over what products patients receive because of insurance coverage.

CASE 8

A 17-year-old boy with severe facial acne (self-rated severity 7/10 [10 being worst]) since age 14 (Table 8). The patient medical history included asthma and an easily upset stomach. The youngest of 3 boys in the 12th grade, he enjoys playing football and is considering attending an in-state college. After discussing the therapy options, the mother deferred oral isotretinoin. Oral minocycline 100 mg twice daily was started while continuing with tretinoin 0.025% cream, a facial wash, and a BPO wash for showering. Although he complied with the treatment plan and no adverse events occurred, his facial condition did not improve by his week 4 follow up. He rates his acne at 6/10 in severity. The physician again discussed the treatment options and repeated the recommendation for oral isotretinoin. The mother remained reluctant to consider isotretinoin as the patient has had a borderline elevation of cholesterol in the past and has a family history of fatty liver. The antibiotic was switched to oral trimethoprim-sulfamethoxazole (Bactrim) double strength (1 tablet twice daily), continuing the topical regime and skin care. On follow up at 4 to 6 weeks, his acne had not improved, and oral isotretinoin at 20 mg daily was started and slowly titrated up to 60 mg. No cholesterol, liver, or any other laboratory abnormalities occurred. Skin care was changed to a ceramide-containing facial cleanser and a healing ointment for the lips.

At the next visit, the acne had cleared, and some residual erythema on his cheeks remained.

Takeaways/clinical pearls: Education is crucial when guiding patients and parents to try and continue oral isotretinoin for severe acne. Physicians should explain that oral isotretinoin can be started at a low dose and slowly titrated up. In addition, they can ask the patient if they have seen friends at school who have had success with oral isotretinoin or if their friends have noticed a difference in their skin condition.

When starting oral isotretinoin, patients can experience a "purging effect" and may need re-education on primary skin care to prevent irritation.³⁹⁻⁴¹

LIMITATIONS

The cases are intended to illustrate the real-world experience rather than reflect a controlled clinical trial data environment, nor do they mirror statistical outcomes. The use of the ceramide-containing cleanser and moisturizer is at the discretion of the treating health care professional after careful clinical evaluation.

SUMMARY AND CONCLUSIONS

The presented pediatric acne case series aims to educate health care providers treating children with acne to tailor acne prescription, nonprescription therapy, skin care, and maintenance treatment to improve patient outcomes.

The 8 cases covered neonatal acne: birth to ≤ 8 weeks; preadolescent acne: ≥ 7 to 12 years; and adolescent acne: ≥ 12 to 19 years or after menarche for girls.

Skincare products containing lipids such as ceramides promote a healthy skin barrier in acne monotherapy, adjunctive, and maintenance treatment. However, further studies are needed to define their role in pediatric acne and to integrate skin care into treatment regimens, guidelines, and algorithms for pediatric acne.

Sharing best practices in acne therapy and maintenance treatment for pediatric patients with acne may support health care providers treating children to improve clinical outcomes.

DISCLOSURES

The authors disclose receipt of an unrestricted educational grant from CeraVe US for support with the research of this work; they also received consultancy fees for their work on this project.

All the authors developed the manuscript, reviewed it, and agree with its content.

The authors gave kind permission to use the photographs of the clinical cases they performed and obtained consent and permission from the patients' caregivers to use the photographs in the publication.

REFERENCES

1. Bhate K, Williams HC. Epidemiology of acne vulgaris. *Br J Dermatol*. 2013;168(3):474-85.
2. Hay RJ, Johns NE, Williams HC, et al. The global burden of skin disease in 2010: an analysis of the prevalence and impact of skin conditions. *J Invest Dermatol*. 2014;134(6):1527-34.
3. Revol O, Milliez N, Gerard D. Psychological impact of acne on 21st-century adolescents: decoding for better care. *Br J Dermatol*. 2015;172 (Suppl. 1):52-58.
4. Gordon RA, Crosnoe R, Wang X. Physical attractiveness and the accumulation of social and human capital in adolescence and young adulthood: assets and distractions. *Monogr Soc Res Child Dev*. 2013; 78:1-137.
5. Eichenfield LF, Krakowski AC, Piggott C, et al. Evidence-based recommendations for the diagnosis and treatment of pediatric acne. American Acne and Rosacea Society. *Pediatrics*. 2013 May; 131 Suppl 3:S163-86. PMID: 23637225.

6. Schachner LA, Eichenfield L, Andriessen A, et al. Consensus on neonatal through preadolescent acne. *J Drugs Dermatol*. 2020;19(6):1-10. doi:10.36849/JDD.2020.5065
7. Skroza N, Tolino E, Potenza C et al. Adult acne versus adolescent acne. *J Clin Aesthet Dermatol*. 2018;11(1):21-25.
8. Perkins AC, Maglione J, Hillebrand GG, et al. Acne vulgaris in women: prevalence across the life span. *J Womens Health (Larchmt)*. 2012;21(2):223-230.
9. Alexis AF, Harper JC, Stein Gold LF, et al. Treating acne in patients with skin of color. *Semin Cutan Med Surg*. 2018;37(Suppl3):S71-S73.
10. Schachner LA, Andriessen A, Hebert AA, et al. The many faces of pediatric acne: How to tailor nonprescription acne treatment and skincare using cleansers and moisturizers. *J Drugs Dermatol*. 2022;21(6):602-612. doi: 10.36849/JDD.6872
11. Prohic A, Jovovic Sadikovic T, Krupaliya-Fazlic M, et al. Malassezia species in healthy skin and in dermatological conditions. *Int J Dermatol*. 2016;55(5):494-504. doi: 10.1111/ijd.13116.
12. Tamayo CS, Janniger CK, Micali G, et al. Neonatal and infantile acne vulgaris: an update. *Cutis*. 2014;94(1):13-16.
13. Piggott CDS, Eichenfield LF, Lucky AW. Acne in children. In: Shalita AR, Del Rosso JQ, Webster GF, eds. *Acne Vulgaris*. New York, NY: Informa Healthcare; 2011:182-197.
14. Thiboutot DM, Dreno B, Abanmi A, et al. Practical management of acne for clinicians: an international consensus from the global alliance to improve outcomes in acne. *J Am Acad Dermatol*. 2018;78(2S1):S1-23.
15. Pappas A, et al. Seasonal changes in epidermal ceramides are linked to impaired barrier function in acne patients. *Experimental Dermatol*. 2018;27(8):833-836.
16. Lynde CW, Andriessen A, Barankin B, et al. Moisturizers and ceramide-containing moisturizers may offer concomitant therapy with benefits. *J Clin Aesthet Dermatol*. 2014;7(3):18-26.
17. Araviiskaia E, Dreno B. The role of dermocosmetics in acne vulgaris. *J Eur Acad Dermatol Venereol*. 2016; 30, 926-935.
18. Kelleher M, Dunn-Galvin A, Hourihane JQ, et al. Skin barrier dysfunction measured through Transepidermal water loss at 2 days and 2 months predates and predicts atopic dermatitis at 1 year. *J Allergy Clin Immunol*. 2015;135:930-935.
19. Cices A, Bayers S, Verzi AE, et al. Poisoning through pediatric skin. *Am J Clin Dermatol*. 2017;18(3):391-403.
20. Melnik BC. Linking diet to acne metabolomics, inflammation, and comedogenesis: an update. *Clin Cosmet Investig Dermatol*. 2015;8:371-88.
21. Bree AF, Siegfried EC. Acne vulgaris in preadolescent children: recommendations for evaluation. *Pediatr Dermatol*. 2014;31:27-32.
22. Lovasz M, Szegedi A, Zouboulis CC, et al. Sebaceous-immunobiology is orchestrated by sebum lipids. *Dermatoendocrinol*. 2017;9(1):e1375636.
23. Elsaie ML. Hormonal treatment of acne vulgaris: an update. *Clin Cosmet Investig Dermatol*. 2016;9:241-248.
24. Parikh SA, Davis SA, Krowchuck DP, et al. Common use of prescription off-label acne therapy in children younger than 12 years old. *Ped Derm*. 2014;31(5):551-555.
25. Karciauskiene J, Valiukeviciene S, Gollnick H, et al. The prevalence and risk factors of adolescent acne among schoolchildren in Lithuania: A cross-sectional study. *J Eur Acad Dermatol Venereol*. 2014;28:733-740.
26. Eun DH, Kim JY, Jang YH, et al. Clinical investigation on preadolescent acne. *Korean Dermatol Association and Korean Society Invest Dermatol*. 2019;31(2):249-251. <https://doi.org/10.5021/ad.2019.31.2.249>
27. Zaenglein AL, Pathy AL, Schlosser BJ, et al. Guidelines of care for the management of acne vulgaris. *J Am Acad Dermatol*. 2016;74(5):945-73.e33. doi: 10.1016/j.jaad.2015.12.037
28. Thiboutot D, Del Rosso JQ. Acne vulgaris and the epidermal barrier: is acne vulgaris associated with inherent epidermal abnormalities that cause impairment of barrier functions? Do any topical acne therapies alter the structural and/or functional integrity of the epidermal barrier? *J Clin Aesthet Dermatol*. 2013;6(2):18-24.
29. Thyssen JP, Nymand LK, Maul JT. Incidence, prevalence and risk of acne in adolescent and adult patients with atopic dermatitis: a matched cohort study. *J Eur Acad Dermatol Venerol*. 2022;36(6):890-896.
30. Dréno B, Bettoli B, Araviiskaia E, et al. The influence of the exposure on acne. *J Eur Acad Dermatol Venerol*. 2018;32(5):812-819. doi: 10.1111/jdv.14820.
31. Dréno B. What is new in the pathophysiology of acne, an overview. *J Eur Acad Dermatol Venereol*. 2017; 31(Suppl 5): 8-12.
32. Perkins AC, Cheng CE, Hillebrand GG, et al. Comparison of the epidemiology of acne vulgaris among Caucasian, Asian, continental Indian and African American women. *J Eur Acad Dermatol Venereol*. 2011;25:1054-60.
33. Davis SA, Narahari S, Feldman SR, et al. Top dermatologic conditions in patients of color: An Analysis of Nationally Representative Data. *J Drugs Dermatol*. 2012;11(4):466-73.
34. Abad-Casintahan F, Chow SK, Goh CL, et al. Frequency and characteristics of acne-related post-inflammatory hyperpigmentation. *J Dermatol*. 2016; 43(7): 826- 828.
35. Tan J, Kang S, Leyden J. Prevalence and risk factors of acne scarring among patients consulting dermatologists in the United States. *J Drugs Dermatol*. 2017;16(2):97-102.
36. Dréno B, Bissonnette R, Tan J, et al. Prevention and reduction of atrophic acne scars with adapalene 0.3%/benzoyl peroxide 2.5% gel in subjects with moderate or severe facial acne: Results of a 6-month randomized, vehicle-controlled trial using intra-individual comparison. *Am J Clin Dermatol*. 2018;19:275-286. doi: 10.1007/s40257-018-0352-y
37. Alexis AF, Woolery-Lloyd H, Williams K, et al. Racial/ethnic variations in acne: Implications for treatment and skin care recommendations for acne patients with skin of color. *J Drugs Dermatol*. 2021;20(7):716-725. doi:10.36849/JDD.6169
38. Baldwin HE, Friedlander SF, Eichenfield LF, et al. The effects of culture, skin color, and other nonclinical issues on acne treatment. *Semin Cutan Med Surg*. 30:S12-S15:12
39. Del Rosso JQ. Clinical relevance of skin barrier changes associated with the use of oral isotretinoin: the importance of barrier repair therapy in patient management. *J Drugs Dermatol*. 2013;12(6):626-31.
40. Dreno B, Araviiskaia E, Kerob D, et al. Nonprescription acne vulgaris treatments: Their role in our treatment armamentarium—An international panel discussion. *J Cosmet Dermatol*. 2020;19(9):2201-2211. doi: 10.1111/jocd.13497
41. Andriessen A, Rodas AC, Gonzalez CG, et al. Over-the-counter products for acne treatment and maintenance in Latin America: A review of current clinical practice. *J Drugs Dermatol*. 2021;20(4):1-9. doi: 10.36849/JDD.2021.5779

AUTHOR CORRESPONDENCE

Lawrence A. Schachner MD FAAD FAAP

E-mail:..... LSchachn@med.miami.edu