

Update on the Management of Rosacea: A Status Report on the Current Role and New Horizons With Topical Azelaic Acid

James Q. Del Rosso DO FAOCD^a and Leon H. Kircik MD^b

^aLas Vegas Skin and Cancer Clinics/West Dermatology Group, Henderson, NV; Touro University College of Osteopathic Medicine, Henderson, NV

^bIcahn School of Medicine at Mount Sinai, New York, NY; Indiana University School of Medicine, Indianapolis, IN; Physicians Skin Care, PLLC, Louisville, KY

ABSTRACT

Azelaic acid (AzA) 15% gel has been available in the United States for slightly over a decade, approved for treatment of the inflammatory lesions (papules and pustules) of rosacea. Efficacy and safety have been established in multiple studies both as monotherapy and in combination with oral doxycycline. Azelaic acid 15% gel has been shown not to induce epidermal permeability barrier impairment, and proper skin care reduces the likelihood of neurosensory adverse effects of stinging and burning that can affect a subset of patients with rosacea. Azelaic acid 15% gel appears to produce a quicker onset of clinical effect than metronidazole in some patients when either agent is used in combination with subantimicrobial dose doxycycline; however, both topical agents are effective when used in this combination approach for papulopustular rosacea (PPR). Although more information is needed on the modes of action of AzA in the treatment of rosacea, downregulation of the cathelicidin pathway appears to be one operative mode of action based on in vitro and in vivo studies, including data from patients treated with AzA 15% gel for PPR. Azelaic acid 15% foam is currently in the latter stages of development for PPR, with pivotal studies demonstrating efficacy and favorable tolerability, including a very low incidence of stinging, burning, and itching even without the use of designated skin care products.

J Drugs Dermatol. 2014;13(suppl 12):s101-s107.

INTRODUCTION

Since the publication of the landmark article by the National Rosacea Society in 2002, which introduced a standard classification system for rosacea, there has been a plethora of basic science and clinical research publications addressing the clinical presentations of rosacea and the underlying pathophysiologic mechanisms that appear to correlate with specific visible manifestations.¹⁻⁶ The magnitude of the individual contribution of each of these mechanisms can vary among different patients, thus accounting for the range of differences in the clinical presentations of rosacea.^{3,4,7-9}

The 2 main pathophysiologic mechanisms fundamental to rosacea that have been reported based on several studies are neurovascular dysregulation and abnormal immune detection and response, with both signaled by a variety of exogenous triggers.³⁻¹³ A greater understanding of these underlying pathophysiologic pathways has led to improved correlations between the clinical features of rosacea and the integration of specific therapies, although much more research needs to be completed to achieve further understanding because the pathophysiology of rosacea and the natural history of its progression are complex.^{3-5,14,15} The current belief is that rosacea, especially in its most common clinical presentations, is an inflammatory facial skin disorder most commonly affecting adults who are affected by rosacea-prone skin.^{3-6,10,11,16,17} Essentially, rosacea-prone skin is “wired differently,” with the facial skin of those with rosacea

exhibiting physiochemical, neurovascular, and microanatomic and ultrastructural differences compared with normal skin.^{3-13,15-17} Various triggers that have been noted to incite flares of rosacea (such as ambient heat, ultraviolet light exposure, spicy foods, and *Demodex* mite proliferation) induce the onset of central facial vasodilation and cutaneous inflammation due to the heightened responsiveness of both neurovascular and innate immunologic pathways associated with rosacea-prone skin.^{3-12,16,17}

Most of the development of medical therapies for rosacea occurred while the pathophysiology was not well understood.^{1,5,13} As a result, researchers were limited by the absence of specific targets against which to direct therapies, which hampered the development of therapeutic agents for rosacea.⁵ Prior to 2013, only 3 medical therapies have been submitted to the United States (US) Food and Drug Administration (FDA) for approval for rosacea, with all 3 receiving an approved indication for the inflammatory lesions (papules and pustules) of rosacea, commonly referred to as papulopustular rosacea (PPR). These 3 agents are topical metronidazole (first formulation 0.75% gel, approved in 1988; 0.75% and 1% available subsequently in multiple formulations); azelaic acid (AzA) 15% gel (approved in 2002); and doxycycline 40 mg modified-release capsule once daily (doxy-MR 40 mg QD, approved in 2006).^{15,18} Most recently, alpha-adrenergic agonists (brimonidine 0.33% gel, approved in August 2013; oxymetazoline in Phase 3 studies) have been

developed specifically to treat persistent non-transient facial erythema of rosacea through vasoconstriction of chronically enlarged and dilated superficial vasculature of the central face, which is commonly referred to as *background erythema*.^{5,13-16}

It is important that clinicians recognize that background erythema is a visible manifestation of rosacea which is both clinically and pathophysiologically distinct from papulopustular lesions and inflammatory erythema induced by pathways of inflammation that are activated during flares of rosacea.^{1,5,13,15,16} Topical metronidazole, AzA 15% gel, and doxy-MR 40 mg QD are approved by the FDA for rosacea based on studies completed only in subjects with PPR; studies completed with these agents for cutaneous rosacea subsequent to FDA approval have also been performed only in patients with PPR.^{3,5,13-18} The approved indication for all 3 of these agents, as stated in their current product labeling (package inserts), is for treatment of the inflammatory lesions (papules and pustules) of rosacea, with none of these agents evaluated in patients with rosacea who did not have papulopustular lesions. Topical metronidazole (all strengths and formulations), AzA 15% gel, and doxy-MR 40 mg QD are not FDA-approved specifically for facial erythema of rosacea as a "stand alone" indication. However, AzA 15% gel (n=333) demonstrated statistically significantly greater reduction in overall facial erythema scores compared with vehicle gel (n=331) in both Phase 3 pivotal trials ($P=.0017$ study 1; $P=.0005$ study 2) performed in subjects with PPR, compared with topical metronidazole formulations and doxy-MR 40 mg QD, which did not achieve statistically significant reduction in overall facial erythema in all Phase 3 studies in subjects with PPR.¹⁹⁻²¹ It is important to recognize that overall facial erythema of rosacea in a patient with a flare PPR is distinct from background erythema, which is persistent, non-transient, and present between rosacea flares.^{3-4,14,16}

"A summary of data on azelaic acid 15% gel serves to maintain a clinically relevant perspective of the therapeutic value of this agent in the management of rosacea."

As a result of the statistical consistency of reduction in overall facial erythema in subjects with PPR treated with AzA 15% gel, the approved FDA indication statement is the following: "[AzA 15% gel] is indicated for topical treatment of inflammatory papules and pustules of mild to moderate rosacea. Efficacy for treatment of erythema in rosacea in the absence of papules and pustules has not been evaluated."²² This labeling serves to distinguish facial erythema related to the augmented inflammation present in patients with active PPR from the

persistent and non-transient background erythema related to fixed dilatation and enlargement of centrafacial superficial cutaneous vasculature.^{4,5,11,12,15,16,22,23} However, it is also important to recognize that AzA 15% gel markedly reduced both papulopustular lesions and overall facial erythema in pivotal Phase 3 studies, both of which are clinical signs associated with augmented inflammation present in rosacea patients with centrafacial erythema and papulopustular lesions.¹⁹

This supplement reviews the treatment of rosacea with emphasis on the track record of data with AzA 15% gel, which has been available in the US marketplace for over a decade. Also included are important considerations related to its formulation and optimal use, newer information on pharmacologic properties of AzA that appear to correlate with possible modes of therapeutic action in rosacea, and new horizons related to formulation development.

A Panoramic Review of Azelaic Acid 15 % Gel Properties and Study Outcomes

The formulation characteristics, efficacy, skin tolerability, and safety of AzA 15% gel have been thoroughly reviewed elsewhere.^{19,24-39} Nevertheless, a summary of data on AzA 15% gel serves to maintain a clinically relevant perspective of the therapeutic value of this agent in the management of rosacea.

Azelaic Acid: The Molecule

Azelaic acid (1,7-heptanedicarboxylic acid) is a naturally occurring dicarboxylic acid, which exists as a white, odorless, large-particulate crystalline powder that is soluble in ethanol and not highly soluble in water.^{25,40}

Azelaic acid is a naturally occurring organic compound found in grains such as wheat, barley, and rye. Application of AzA 15% gel does not result in systemic accumulation of AzA, with plasma concentrations not increasing above levels reflective of usual nutritional ingestion and endogenous metabolism (formed from the metabolism of larger chain dicarboxylic acids, ie, oleic acid).^{25,40,41}

Vehicle Formulation

Azelaic acid 20% cream was the initial formulation approved by the FDA in 1995 for the topical treatment of inflammatory acne vulgaris.⁴² The decision to reformulate AzA in the 15% gel was due to improvements in the cutaneous delivery of AzA.²⁵

- The vehicle gel formulation improved the pharmacologic characteristics of AzA through micronization of the AzA crystals to create a uniformly small particle size; incorporation into an aqueous-based gel (70% water) using polyacrylic acid and lecithin to form the gel matrix as dispersers and thickening agents; and using polysorbate 80 as an emulsifier and stabilizer of the aqueous formulation.^{25,40,41}

- The percutaneous penetration of AzA was shown to be approximately 8-fold greater after application of AzA 15% gel compared with AzA 20% cream based on results from an in vitro Franz flow-through diffusion cell test in murine skin.²⁵

Skin Barrier Effects

Sensitive skin is common in rosacea patients, with increased centofacial transepidermal water loss reported in those with centofacial erythema both with and without papulopustular lesions.^{1,5,13,43}

- Application-site stinging and/or burning, reported in a subset of patients treated with AzA 15% gel, are usually transient in duration, mild to moderate in severity, no longer occurring after the first week to a few weeks of use in many patients, and not commonly resulting in discontinued use of the AzA 15% gel.^{19,25,26,28,36,44} These symptoms are not associated with visible skin changes suggestive of contact dermatitis or contact urticaria, but rather are neurosensory and idiosyncratic in nature.³⁸
- Regular proper skin care with a gentle cleanser and well-formulated moisturizer has been shown to reduce the likelihood, frequency, and intensity of stinging and burning after application of AzA 15% gel in most rosacea patients who experience these idiosyncratic effects.^{15,24,25,44,45}
- An in vitro modified Franz diffusion chamber test performed with human skin showed that applying 1 of 3 studied brand moisturizer lotions (CeraVe® Moisturizing Lotion, Cetaphil® Moisturizing Lotion, Dove® lotions) before applying AzA 15% gel did not reduce the percutaneous penetration of AzA, and in some cases resulted in an incremental increase in percutaneous penetration compared with applying the moisturizer after applying the AzA 15% gel. The study results suggested that any of the 3 tested moisturizers may be applied either before or after AzA 15% gel without a major change in the percutaneous penetration/absorption profile of AzA.³⁹
- In a split-face, investigator-blinded, 12-week study of 40 subjects with PPR, the idiosyncratic neurocutaneous symptoms of stinging and burning that affect a subset of rosacea patients treated with AzA 15% gel were shown not to be related to worsening of the epidermal permeability barrier function by the medication.⁴⁶ One side of the face was treated with AzA 15% gel twice daily, and the other side remained untreated. The results were as follows:

- Decline in skin hydration measured by corneometry was greater on the untreated side. There was an increase in skin hydration at week 1 compared with baseline on the AzA-treated side ($P=.009$).

- Investigator assessments of parameters such as facial erythema, desquamation, and overall facial appearance were scored using a 6-point ordinal scale (Table 1). Subjects used this same scale to report symptoms.
- A statistically significant decrease in overall facial erythema was also noted on the treated side at week 2 ($P=.003$) and week 4 ($P<.001$) (Figure 1).
- Overall facial appearance assessment was statistically superior on the treated side at week 2 ($P=.005$) and week 4 ($P<.001$).
- A statistically significant decrease in desquamation was noted on the treated side over the untreated side at each time point ($P<.001$) (Figure 2).
- Longitudinal analysis showed an increase in desquamation on the untreated side at 48 hours, week 1, week 2, and week 4 (Figure 2).
- There was no increase noted in facial stinging and itching at any time point on the treated side. By week 4, there was a reduction in itching in both groups.

This study supports that AzA 15% gel does not appear to induce impairment of the epidermal permeability barrier, and improves signs and symptoms of rosacea, including skin changes inherent to rosacea-prone facial skin. This supports that the disease state itself is associated with epidermal permeability barrier impairment that is often not visibly evident or may present with visible signs such as fine facial scaling ("rosacea dermatitis").^{5,43-46}

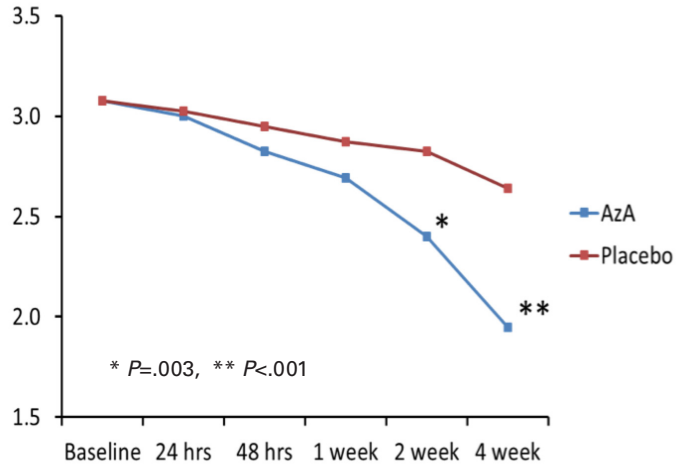
TABLE 1.

Assessment Rating Scale: Split-Face Study of Azelaic Acid 15% Gel Twice Daily on Treated Side vs Untreated Side

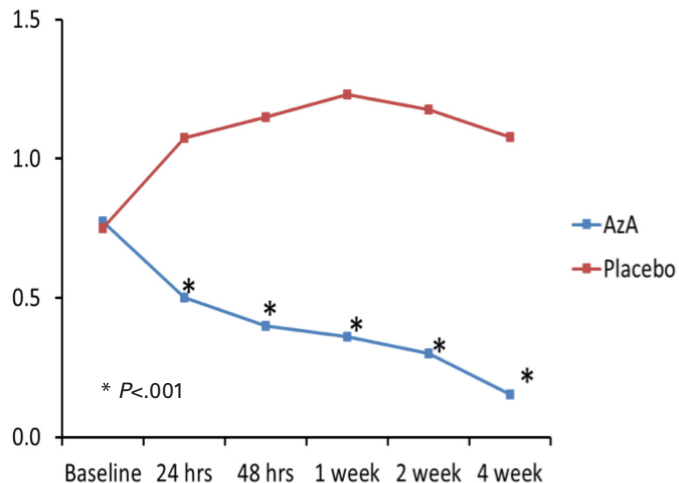
Rating	Assessment
0	None
1	Minimal
2	Mild
3	Moderate
4	Moderately Severe
5	Severe

Efficacy and Safety

The efficacy and safety of AzA 15% gel for PPR have been demonstrated in multiple studies, both as monotherapy and in combination with oral therapy (ie, doxycycline); no major cutaneous or systemic safety issues have been associated with AzA 15% gel.^{19,26-29,31-34,36,37}

FIGURE 1. Investigator assessment of overall facial erythema. Split-face study of azelaic acid 15% gel twice daily on treated side vs untreated side.

AzA, azelaic acid 15% gel.

FIGURE 2. Investigator assessment of facial desquamation. Split-face study of azelaic acid 15% gel twice daily on treated side vs untreated side.

AzA, azelaic acid 15% gel.

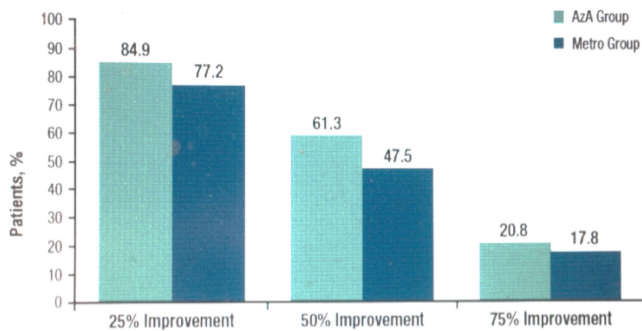
- Use of AzA 15% gel in combination with oral doxycycline expedites clinical improvement of PPR, especially in patients presenting with greater disease severity.³¹⁻³⁴ Once adequate control of a PPR flare was achieved within 1 to 3 months, AzA 15% gel applied twice daily proved to sustain satisfactory control of PPR in 75% of treated subjects over 6 months of follow-up.³²
- The approved application frequency with AzA 15% gel is twice daily as this was the frequency in the pivotal studies submitted to obtain approval.^{19,26,40} However, if patients with PPR end up applying AzA 15% gel once a day, there are published data to support comparable efficacy to twice-daily application.³⁷

- In a 12-week study of PPR patients treated with doxy-MR 40 mg once daily in combination with either AzA gel 15% twice daily (n=106) or metronidazole 1% gel (metro 1%) once daily (n=101), efficacy parameters supported that both combination regimens were effective, with a trend toward earlier and greater therapeutic benefit with the AzA-based regimen than with the metronidazole-based regimen. Nominal differences were noted, but most were not statistically significant.³³
 - Subjects at baseline in both groups had a mean lesion count of approximately 20 papules and pustules, most patients were rated as moderate severity by investigator global assessment (IGA), and all had at least mild overall facial erythema.³³
 - After 2 weeks of treatment, a 25% reduction of papules and pustules was achieved by almost 85% of subjects in the AzA 15% gel group, with 61.3% and 20.8% of them achieving 50% and 75% reduction in papulopustular lesions, respectively. The percent lesion reductions observed in the metro 1% group were lower for each clearance category at each time point (Figure 3).
 - The percentage of patients achieving "treatment success" (IGA score of clear or minimal) was higher in the AzA 15% gel group compared with the metro 1% group at each time point. Statistical significance was reached at week 6 (P=.0097) (Figure 4).

The results of this study demonstrate comparable results in both groups, with support of an overall trend of quicker response and slightly greater efficacy in the AzA 15% gel treatment arm.³³

New Information on Possible Modes of Action of Azelaic Acid in Rosacea

In 2008, the American Acne and Rosacea Society (AARS) published recommendations on the medical management of rosacea based on the most current research and clinical data available.¹⁸ These recommendations suggest the initial use of medical therapy that decreases the inflammation of rosacea (especially PPR) without the need for an antibiotic effect as there is no evidence that a bacterium is integral to the pathogenesis of rosacea, a concept that is well-supported based on currently available evidence.^{6,11,13,18-20} Most recently, the AARS has published current recommendations on the management of rosacea that address the most common presentations of the disease – central facial erythema without papulopustular lesions (commonly referred to as erythematotelangiectatic rosacea) and central facial erythema with papulopustular lesions (commonly referred to as papulopustular lesions).⁴⁷ These

FIGURE 3. Percentage of subjects achieving 25%, 50%, and 75% or greater improvement in inflammatory lesion counts from baseline to week 2.^a

AzA, azelaic acid 15% gel; Metro, metronidazole 1% gel.

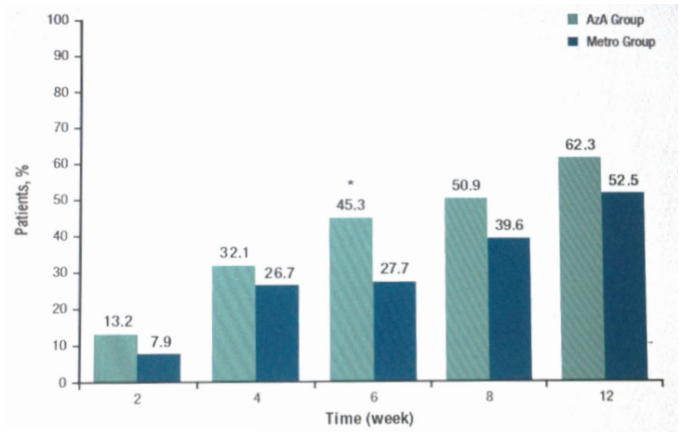
^aSubjects treated with doxycycline 40 mg modified-release once daily and either azelaic acid 15% gel or metronidazole 1% gel.

current AARS recommendations emphasize selecting therapy based on correlation with the clinical manifestations present in the individual patient and, as best as possible, the pathophysiologic mechanisms that are likely to be contributory.

Azelaic acid 15% gel was approved by the FDA on December 24 2002 for the treatment of papulopustular lesions of rosacea.²² The statement “the mechanism(s) by which azelaic acid interferes with the pathogenic events in rosacea are unknown” was written in the approved product labeling over a decade ago.⁴⁰ Azelaic acid has been shown to exhibit multiple pharmacologic properties.^{24,48} These include:

- Reduction in follicular keratinization in human skin in vivo and in vitro.
- In vitro evidence of antioxidant effects, including scavenger activity against hydroxyl radicals, inhibition of hydroxyl radical-induced toxicity, and inhibition of oxyradical release from neutrophils.
- Competitive inhibition of tyrosinase and inhibition of mitochondrial respiratory enzymes in abnormal melanocytes.

Comedolytic activity and reduction in follicular keratinization support the development and FDA approval of AzA 20% cream for the treatment of inflammatory acne vulgaris. However, other than a possible contribution by antioxidant activity (if it occurs in vivo in rosacea-affected skin), none of the aforementioned pharmacologic effects of AzA are known to correlate with pathophysiologic mechanisms thought to be operative in rosacea. It is important to recognize that approved product labeling does not necessarily reflect current evidence related to how a given therapeutic agent may modulate the pathophysiology of disease, and that product labeling is not automatically updated by the FDA based on new evidence.

FIGURE 4. Percentage of patients achieving treatment success (investigator global assessment score of clear or minimal) at each time point.^a

* $P=0.0097$

AzA, azelaic acid 15% gel; Metro, metronidazole 1% gel.

^aSubjects treated with doxycycline 40 mg modified-release once daily and either azelaic acid 15% gel or metronidazole 1% gel.

The augmented immune response and detection that is characteristic of rosacea-prone skin refers primarily to studies demonstrating upregulation of the cathelicidin (LL-37) production pathway in the facial skin of patients with PPR.^{4,9-12}

The increased expression of toll-like receptor-2 (TLR2) is also consistent with the hyper-responsive nature of central facial skin of rosacea when exposed to exogenous trigger factors.⁹ Interestingly, over the past 5 years, a series of in vitro studies performed with murine or human skin showed that AzA directly inhibited the following: (1) kallikrein 5 (KLK5) in cultured keratinocytes, (2) gene expression of KLK5, (3) TLR2 expression, and (4) cathelicidin (LL-37) formation.^{12,49} An in vivo 16-week study performed in patients with PPR demonstrated that cathelicidin and KLK5 activity decrease with AZA 15% gel exposure; subjects with rosacea showed reduction in cathelicidin and KLK5 messenger RNA after treatment with AzA 15% gel twice daily.⁴⁹ These data performed in keratinocyte cell cultures, in murine skin, and in the facial skin of adult subjects with PPR support that inhibition of the up-regulated cathelicidin pathway and possibly inhibition of TLR2 expression in rosacea-affected skin at least partially explain the therapeutic effects of AzA 15% gel in patients with PPR.

The efficacy of AzA 15% gel is greatest in those subjects with PPR who exhibit higher baseline levels of KLK5, further supporting this mode of action.⁴⁹

This information on possible modes of action of AzA in PPR may also account to some extent for the observation of augmented benefit when AzA 15% gel is used in combination with doxycycline because this latter agent inhibits the upregulated cathelicidin pathway at a different step in the cathelicidin cascade of inflammation (inhibition of matrix metalloproteinases).^{12,50}

New Horizons With Azelaic Acid 15%

An oil-in-water emulsion foam formulation of micronized AzA 15% is under development and has been evaluated through the stage of Phase 3 clinical studies.⁵¹ A randomized, double-blind, vehicle-controlled, multicenter, parallel-group study was conducted over 12 weeks with a 4-week follow-up period, evaluating the efficacy and safety of AzA 15% foam (n=198) applied twice daily compared with a vehicle foam (n=203) applied twice daily in adult subjects with moderate PPR (approximately 90% of subjects) or severe PPR (approximately 10% of subjects).⁵¹ Primary efficacy variables assessed were IGA dichotomized into success and failure, and nominal change in inflammatory lesion count from baseline to end of treatment. The mean inflammatory lesion count at baseline was 21.6 in the AzA 15% foam group and 20.4 in the vehicle foam group.

- At week 12 (end of treatment), 43.4% of AzA 15% foam-treated subjects achieved treatment success (IGA score of clear or minimal) compared with 32.5% in the vehicle arm ($P=.17$).
- At week 12, the mean nominal inflammatory lesion reduction and mean percent reduction in inflammatory lesions were -13.4 and 65.4% respectively in the AzA 15% foam group, and -9.5 and 51% respectively in the vehicle foam group ($P<.001$, both parameters).
- Skin tolerability was favorable in both study groups. Application site burning sensation, stinging, and pruritus were reported as 1.5%, 2.5%, and 1.5% respectively in the AzA 15% foam study group, and as 0% for all 3 parameters in the vehicle foam study group. Importantly, this low number of subjects experiencing stinging and/or burning occurred despite the protocol not mandating use of designated gentle skin care products.⁵¹

Study outcomes show that the new foam formulation of AzA 15% is effective and well-tolerated in patients with moderate to severe PPR. Although no single formulation is appropriate for all patients, the availability of multiple vehicles assists the clinician in matching the needs and preferences of individual patients, especially given the favorable tolerability reported in the Phase 3 data with AzA 15% foam.⁵¹

CONCLUDING REMARKS

Azelaic acid 15% gel boasts a long track record of both efficacy and safety for the treatment of PPR. The optimal use of AzA 15% gel is with concurrent proper skin care, either as monotherapy in patients with mild to moderate PPR, or in combination with oral therapy (ie, doxycycline) in patients with moderate to severe PPR. Once adequate control of PPR is achieved, AzA 15% gel can be continued without the oral agent to sustain the reduction in papulopustular lesions and associated inflammatory erythema.

There is some suggestive evidence that when used in combination with doxy-MR 40 mg QD, AzA 15% gel may provide a slightly quicker onset and greater magnitude of improvement of PPR overall than metro 1%. Although the differences are incremental based on study data, it may be clinically relevant in some patients who are anxious to see improvement, especially due to the chronicity of their disease.

There are new data supporting the anti-inflammatory activity of AzA through reduction of the cathelicidin pathway that is upregulated in rosacea-affected skin. If patients are not fully compliant and are using AzA 15% gel once daily instead of twice daily, there is comfort in knowing that once-daily application proved to be comparable to twice-daily application in patients with PPR. Lastly, the development of AzA 15% foam offers another vehicle option, and provides efficacy, safety, and a low incidence of skin tolerability reactions based on pivotal trial outcomes.

"Study outcomes show that the new foam formulation of azelaic acid 15% is effective and well-tolerated in patients with moderate to severe papulopustular rosacea."

DISCLOSURES

This publication was supported by Bayer Healthcare. No one at Bayer Healthcare or any affiliated agency influenced the content of this publication. Only the authors participated in content and publication interactions.

Dr. Del Rosso has served as a consultant, advisory board participant, clinical investigator, and/or speaker for Allergan, Anacor, Aqua, Bayer Healthcare (Dermatology), Celgene, Dermira, Ferndale, Galderma, Innocutis, LeoPharma, Merz Pharmaceuticals, Pharmaderm, Promius, PuraCap, Ranbaxy, Sebacia, Taro Pharmaceuticals, Unilever, and Valeant Pharmaceuticals.

Dr. Kircik has served as an advisor, investigator, consultant, and speaker for Allergan, Bayer, Galderma, Promius Pharma, Quinova, Stiefel/GSK, LeoPharma, Taro, Valeant, and Warner-Chilcott.

REFERENCES

1. Wilkin J, Dahl M, Detmar M, et al. Standard classification of rosacea: Report of the National Rosacea Society Expert Committee on the Classification and Staging of Rosacea. *J Am Acad Dermatol*. 2002;46(4):584-587.
2. Bikowski JB, Goldman MP. Rosacea: where are we now? *J Drugs Dermatol*. 2004;3(3):251-261.
3. Del Rosso JQ, Gallo RL, Tangheiti E, Webster G, Thiboutot D. An evaluation of potential correlations between pathophysiologic mechanisms, clinical manifestations, and management of rosacea. *Cutis*. 2013;91(suppl 3):s1-s8.
4. Fleischer AB Jr. Inflammation in rosacea and acne: Implications for patient care. *J Drugs Dermatol*. 2011;10(6):614-620.

5. Del Rosso JQ. Advances in understanding and managing rosacea: part 1: connecting the dots between pathophysiological mechanisms and common clinical features of rosacea with emphasis on vascular changes and facial erythema. *J Clin Aesthet Dermatol.* 2012;5(3):16-25.
6. Steinhoff M, Schaubert J, Leyden JJ. New insights into rosacea pathophysiology: a review of recent findings. *J Am Acad Dermatol.* 2013;69(6 suppl 1):s15-s26.
7. Steinhoff M, Buddenkotte J, Aubert J, et al. Clinical, cellular, and molecular aspects in the pathophysiology of rosacea. *J Invest Dermatol Symp Proc.* 2011;15(1):2-11.
8. Schwab VD, Sulk M, Seeliger S, et al. Neurovascular and neuroimmune aspects in the pathophysiology of rosacea. *J Invest Dermatol Symp Proc.* 2011;15(1):53-62.
9. Yamasaki K, Kanada K, Macleod DT, et al. TLR2 expression is increased in rosacea and stimulates enhanced serine protease production by keratinocytes. *J Invest Dermatol.* 2011;131(3):688-697.
10. Yamasaki K, Gallo RL. Rosacea as a disease of cathelicidins and skin innate immunity. *J Invest Dermatol Symp Proc.* 2011;15(1):12-15.
11. Yamasaki K, Gallo RL. The molecular pathology of rosacea. *J Dermatol Sci.* 2009;55(2):77-81.
12. Two AM, Del Rosso JQ. Kallikrein 5-mediated inflammation in rosacea: clinically relevant correlations with acute and chronic manifestations in rosacea and how individual treatments may provide therapeutic benefit. *J Clin Aesthet Dermatol.* 2014;7(1):20-25.
13. Crawford GH, Pelle MT, James WD. Rosacea: I. Etiology, pathogenesis, and subtype classification. *J Am Acad Dermatol.* 2004;51(3):327-341.
14. Layton A, Thiboutot D. Emerging therapies in rosacea. *J Am Acad Dermatol.* 2013;69(6 suppl 1):s57-s65.
15. Del Rosso JQ. Management of cutaneous rosacea: emphasis on new medical therapies. *Expert Opin Pharmacother.* 2014;15(14):2029-2038.
16. Del Rosso JQ. Management of facial erythema of rosacea: what is the role of topical α -adrenergic receptor agonist therapy? *J Am Acad Dermatol.* 2013;69(6 suppl 1):s44-s56.
17. Del Rosso JQ, Gallo RL, Kircik L, Thiboutot D, Baldwin HE, Cohen D. Why is rosacea considered to be an inflammatory disorder? The primary role, clinical relevance, and therapeutic correlations of abnormal innate immune response in rosacea-prone skin. *J Drugs Dermatol.* 2012;11(6):694-700.
18. Del Rosso JQ, Baldwin H, Webster G; American Acne & Rosacea Society. American Acne & Rosacea Society rosacea medical management guidelines. *J Drugs Dermatol.* 2008;7(6):531-533.
19. Thiboutot D, Thieroff-Ekerdt R, Graupe K. Efficacy and safety of azelaic acid (15%) gel as a new treatment for papulopustular rosacea: results from two vehicle-controlled, randomized phase III studies. *J Am Acad Dermatol.* 2003;48(6):836-845.
20. Del Rosso JQ, Webster GF, Jackson M, et al. Two randomized phase III clinical trials evaluating anti-inflammatory dose doxycycline (40-mg doxycycline, USP capsules) administered once daily for treatment of rosacea. *J Am Acad Dermatol.* 2007;56(5):791-802.
21. McClellan KJ, Noble S. Topical metronidazole: a review of its use in rosacea. *Am J Clin Dermatol.* 2000;1(3):191-199.
22. Azelaic acid 15% gel (Finacea®), Full Prescribing Information, Bayer HealthCare Pharmaceuticals Inc, Whippany, New Jersey, 2014.
23. Rosina P, Zamperetti MR, Giovannini A, et al. Videocapillaroscopic alterations in erythematotelangiectatic rosacea. *J Am Acad Dermatol.* 2006;54(1):100-104.
24. Fleischer AB Jr. The evolution of azelaic acid. *Cutis.* 2006;77(suppl 2):s4-s6.
25. Draelos ZD. The rationale for advancing the formulation of azelaic acid vehicles. *Cutis.* 2006;77(suppl 2):s7-s11.
26. Elewski B, Thiboutot D. A clinical overview of azelaic acid. *Cutis.* 2006;77(suppl 2):s12-s16.
27. Liu RH, Smith MK, Basta SA, Farmer ER. Azelaic acid in the treatment of papulopustular rosacea: a systematic review of randomized controlled trials. *Arch Dermatol.* 2006;142(8):1047-1052.
28. Del Rosso JQ, Bhatia N. Azelaic acid gel 15% in the management of papulopustular rosacea: a status report on available efficacy data and clinical application. *Cutis.* 2011;88(2):67-72.
29. Elewski BE, Fleischer AB Jr, Pariser DM. A comparison of 15% azelaic acid gel and 0.75% metronidazole gel in the topical treatment of papulopustular rosacea: results of a randomized trial. *Arch Dermatol.* 2003;139(11):1444-1450.
30. Kennedy Carney C, Cantrell W, Elewski BE. Rosacea: a review of current topical, systemic and light-based therapies. *G Ital Dermatol Venereol.* 2009;144(6):673-688.
31. Fleischer A, Suephy C. The face and mind evaluation study: an examination of the efficacy of rosacea treatment using physician ratings and patients' self-reported quality of life. *J Drugs Dermatol.* 2005;4(5):585-590.
32. Thiboutot DM, Fleischer AB, Del Rosso JQ, Rich P. A multicenter study of topical azelaic acid 15% gel in combination with oral doxycycline as initial therapy and azelaic acid 15% gel as maintenance monotherapy. *J Drugs Dermatol.* 2009;8(7):639-648.
33. Del Rosso JQ, Bruce S, Jarratt M, Menter A, Staedtler G. Efficacy of topical azelaic acid (AzA) gel 15% plus oral doxycycline 40 mg versus metronidazole gel 1% plus oral doxycycline 40 mg in mild-to-moderate papulopustular rosacea. *J Drugs Dermatol.* 2010;9(6):607-613.
34. Bhatia ND, Del Rosso JQ. Optimal management of papulopustular rosacea: rationale for combination therapy. *J Drugs Dermatol.* 2012;11(7):838-844.
35. Del Rosso JQ, Baum EW, Draelos ZD, et al. Azelaic acid gel 15%: clinical versatility in the treatment of rosacea. *Cutis.* 2006;78(suppl 5):s6-s19.
36. Del Rosso JQ. Medical treatment of rosacea with emphasis on topical therapies. *Expert Opin Pharmacother.* 2004;5(1):5-13.
37. Thiboutot DM, Fleischer AB Jr, Del Rosso JQ, Graupe K. Azelaic acid 15% gel once daily versus twice daily in papulopustular rosacea. *J Drugs Dermatol.* 2008;7(6):541-546.
38. Draelos ZD. Noxious sensory perceptions in patients with mild to moderate rosacea treated with azelaic acid 15% gel. *Cutis.* 2004;74(4):257-260.
39. Del Rosso JQ, Lehman PA, Raney SG. Impact of order of application of moisturizers on percutaneous absorption kinetics: evaluation of sequential application of moisturizer lotions and azelaic acid gel 15% using a human skin model. *Cutis.* 2009;83(3):119-124.
40. Azelaic acid 15% gel (Finacea®), NDA 21-470, Approved labeling, Center for Drug Evaluation and Research, US Food and Drug Administration, 12/24/02.
41. Azelaic acid 15% gel (Finacea®), Drug approval package (NDA 21-470), US Food and Drug Administration.
42. Azelaic acid 20% cream (Azelex®) [package insert]. Irvine, California: Al-lergan Inc; 2013.
43. Dirschka T, Tronnier H, Fölster-Holst R. Epithelial barrier function and atopic diathesis in rosacea and perioral dermatitis. *Br J Dermatol.* 2004;150(6):1136-1141.
44. Del Rosso JQ, Baum EW. Comprehensive medical management of rosacea: an interim study report and literature review. *J Clin Aesthet Dermatol.* 2008;1(1):20-25.
45. Del Rosso JQ. The use of moisturizers as an integral component of topical therapy for rosacea: clinical results based on the Assessment of Skin Characteristics Study. *Cutis.* 2009;84(2):72-76.
46. Draelos ZD. The effect of topical azelaic acid gel 15% in barrier restoration. Poster presentation. Caribbean Dermatology Seminar, Skin Disease Education Foundation, 2014.
47. Del Rosso JQ, Thiboutot D, Gallo R, et al. Consensus recommendations from the American Acne & Rosacea Society on the management of rosacea, part 5: a guide on the management of rosacea. *Cutis.* 2014;93(3):134-138.
48. Mayer-da-Silva A, Gollnick H, Detmar M, et al. Effects of azelaic acid on sebaceous gland, sebum excretion rate and keratinization pattern in human skin: an in vivo and in vitro study. *Acta Derm Venereol Suppl (Stockh).* 1989;143:20-30.
49. Coda AB, Hata T, Miller J, et al. Cathelicidin, kallikrein 5, and serine protease activity is inhibited during treatment of rosacea with azelaic acid 15% gel. *J Am Acad Dermatol.* 2013;69(4):570-577.
50. Kanada KN, Nakatsuji T, Gallo RL. Doxycycline indirectly inhibits proteolytic activation of tryptic kallikrein-related peptidases and activation of cathelicidin. *J Invest Dermatol.* 2012;132(5):1435-1442.
51. Draelos ZD, Elewski B, Staedtler G, Havlickova B. Azelaic acid foam 15% in the treatment of papulopustular rosacea: a randomized, double-blind, vehicle-controlled study. *Cutis.* 2013;92(6):306-317.

AUTHOR CORRESPONDENCE

James Q. Del Rosso DO FAOCD

E-mail:.....jqdelrosso@yahoo.com