

Thermal Imaging for Cryotherapy Documentation in Dermatology Practice

Katherine B. Lee MD^a

^aHalcyon Dermatology, Laguna Hills, CA

To the Editor,

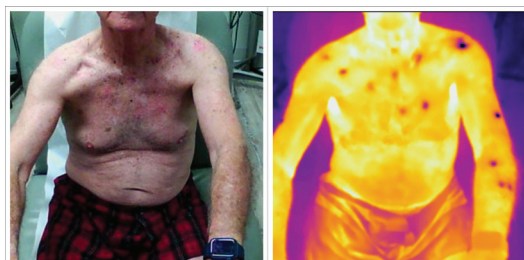Liquid Nitrogen (LN₂) is one of the most common dermatologic procedures performed by dermatologists and other physicians. Actinic keratoses (AK), seborrheic keratoses (SK), and warts are the most common lesions treated with LN₂. The 2023 CMS data and research statistics listed code 17110, destruction of benign lesions up to 14, and code 17000, destruction of premalignant lesions 1st, in the top 200 billed codes. Allowed services totaled 3,037,446 for code 17110 and 6,114,068 for code 17000 in 2023.¹

To administer LN₂, providers typically will hold a cryocanister in one hand while feeling for skin lesions with the other hand. Dermatologists often treat between 1 and 50 or more distinct sites per encounter, and scribes are often used to record the location, number, and diagnosis of each lesion. This current workflow inefficiency is associated with rapidly increasing labor costs and declining reimbursement. Without a scribe, providers rely on recall to document LN₂ treatments. Visible cameras, as well as ambient artificial intelligence (AI) audio scribes, are of limited use in cryotherapy because they cannot accurately capture the locations of LN₂-treated lesions (Figure 1). AI-scribes fail to address the practical needs of dermatology providers who spend a large portion of their visits administering LN₂. We report a novel solution that enables providers to perform and document liquid nitrogen simultaneously.

FIGURE 1. SK photographed 3 seconds after treatment (not visible).



FIGURE 2. Visible and corresponding thermal images of multiple AK lesions photographed 3 seconds after treatment.



The Technique

While visible imaging cannot capture LN₂-treatment sites, thermal imaging can capture cryotherapy sites with precision (Figure 2). Cryotherapy-treated lesions appear as foci of cooler temperatures on thermal imaging and undergo temporal decay as they warm. When treating an AK for 10 seconds with a 1–2 mm rim of LN₂, the AK will be visible on thermal imaging for approximately 1 minute after treatment.

We have developed a HIPAA-compliant solution that utilizes a lightweight adapter to attach an Android device with integrated visible and FLIR Lepton 3.5 thermal cameras to a cryocanister (Figure 3). After treating a region of lesions with LN₂, the provider can quickly tap the camera screen, capturing visible and thermal images of the area. These images are processed via an advanced machine learning (ML) pipeline for automated treatment site detection and anatomical mapping. The provider can quick-select diagnoses, tag lesions to observe, and download a summary report that allows for electronic medical record (EMR) integration (Figure 4).

Practical Implications

Thermal imaging has been used to assess skin conditions, including psoriasis, skin cancers, burns, and cosmetic treatments such as cryolipolysis.² To date, there are no reports on the use of thermal imaging for documentation of cryotherapy treatment sites. With current off-the-shelf thermal cameras, providers are unable to administer LN₂ and subsequently operate a thermal camera quickly enough before treated lesions become undetectable. Incorporation of this novel thermal imaging

FIGURE 3. The adapter and thermal camera attached to the cryocanister, and the provider performing cryotherapy while capturing



FIGURE 4. The downloadable treatment summary with corresponding composite diagram.

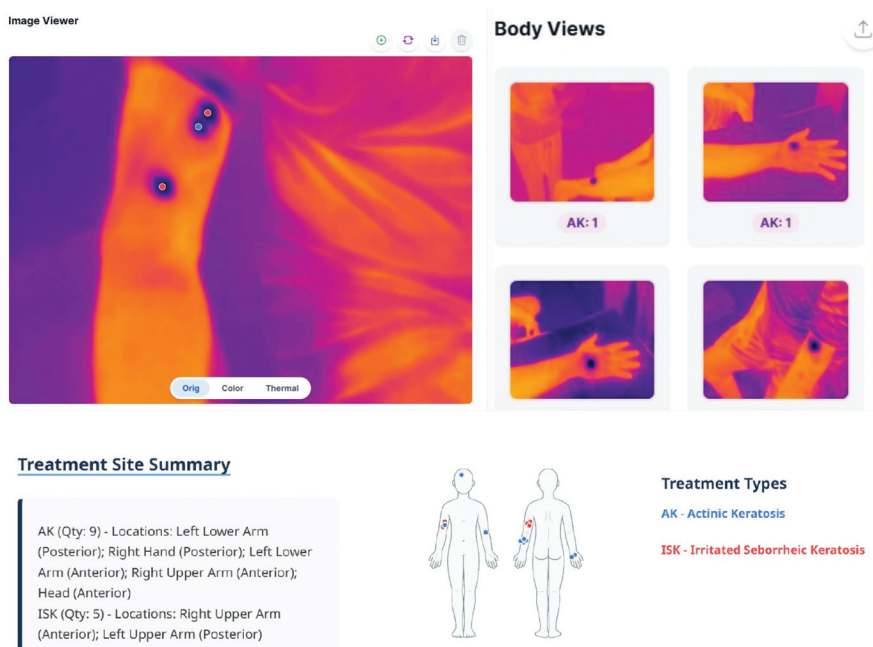
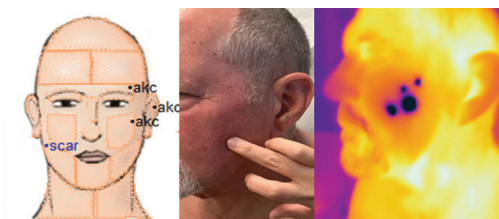


FIGURE 5. An EMR diagram showing a lack of specificity with manual cryotherapy charting, a visible image of an AK re-treated at multiple visits due to unclear charting, and a thermal image showing the precise location of treated sites.



technique into our charting will allow a provider to perform and document LN2 procedures independently and reduce labor costs.

With our current charting tools, providers may unknowingly re-treat the same lesions with LN₂ multiple times because the exact location of prior treatment sites could not be precisely recorded (Figure 5). Patient care will be improved because lesions that failed LN₂ can now be readily identified. As a low-cost solution, this novel technique efficiently captures the visual information needed to document LN₂ and fills a much-needed gap that current AI Scribes and dermatology-specific EMRs lack. Future studies will explore the diagnostic uses of thermal imaging after liquid nitrogen treatment in dermatology.

DISCLOSURES

Katherine B. Lee MD, has a patent pending for CryoCaptures. Dr Lee received an honorarium from the American Academy of Dermatology for CryoCaptures being named the 2025 Innovation Academy Derm Tank winner.

REFERENCES

- Centers for Medicare & Medicaid Services. Medicare fee-for-service statistics for Parts A and B: top 200 Level II CPT codes ranked by charges incurred. Accessed August 23, 2025. <https://www.cms.gov/data-research/statistics-trends-and-reports/medicare-fee-for-service-parts-a-b>.
- Vergilio MM, Gomes G, Aiello LM, et al. Evaluation of skin using infrared thermal imaging for dermatology and aesthetic applications. *J Cosmet Dermatol.* 2022;21(3):895-904. doi:10.1111/jocd.14748

AUTHOR CORRESPONDENCE

Katherine B. Lee MD
 E-mail:..... kathy@kathyleemd.com