

A SUPPLEMENT TO

JOURNAL OF DRUGS IN DERMATOLOGY

JDD

---

DRUGS • DEVICES • METHODS

---

REAL-WORLD CLINICAL EXPERIENCE  
COMBINING A NEURO-PEPTIDE SERUM AND  
BOTULINUM TOXIN TYPE-A INJECTIONS

ISSN: 1545 9616

November 2024 • Volume 23 • Issue 11 (SUPPLEMENT 2)

The real-world case series to the *Journal of Drugs in Dermatology* was supported by an unrestricted educational grant from SkinCeuticals International- L'Oréal Groupe.

# Real-World Clinical Experience With a Neuro-Peptide Serum in Combination With Botulinum Toxin Type-A Injections

Mark Lupin MD FRCPC,<sup>a</sup> Peter Bjerring MD Dr Sci,<sup>b</sup> Anneke Andriessen PhD,<sup>c</sup> Jonquille Chantrey MD,<sup>d</sup> Sabrina Guillen Fabi MD FAAD FAACS,<sup>e</sup> Steven Liew MD,<sup>f</sup> Cara McDonald MBBS BMedSci MPH FACD,<sup>g</sup> Qin Xiaolei MD,<sup>h</sup> Stacy White PhD<sup>i</sup>

<sup>a</sup>Cosmedica Laser Centre, Victoria, BC, Canada

<sup>b</sup>Department of Dermatology, Aalborg University Hospital, Aalborg, Denmark

<sup>c</sup>Radboud UMC Nijmegen, Andriessen Consultants, Malden, The Netherlands

<sup>d</sup>ØNE aesthetic studio, Alderley Edge, Cheshire, United Kingdom

<sup>e</sup>Cosmetic Laser Dermatology, San Diego;

University of California, San Diego, CA

<sup>f</sup>Shape clinic, Medical Director, Specialist Plastic Surgeon, Sydney, Australia

<sup>g</sup>St Vincent's Hospital, Director Complete Skin Specialists, Sunbury, Melbourne, Australia

<sup>h</sup>DEYI SKIN Dermatology Clinic, Shenzhen, China; <sup>i</sup>SkinCeuticals, New York, NY

## ABSTRACT

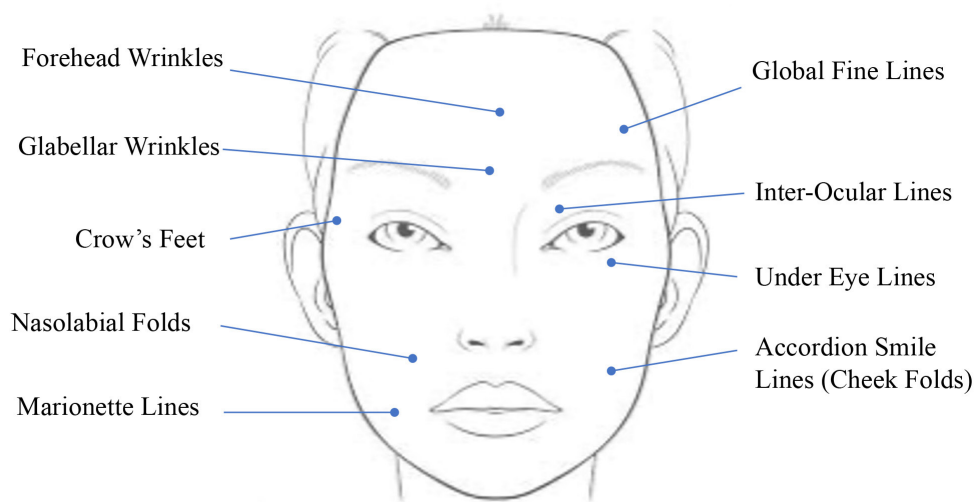
We evaluated real-life experiences of a topical neuro-peptide serum containing 2% acetyl hexapeptide-8, 2% dipeptide diaminobutyryl, 5% polyhydroxy acids (PHA), 5% niacinamide, and 1% laminaria extract (topical neuro-peptide serum [TNP-serum]). The TNP-serum works synergistically by stimulating 9 key skin biomarkers to reduce wrinkles and produce a skin-brightening effect. Here, we highlight the real-life experiences of 5 dermatologists and 2 surgeons, using an integrated skincare regimen consisting of botulinum toxin type-A (BTX-A) injection in conjunction with twice daily TNP-serum. Real-world cases provide evidence for combination treatments that may be used in cosmetic dermatology to improve patient outcomes and satisfaction. TNP-serum appears to complement BTX-A injections to improve radiance, reduce fine lines, and reduce wrinkles in diverse patients. Incorporating TNP-serum into integrated skincare regimens may offer an additive effect to BTX-A injections and, ultimately, optimize patient results.

*J Drugs Dermatol.* 2024;23:11(Suppl 2):s3-14.

## INTRODUCTION

By 2050, the World Health Organization (WHO) estimates that the world's population of people aged 65 years and older will have more than doubled from 761 million in 2021.<sup>1</sup> As the population and their skin ages, there will be an increasing demand for targeted treatments for skin rejuvenation. Skin ages in response to intrinsic and extrinsic factors.<sup>2</sup> Intrinsic aging occurs with chronological age and may be affected by hormonal status and comorbid disease.<sup>2</sup> Extrinsic aging occurs due to ultraviolet (UV) exposures, cigarette smoking, and other environmental factors.<sup>2</sup> It is estimated that over 80% of facial skin aging is due to long-term UV exposure that leads to skin roughening, wrinkling, dyschromia, and loss of skin elasticity.<sup>3</sup> Together, extrinsic and intrinsic factors lead to epidermal thinning, loss of elasticity, skin fragility, and wrinkles.

While benign, wrinkles can be particularly distressing for some patients and negatively impact their self-image and quality of life.<sup>4</sup> They form due to age-related dermal atrophy and repetitive contraction of muscles that may lead to wrinkling of the overlying skin.<sup>4</sup> Fine wrinkles (<1 mm in width and depth) and coarse wrinkles (>1 mm) can occur anywhere on the body, but have been most studied on the face, forearms, and hands.<sup>4</sup> On the face, dynamic wrinkles form perpendicular to the direction of muscle contraction.<sup>4</sup> Common dynamic wrinkles that are often treated include horizontal forehead lines, bunny lines (nasal lines), radial lip lines, marionette lines, frown lines, crow's feet (lateral canthal lines), accordion smile lines (cheek folds), nasolabial fold lines, and chin lines (Figure 1).<sup>4</sup>

**FIGURE 1.** Dynamic wrinkles that can be treated with the topical.

Age, cigarette smoking, sun exposure, pregnancy, and menopause significantly affect facial wrinkling severity.<sup>1</sup> In addition, wrinkling has been reported to be more common in Fitzpatrick skin types (FSTs) I and II, suggesting a link to photoaging.<sup>5</sup> Recommendations for wrinkle interventions through skincare largely consist of sunscreen, topical retinoids, alpha hydroxy acids, and topical vitamins C and E.<sup>6</sup> However, there have been minimal numbers of studies to investigate the effect of these agents on wrinkle reduction.<sup>6</sup> Low-grade evidence exists for the use of topical tazarotene, tretinoin, and isotretinoin creams, while topical alpha and beta hydroxy acids may have subtle effectiveness as wrinkle interventions.<sup>6</sup> Topical tretinoin has been shown to improve fine wrinkles compared with placebo; however, the vitamin A derivative can cause skin itching and burning and comes with the trade-off of increasing photosensitivity.<sup>6</sup>

BTX-A remains the mainstay of wrinkle treatment.<sup>7</sup> It was the first cosmetic treatment approved by the US Food and Drug Administration (FDA) for the treatment of glabellar frown lines in 2002.<sup>7</sup> It is most commonly used in the upper one-third of the face, while experienced injectors can also use it in the lower 2-thirds of the face. While the family of botulinum neurotoxins includes 7 subtypes, BTX-A is the most commonly used and is the most potent of the family.<sup>7</sup> The neurotoxin is derived from the *Clostridium*

*botulinum* bacterium, which inhibits muscle contraction via neuromodulating effects at the neuromuscular junction (NMJ). BTX-A functions by cleaving docking protein, synaptosomal-associated protein of 25 kDa (SNAP-25).<sup>4</sup> SNAP-25 cleavage prevents fusion of vesicles and acetylcholine release at the NMJ.<sup>4</sup> Effects of BTX-A are typically seen within 3 days of injection and can last up to 4 months before SNAP-25 regenerates and neuromuscular signaling is restored.<sup>4,7</sup> Thus, BTX-A treatment of wrinkles requires repeat sessions and regular interval injections. Adverse events following BTX-A are uncommon but may include injection-site reactions, allergic reactions, blepharoptosis, antibodies against BTX-A, eyebrow ptosis, facial asymmetry, distant spread from the injection site, or undesired facial results.<sup>4</sup>

Topical neuro-peptide serum (TNP-serum) is a wrinkle-modulating neuro-peptide serum for contraction lines, texture, and skin radiance. TNP-serum contains 5 key active ingredients: 2% acetyl hexapeptide-8, 2% dipeptide diaminobutyryl, 5% PHA, 5% niacinamide, and 1% laminaria extract that work via a synergistic action by stimulating 9 key skin biomarkers to reduce wrinkles and produce a skin-brightening effect. Studies have shown that neuropeptides such as hexapeptide-8 and dipeptide diaminobutyryl can effectively treat facial rhytids.<sup>7-10</sup> In

TPN-serum, the advanced peptide complex contains 2% acetyl hexapeptide-8 and 2% dipeptide diaminobutyryl, which function to reduce contraction lines.<sup>10</sup> Acetyl hexapeptide has homology with the N-terminus of SNAP-25 and dipeptide diaminobutyryl is an acetylcholine receptor antagonist.<sup>8-10</sup> Dipeptide diaminobutyryl binds to the acetylcholine receptor, blocking acetylcholine binding, further reducing muscle contraction.<sup>9</sup> PHA and niacinamide act to improve skin radiance and texture while contributing to line smoothing and enhanced penetration. The laminaria extract works to stimulate collagen and aid in long-term wrinkle correction. Together, these 5 active ingredients work in synergy to reduce contraction lines, refine skin texture, and tighten pores to enhance overall skin radiance.<sup>11</sup>

The synergistic active association of the TNP-serum has been proven via ex-vivo skin studies to significantly increase the expression of key components of the extracellular skin matrix associated with youthful skin appearance. Comparing the 5-ingredient formula to each of the ingredients alone, the formula demonstrated significantly higher expression of biomarkers such as collagen I (166% improvement) and collagen IV (229% improvement), suggesting synergistic action. TNP-serum-treated skin samples also resulted in significant upregulation of collagen III and elastin expression compared with compared skin samples. In 2 clinical trials in the United States and China, twice daily TNP-serum application to the full face in women aged 25 to 55 years demonstrated significant clinical improvement of 9 contraction wrinkles after 12 weeks of use. Contraction lines showed the most improvement after 12 weeks of TNP-serum application, and additional significant improvement included forehead wrinkles, glabellar frown lines, crow's feet, nasolabial folds, marionette lines, inter-ocular lines, cheek folds, and dynamic lines under the eyes (Figure 1). The TNP-serum effectively treats wrinkles and radiance or is integrated with BTX-A treatment of wrinkles to further optimize patient outcomes.

Herein, we highlight real-life experiences using an integrated skincare regimen consisting of BTX-A injections in conjunction with twice-daily daily TNP-serum in patients over the age of 30 years.

## METHODS

This is a real-world case series that aims to highlight the complementary use of a TNP-serum with BTX-A injection for synergistic wrinkle treatment and skin rejuvenation in patients over the age of 30 years. The cases demonstrate the use of the TNP-serum under real-world conditions by skin rejuvenation experts. Cases outline expert clinical reasoning and rationale for the combination of TNP-serum and BTX-A injections to optimize patient satisfaction and outcomes. These cases illustrate different ways to integrate the TNP-serum into clinical practice in a variety of patients with diverse FSTs. They also serve as a guide for future cosmetic dermatologists and surgeons to apply integrated skincare practices to enhance cosmesis and patient results.

## Steps in the Process

The real-world cases were compiled and selected in the following steps: 1) project definition and expert panel selection, 2) data collection and preparation of patient cases, 3) patient case discussion and selection for publication, 4) literature review to support selected cases, and 5) drafting, review, and finalization of the manuscript.

## Role of the Panel

The selected expert panel consisted of 5 dermatologists and 2 surgeons with expertise in cosmetic and skin rejuvenation procedures. Experts were chosen from various practice settings and geographical locations to capture diverse perspectives. Our panel represented experts from 6 different countries (Canada, Denmark, United States, Australia, China, and the United Kingdom). The experts were asked to share patient cases in which an integrated skincare regimen containing TNP-serum and BTX-A injections was used. In a meeting that took place on March 29<sup>th</sup>, 2024, in Cap d'Ail, France, each expert presented 2 cases of patients who were >30 years old who received BTX-A injections followed by twice daily use of TNP-serum. Treatment goals, challenges, and patient outcomes were discussed in each of the

**TABLE 1.**

Physician Assessment						
Site (eg, Glabella)						
Skin Smoothness	Skin Tone/Discoloration	Skin Texture	Fine Lines/Wrinkles	Radiance	Overall Appearance	Discomfort/Tolerability
Item: Skin smoothness: 0-4 (0=smooth appearance; 4=severe, rough appearance)	Item: Skin tone: 0-4 (0=even, healthy color; 4=uneven, discolored appearance)	Item: Skin texture: 0-4 (0=smooth, even feeling texture; 4=rough, uneven feeling texture)	Item: Fine Lines/Wrinkles: 0-4 (0= none, 4=diffuse)	Item: Radiance: 0-4 (0=dull skin appearance; 4=bright youthful skin appearance)	Item: GAIS: 1-5 (1=Very much improved; 5=Worse)	Item: Y/N? If Y, Explain
Score:	Score:	Score:	Score:	Score:	Score:	Score:

presented cases. Finally, 5 patient cases that panelists felt best demonstrated the integrated skincare regimen were selected for inclusion in this manuscript.

## Neuro-Peptide Serum

Patients were instructed to start the application of the TNP-serum on the same day as the neurotoxin injection. Patients were provided with TNP-serum (P-TIOX SkinCeuticals, NY, USA). Patients were instructed to apply the TNP-serum twice-daily full face, for 4 weeks starting the evening after the neuromodulator injection. Any deviation in this regimen is stated in the cases. The patients were instructed to refrain from using any other type of skincare except for broad-spectrum sunscreen and a gentle moisturizer.

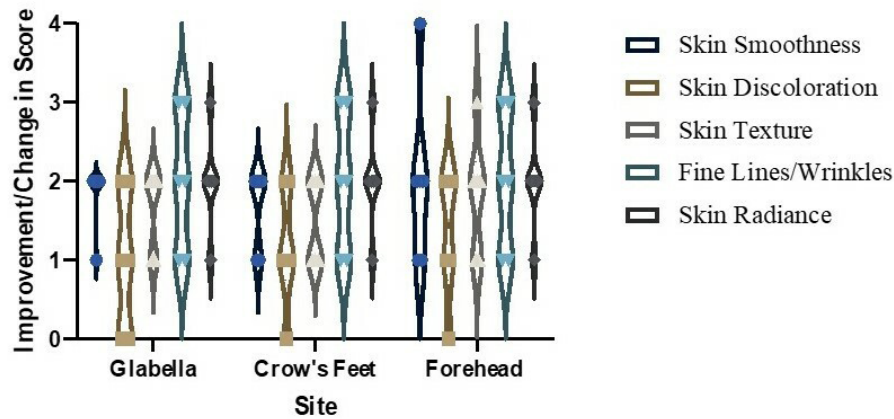
## Data Gathering and Outcome Measures

Suggested information to present included patient demographics, clinical features, cosmetic treatment goals, and qualitative and quantitative outcome measures. The panel used the same template to gather insight through a case-based approach, comprising cosmetic evaluation and alignment of treatment goals. Information on the neuromodulator (toxin) used, dilution used for the toxin, and the number of units injected into each muscle site was recorded. At baseline, physicians completed a baseline assessment that scored the glabella, crow's feet, and forehead on skin smoothness, skin tone/discoloration, skin texture, fine lines/wrinkles, and radiance, on a scale from 0 (none) to 4 (severe) (Table 1). Patients received

neuromodulator injections to sites determined by the physician and applied the TNP-serum all over the face. Post-injection, the overall appearance of each site was also rated using the Global Aesthetic Improvement Scale (GAIS) score at each of the follow-up visits. GAIS rates a subject's response to treatment as: very much improved (3), much improved (2), improved (1), no change (0), worse (-1), much worse (-2), and very much worse (-3). Any discomfort or intolerance was documented at each follow-up visit. Patients returned for follow-up visits at weeks 1, 2, and 4. At each follow-up visit, a physician assessment of injection sites was performed and subjects provided their feedback on the use of the TNP-serum in the form of a subject assessment (Table 2). In total, patient outcomes were tracked over 4 visits at day 0 (baseline), week 1 (+/- 3 days), week 2 (+/- 3 days), and week 4 (+/- 3 days). Special considerations and lessons learned were discussed at the end of the evaluation.

**TABLE 2.**

Subject Assessment	
Compared with your last visit, after X days of topical neuro-peptide serum use: <i>Complete the questions using the scale 1 (strongly disagree), 2 (disagree), 3 (neutral), 4 (agree), and 5 (strongly agree)</i>	Score
Overall, skin quality feels improved	
Skin looks healthier	
Skin looks younger	
Skin looks more supple	
Fine lines look reduced/minimized	
Wrinkles look reduced/minimized	
Skin looks brighter/more radiant/vibrant	
Skin tone looks more even	
Skin texture looks smoother/more refined	
Overall, I am satisfied with the test product	

**FIGURE 2.** Improvement/change in scores across physician assessment categories and skin sites at week 4.

The box-violin plot illustrates the positive change in 3 skin sites (glabella, crow's feet, and forehead) across 5 different skin categories. Data were collected from the 5 patients' cases, and the difference in score from baseline to week 4 of twice daily topical neuro-peptide serum (TNP-serum) use in each category was plotted. Case 6 was not plotted as this was a proof of concept case. The change is represented as intervals and plotted accordingly. The larger width of the box-violin represents a greater number of cases that had the same interval change.

## RESULTS

### Selected Real-World Patient Cases

Five cases were selected by the expert panel to illustrate TNP-serum use after neuromodulator injection under real-world conditions and one case (case 6) was a proof of concept case. Cases demonstrate the use of the TNP-serum in a diverse patient population with differing medical histories and treatment goals. The use of the TNP-serum in these patient cases shows how the serum may complement neuromodulators in patients over the age of 30. Data were collected from the 5 patients' cases, and the difference in score from baseline to week 4 of twice daily TNP-serum use in each category is shown in Figure 2. The information about the neuromodulator and TNP-serum regimen used for each of the 5 patients is shown in Table 3.

### Case 1. Use of Neuro-Peptide Serum in a Neuromodulator-Experienced Patient

A 69-year-old female with FST I presented with concern of a dull complexion and increasing fine wrinkles across her forehead, cheeks, and eyes. The patient had in the past received BTX-A injections to her upper face. At presentation, the patient was found to have rough skin texture on the skin overlying her forehead, glabella, and crow's feet, and received scores of 3, 4, and 4, respectively. She was also noted to have diffuse wrinkles with mild discoloration and minimal radiance.

At this time, the patient received Azzalure® (AbobotulinumtoxinA) injections to her corrugator, procerus, frontalis, and orbicularis oculi (Table 3). After injection, the patient was instructed to apply a thin layer of the TNP-serum across her entire face, twice daily.

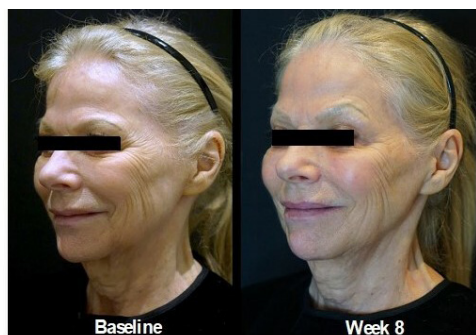TABLE 3.

Overview of Selected Patient Cases and Integrated Neuro-Peptide Serum and Neuromodulator Regimens						
Site (eg, Glabella)						
Case	Neuromodulator Used (Dilution), Areas Injected (Units)	Gender & Age, Fitzpatrick Skin Type	Topical Neuro-Peptide Serum	Tolerability	Outcome	Clinical Pearl
1	Neuromodulator: Azzalure® (1 mL in 125U) Sites Injected: Corrugator (25U) Procerus (12.5U) Frontalis (25U) Orbicularis Oculi (37.5U per side)	F69, Fitzpatrick 1  Concern of dull complexion and fine wrinkles.	After neuromodulator, the patient was instructed to apply TNP-serum twice daily all over the face	Slight facial redness after 1 week of use. Reported that product had a bit of "tackiness" upon application.	Improvement of fine wrinkles and skin texture within 7 days of serum use, post BTX-A. She felt that her skin had "extra luminosity" and strongly agreed that her condition has improved.	Improved outcome at 69 years possible with neuromodulator in combination with neuro-peptide serum. Dosage does not necessarily increase with severity of wrinkle scale or age.
2	Neuromodulator: Azzalure® (1 mL in 125U) Sites Injected: Corrugator (25U) Procerus (12.5U) Frontalis (25U) Orbicularis Oculi (37.5U per side)	F64, Fitzpatrick 1  <i>Concern of dynamic wrinkles and lack of skin radiance</i>	After neuromodulator, the patient was instructed to apply TNP-serum twice daily all over the face	Well-tolerated	At one month, the patient felt that his skin condition had strongly improved.	Improvement can be maintained at month 2 with neuro-peptide serum. Normal expression can be maintained throughout whilst reducing fine lines and wrinkles, radiance and improving symmetry.
3	Neuromodulator: Botox® Sites Injected: Glabella (16U) Forehead (10U) Crow's Feet (10U/side) Top/Bottom of Eye (2U/side)	F46, Fitzpatrick 3  <i>Concern of photoaging and fine lines/wrinkles</i>	After neuromodulator, the patient was instructed to apply TNP-serum twice daily all over the face	No adverse effects seen around eyes unlike patients experienced with BTX-A injections	Improvement in fine lines and wrinkles as early as day 7	Safe treatment for patients with previous complications with BTX-A
4	Neuromodulator: Botox® Sites Injected: Glabella (20U), Forehead (20U), Crow's Feet (20U)	F40, Fitzpatrick 4  <i>Concern of enlarged pores and dynamic fine wrinkles</i>	After neuromodulator, the patient was instructed to apply TNP-serum twice daily all over the face	Slight tingling sensation for the first 3 days, which gradually diminished. No symptoms of skin irritation, erythema or edema	Marked reduction in pore size by week 2	Neuro-peptide serum enhances the therapeutic effects of neuromodulators and offers additional benefits such as improving static wrinkles, skin texture, and brightness.  Patients' acceptance and satisfaction were remarkably high.
5	Neuromodulator: Dysport® (1.2mL saline per 300 U) Sites Injected: Glabella (60U) Crow's Feet (20U) Forehead (30U)	M43, Fitzpatrick 3  <i>Concern of sun-damaged skin, dyspigmentation</i>	After neuromodulator, the patient was instructed to apply TNP-serum twice daily all over the face	No adverse effects reported.	Early improvement in skin radiance and texture and strong patient satisfaction by day 7 of use	High patient acceptance of the TNP-serum formulation.  Improved satisfaction over neuromodulator alone.

Information about the neuromodulator and TNP-serum regimen used for each of the 5 patients.  
BTX-A, botulinum toxin type-A; TNP-serum, topical neuro-peptide serum.

The patient noticed slight facial redness after 1 week of serum use. She also reported that the product had a "tacky" or "sticky" feeling to it. Despite the texture, the patient continued the use of the TNP-serum and reported no other adverse effects. By week 1 of use, the patient was given a GAIS score of 3, very much improved. Skin smoothness scores decreased from 4 to 3 on her glabella and crow's feet and decreased from 3 to 2 across her forehead. The patient also agreed that her skin felt smoother and more radiant after only 1-week post-BTX-A injection and serum use. By week 4, the patient's fine wrinkle scores across her glabella, forehead, and crow's feet decreased from 4 to 2. The accordion smile lines had visibly decreased as well (Figure 3). The patient strongly agreed that the TNP-serum was satisfactory and felt that her skin complexion improved in shine and radiance. The patient continued to improve by week 8.

**FIGURE 3.** Case 1. Use of topical neuro-peptide serum regimen in a neuromodulator-experienced patient



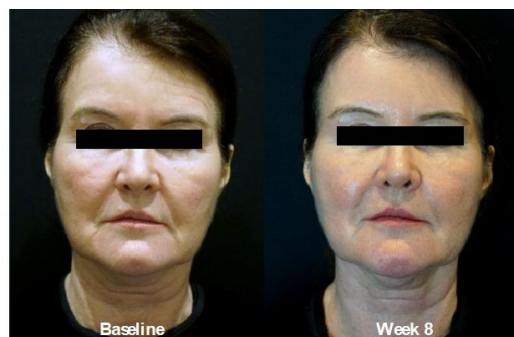This case demonstrates that the TNP-serum was effective in a neuromodulator-experienced, >65-year-old female, and did not require any dose adjustment. The patient saw significant improvement in fine wrinkles while maintaining normal smile expression and eyebrow raise. She was noted to have improved symmetry and saw enhanced results compared with her previous neuromodulator monotherapy use.

## Case 2. Maintenance Routine Using Neuro-Peptide Serum

The TNP-serum was used as a maintenance routine in a 64-year-old female with FST1 after BTX-A treatment for dynamic wrinkles. At the presentation, the patient was concerned with dynamic wrinkles across her forehead, chin, and nasolabial folds. She also reported that she felt her skin lacked radiance. At baseline, her physician assessment showed scores of 1, 1, 1 for radiance, 3, 4, 4, for skin smoothness, and 3, 3, 3 for fine lines and wrinkles for her glabella, crow's feet, and forehead, respectively.

She was injected with Azzalure® (AbobotulinumtoxinA) in her corrugator, procerus, frontalis, and orbicularis oculi while being started on complementary twice daily TNP-serum (Table 3). Two weeks post-BTX-A injection and serum use, the patient showed scores of 1, 2, 0 for skin smoothness, 2, 2, 3 for skin radiance, and 2, 2, 1 for fine wrinkles over the glabella, crow's feet, and forehead, respectively. The patient strongly agreed at this time that her skin had improved in radiance and vibrance over 2 weeks. By week 4, the patient had a GAIS score of 2 for her glabella and crow's feet and a score of 1, very much improved, over her forehead. The patient stopped the TNP-serum after 4 weeks of use; however, at her 8-week follow-up, the patient's skin maintained its smoothness and radiance (Figure 4). This case demonstrates that the use of neuromodulators with the neuro-peptide serum led to synergistic effects that lasted beyond the 4-week treatment period.

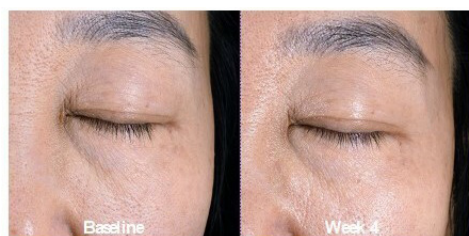**FIGURE 4.** Case 2. Maintenance routine using topical neuro-peptide serum regimen.



**Case 3. Previous Adverse Reaction to BTX-A**

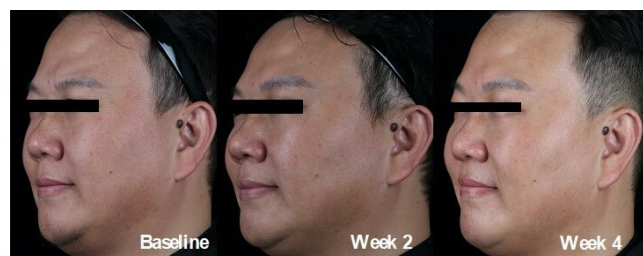A 46-year-old female with FST 3 presented with moderate facial photoaging and diffuse fine lines across her face. The patient had previously received regular BTX-A injections over the past 5 years. However, the patient started developing eyelid weakness post-injections, thereby necessitating smaller dosing of the neuromodulator every 3 to 4 months. At the same time, the patient was also concerned by enlarged pores across her central face and a slightly rough skin texture with prominent fine lines around her eyes, brows, and forehead. Baseline scores for skin texture, smoothness, and tone were 3 for the glabella, forehead, and crow's feet. Her score for fine lines/wrinkles was a 4 at baseline.

After her BTX-A session using OnabotulinumtoxinA, the patient was started on twice-daily TNP-serum to boost the effects of the smaller dose BTX-A injections. By day 7 of treatment, the patient had seen a 1-point improvement in her fine wrinkles and was given a GAIS score of 3. Three weeks later, the patient's GAIS score was 1, very much improved. At week 4, the patient had a score of 1 across all facial sites in all categories (Figure 5). The patient tolerated the treatment without any noticeable side effects. The patient loved the TNP-serum and found her skin texture smoother than at baseline and the lines around the eyes improved. The TNP-serum treatment proved to be a safe, alternative to high-dose BTX-A injections and served as an effective add-on therapy for a multi-pronged approach to fine wrinkles.

**FIGURE 5.** Case 3. Previous adverse reaction to botulinum toxin type-A.**Case 4. Reduction in Pore Size Using Neuro-Peptide Serum Regimen**

A 40-year-old male with FST 4 presented with the primary complaint of enlarged pore size. The patient also reported increased fine lines and wrinkles across his forehead. At presentation, the patient was noted to have a rough texture across his skin. His physician assessment at baseline showed a score of 4 for fine lines/wrinkles across all facial sites and a score of 3 for skin tone, texture, and radiance across all skin sites.

The patient received Botox Cosmetic® (OnabotulinumtoxinA) injections to the glabella, forehead, and crow's feet and was instructed to apply twice-daily TNP-serum across his face (Table 3). By week 2, the patient's forehead, glabella, and crow's feet region had scores of 1 for fine lines/wrinkles. This rapid reduction in wrinkles suggests that the TNP-serum may work synergistically with itself, the skin, and OnabotulinumtoxinA treatment to improve patient complexion and skin smoothness. Results were maintained through week 4. The subject assessment revealed that the patient was extremely happy with the product and felt that his skin looked brighter with fewer wrinkles. Importantly, there was also a noticeable reduction in pore size, offering a non-invasive topical solution for pore size reduction (Figure 6).

**FIGURE 6.** Case 4. Reduction in pore size using topical neuro-peptide serum regimen.

**Case 5. Neuro-Peptide Serum Use in Sun-Damaged Skin**

A 43-year-old (FST3) baseball player presented to the clinic with severely sun-damaged skin. The patient reported that he never used sunscreen when outside during practice and games. At baseline, the patient was found to have moderate discoloration across his face (scores 3 for all sites) with dull skin (radiance score of 1 for all sites), rough skin (skin smoothness score of 2 for all sites), and fine lines/wrinkles (score of 2, 3, 2 for glabella, crow's feet, and forehead, respectively).

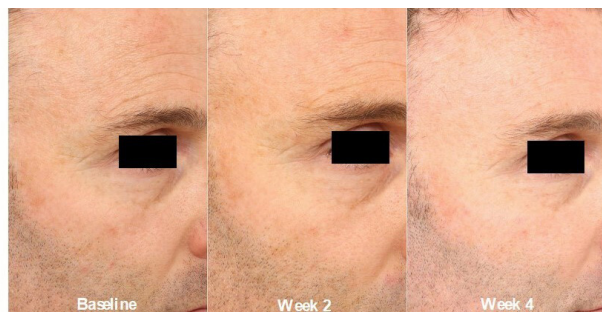
The patient received Dysport® (AbobotulinumtoxinA) to his glabella, crow's feet, and forehead (Table 3). The patient was instructed to start full-face application of the TNP-serum the evening after injection. After 7 days, the patient noticed the most visible change in skin smoothness and radiance and received a GAIS score of 2. By week 2, the patient continued to see improvement in skin smoothness (scores 0, 1, 1 for glabella, crow's feet, and forehead, respectively) and a 1-point improvement in skin discoloration across all sites. At week 4, the patient had a GAIS score of 1, radiance scores of 3 at all sites, and fine line wrinkle scores of 0 for the glabella, 1 for crow's feet, and 1 for the forehead. At the end of the treatment period, the patient was very satisfied with TNP-serum and felt that it had improved skin texture and tone while making his skin look younger and more vibrant (Figure 7). This case illustrates the significant improvement in photoaged, sun-damaged skin with the use of the neuro-peptide serum.

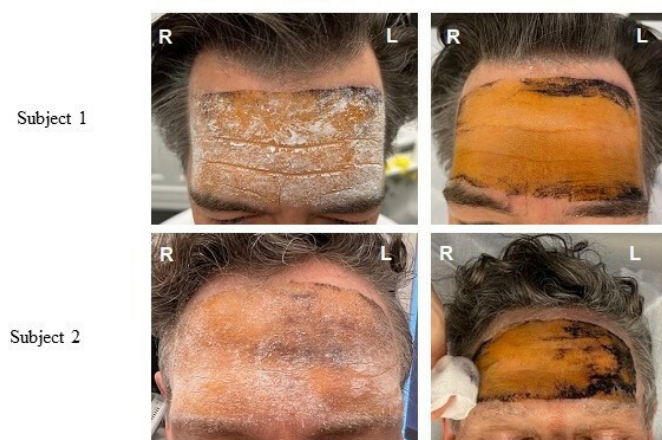**Case 6. Proof of Concept Using Minor's Starch Test**

Two males without any BTX-A treatment within the past year were included in a proof-of-concept test with TNP-serum, neuro-peptide serum. The serum is formulated to mimic the effect of mesotherapy where superficial BTX-A injections are used to deposit approximately 100 droplets of highly diluted BTX-A into the superficial lower aspect of the dermis. This is different from traditional BTX-A treatment where BTX-A is injected directly into the facial muscles; studies have shown BTX-A mesotherapy has improved skin texture and fine lines. Since sweat glands and voluntary muscles are innervated by acetylcholine between the distal nerve endings and the muscle/gland membrane, the effect of the neuro-peptide serum on sweat secretion was used as a proxy for the effect on muscle relaxation. Thus, the Minor's test was used to evaluate the neuromodulating effects of the TNP-serum on exercise-induced sweating of the skin and muscle activity.

The Minor's test, also known as the starch-iodine test, is used to evaluate hyperhidrosis. Iodine is applied to the skin and allowed to dry. Once dry, corn or potato starch is dusted across the dried iodine. At this point, the subject may be asked to exercise or enter a warm room to induce sweat production. If sweat is induced and reaches the skin surface, the starch and iodine react to form a dark blue-black color, which indicates normal neuromodulation of sweat production.

**FIGURE 7.** Case 5. Topical neuro-peptide serum use in sun-damaged skin.



**FIGURE 8.** Case 6. Proof of concept case.

The 2 male subjects included in the test received 3 applications of the TNP-serum to the right half of the forehead at 16 hours, 4 hours, and 2 hours before the Minor's test. The subjects were then asked to do burpee exercises to induce sweating. After exercise, the Minor's test was evaluated on the subject's forehead. In both males, the dark blue-black color was seen predominantly on the non-serum-treated side, the left side of the forehead (Figure 8). Thus, the neuro-peptide serum demonstrated a reduction of exercise-induced sweat gland activity after 3 applications with onset at 2 hours post-application TNP-serum continuing to 16 hours post-application. There was no visible effect on voluntary frontal muscle activity, possibly due to the deeper location of the muscle nerve endings compared with that of the sweat glands, or a dose and time-response differentiation of muscle vs sweat gland effect from this topical formulation. Effect on voluntary muscle relaxation may require a longer time, assuming similar action to BTX-A, which takes up to 7 days for effect.

## DISCUSSION

The TNP-serum demonstrates a novel combination of peptides that work in synergy to enhance the effects of neuromodulators. The real-world cases presented demonstrate that the TNP-serum may serve as a complementary skincare regimen to patients undergoing treatment for fine lines, wrinkles, and skin rejuvenation. In the field of cosmetic and rejuvenation medicine, few existing guidelines recommend best practices and post-procedure care to patients and providers. A few widely accepted but unproven recommendations for BTX-A aftercare include remaining upright for at least 4 hours and avoiding exercise or alcohol on the day of the treatment to prevent flushing and the undesired spread of toxin.<sup>2</sup> However, there are few to no options for patients seeking complementary skincare to enhance or maintain longer results from neuromodulator treatment.

Under real-world conditions, the neuro-peptide serum has been shown to provide a safe adjuvant therapy option to providers and patients for skin rejuvenation treatments. To date, BTX-A injections are the most common cosmetic procedure in the United States; however, it has only been FDA-approved for the treatment of moderate to severe forehead lines, glabellar frown lines, and crow's feet.<sup>13</sup> Consensus guidelines have been published to outline specific considerations and recommendations for treatment areas beyond FDA indication, and in experienced hands may result in successful outcomes.<sup>11</sup> In contrast, the TNP-serum provides a reliable, effective, and gentle alternative to support wrinkle-targeting treatments. The serum can be used topically on both the upper and lower portions of the face to enhance and maintain results from neuromodulator injections. The presented cases demonstrate that, over 4 weeks, there was an average 2-point improvement in skin smoothness, texture, discoloration, radiance, and fine lines/wrinkles across all skin types (Figure 2). The presented cases demonstrate TNP-serum safety with only 2 patients reporting either transient redness or tingling sensation after application.

The TNP-serum, neuro-peptide serum is comprised of 5 active ingredients: the advanced peptide complex of acetyl hexapeptide and dipeptide diaminobutyryl, which works in synergy with PHA, niacinamide, and laminaria extract to improve radiance.<sup>8,9</sup> The advanced peptide complex has 2 ingredients, the acetyl hexapeptide-8 homology with the N-terminus of SNAP-25 and dipeptide diaminobutyryl with antagonistic properties at the acetylcholine receptor without the potential systemic side effects associated with neuromodulators.<sup>8,9,14</sup> PHA and niacinamide work synergistically with the advanced peptide complex to smooth lines and produce a water-peel effect. Lastly, the laminaria extract helps to stimulate collagen and produce lifting and brightening effects on the skin.

Further, the real-world cases demonstrated that while the TNP-serum helped target wrinkles and skin radiance, it also helped improve redness and pore size. The redness is likely aided by the anti-inflammatory effects of niacinamide while pore size may be an added benefit of the advanced peptide complex by reducing sebum production.<sup>15,16</sup> This demonstrates that the synergistic effect of the TNP-serum, including the skin brightening ingredients such as PHA, niacinamide, and laminaria complex, provides an added effect for optimal patient outcome. As an adjunctive treatment, the TNP-serum may also be able to extend the interval of neuromodulator re-treatment.

One expert demonstrated the superficial efficacy of the TNP-serum using the Minor's test. The results of the test suggest that TNP-serum may have more immediate effects on sweat secretion prior to effecting muscle relaxation. The results of the TNP-serum application prior to administration of the Minor's test are similar to Minor's test results observed with BTX-A injections in the forehead to reduce stimuli-induced sweating. Future studies may also be able to identify a use for the neuro-peptide serum in the setting of hyperhidrosis, similar to BTX-A. Experts agree that, in the future, using greater qualitative and quantitative data analysis with diagnostic devices could greatly enhance our clinical research of integrated medicine and skincare regimens.

## Limitations

The cases presented represent treatment successes with neuro-peptide serum and neuromodulator injections; however, results are limited by a lack of controls. From our results, it is difficult to distinguish the effects of the TNP-serum from those of the neuromodulator injections. In the future, it will be important to conduct more studies on the isolated effects of the TNP-serum. Our results represent data from patients under real-world conditions and do not represent data from a controlled, clinical trial setting.

## CONCLUSION

The real-world cases demonstrate how the TNP-serum may be combined with neuromodulator injections to enhance skin rejuvenation results in an integrated skincare model. Experts' cumulative experience and insight suggest that the TNP-serum is a valuable complementary treatment in targeting wrinkles, fine lines, and skin radiance. The serum was seen to be effective in promoting skin rejuvenation in a wide range of patient ages, skin types, and clinical settings. Use of the TNP-serum after neuromodulator injections may provide a comprehensive, safe, and synergistic solution for improving overall skin appearance and health.

## DISCLOSURES

SW is an employee of SkinCeuticals International. All the other authors (ML, PB, AA, JC, SGF, SL, CM, QX, SW) have no conflict of interest with the manuscript's content. All authors contributed to the cases and development of the manuscript, reviewed it, and agreed with its content. All authors (ML, PB, AA, JC, SGF, SL, CM, QX, SW) disclose receipt of an unrestricted educational grant from SkinCeuticals International - L'Oréal Groupe for support with the research of this work; they also received consultancy fees for their work. The products used for the real-world cases were made available by SkinCeuticals in commercially available packaging.

**Author Contributions:** All authors (ML, PB, AA, JC, SGF, SL, CM, QX, SW) contributed to developing and conducting real-world cases, and reviewing and selecting the cases presented in this publication. All authors (ML, PB, AA, JC, SGF, SL, CM, QX, SW) contributed to developing the manuscript, reviewing this work, and agreeing with the content.

## REFERENCES

- World Health Organization. Ageing and Health. Available at <https://www.who.int/news-room/fact-sheets/detail/ageing-and-health>. Accessed May 14, 2024.
- Tobin DJ. Introduction to skin aging. *J Tissue Viab.* 2017;26(1):37-46.
- Leyden JJ. Clinical features of ageing skin. *B J Dermatol.* 1990;122:1-3.
- Small R. Botulinum toxin injection for facial wrinkles. *Am Family Physician.* 2014;90(3):168-175.
- Rona C, Vailati F, Berardesca E. The cosmetic treatment of wrinkles. *J Cosm Dermatol.* 2004;3(1):26-34.
- Manríquez JJ, Gringberg DM, Diaz CN. Wrinkles. *B Med J Clin Evid.* 2008;(12)2008:1711.
- Carruthers A, Carruthers J, Saunders JB. Botulinum toxin type A: history and current cosmetic use in the upper face. *Sem Cutan Med Surg.* 2001;20(2):71-84.
- Blanes-Mira C, Clemente J, Jodas G, et al. A synthetic hexapeptide (Argireline) with antiwrinkle activity. *Int J Cos Sci.* 2002;24(5):303-310.
- Kraeling ME, Zhou W, Wang P, Ogunsola OA. In vitro skin penetration of acetyl hexapeptide-8 from a cosmetic formulation. *Cutan Ocular Toxicol.* 2015;34(46-52).
- Lungu C, Considine E, Zahir S, et al. Pilot study of topical acetyl hexapeptide-8 in the treatment for blepharospasm in patients receiving botulinum toxin therapy. *Eur J Neurol.* 2013;20(3):515-518.
- Araco A, Francesco A. Prospective randomized clinical study of a new topical formulation for face wrinkle reduction and dermal regeneration. *J Cosmet Dermatol.* 2021;20(9):2832-2840.
- Klein AW. Contraindications and complications with the use of botulinum toxin. *Clinics Dermatol.* 2004;22(1):66-75.
- Carruthers J, Fagien S, Matarasso SL, et al. Consensus recommendations on the use of botulinum toxin type A in facial aesthetics. *Plast Reconstruct Surg.* 2004;114(6):1S-22S.
- Hurst JH, Scheller R, Südhof T. Receive the 2013 Albert Lasker Basic Medical Research Award. *J Clin Invest.* 2013;123(10):4095-4101.
- Ahmed El Attar Y, Nofal, A. Microbotox for the treatment of wide facial pores: a promising therapeutic approach. *J Cosm Dermatol.* 2021;20(5):1361-1366.
- Shi VY, Burney W, Shakhbazova A, et al. The effect of synthetic acetylhexapeptide-8 (AH8) on sebaceous function. *Int J Cosm Sci.* 2022;44(4):477-483.

## AUTHOR CORRESPONDENCE

**Anneke Andriessen PhD**

E-mail: ..... ti016762@telfort.nl



