

Cutaneous Photoaging: A Notable Pattern of Distribution of Lentigines on the Face

Farah A. Moustafa MD,^a Abrar A. Qureshi MD MPH,^b Jeffrey S. Dover MD FRCP^{a,c}

^aSkinCare Physicians, Chestnut Hill, MA

^bDepartment of Dermatology, Rhode Island Hospital, Brown Medical School, Providence, RI

^cDepartment of Dermatology Yale University School of Medicine, New Haven, CT

ABSTRACT

Importance: Facial lentigines are a common patient complaint encountered in general and cosmetic dermatology practices. Lentigines are a marker of photoaging and understanding their distribution will provide insight into the aging process in order to better counsel patients.

Objectives: To compare the relative distribution of lentigines in facial cosmetic subunits.

Methods: We reviewed clinical photographs of patients receiving Alexandrite laser treatment for facial lentigines during the time period 11/1/2017–12/1/2018. Individual lentigines were plotted for each patient into one of 21 aesthetic units. A “heat map” was created to compare the relative density of these lesions.

Results: Grouped peripheral cosmetic subunits contained more lentigines compared to grouped central cosmetic units. The mean number of lentigines in the central units was 0.60 and in the peripheral units was 0.85. This finding was statistically significant with a p value of 0.0001.

J Drugs Dermatol. 2020;19(7):755-757. doi:10.36849/JDD.2020.5193

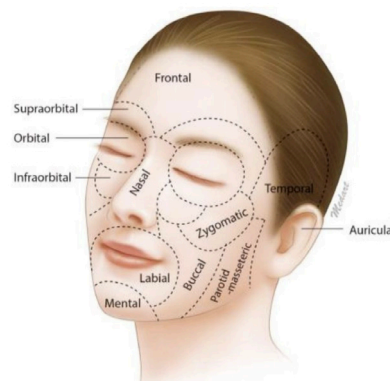
INTRODUCTION

Facial lentigines are a common patient complaint in dermatology practices. Lentigines are a marker of photoaging and understanding their distribution will provide insight into the aging process. The goal of our study was to determine the distribution of lentigines on the face and to determine if distribution of lentigines corresponds to published cutaneous UV damage and skin cancer distributions.

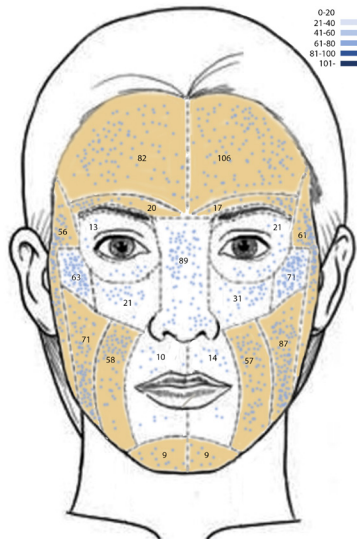
METHODS

We performed an IRB-approved retrospective chart review at SkinCare Physicians in Chestnut Hill, MA. Eligible patients were identified by screening the electronic health record (EHR) for patients who had procedure codes for short-pulsed Alexandrite during the time period of 11/1/2017–12/1/2018. Patients who were 25–80 years-old and received Alexandrite laser treatment for facial lentigines were included. Patients were excluded if they did not have a series of high-quality photographs of the entire face. Photographs were reviewed and each patient's lentigines were plotted on a diagram of the face divided into aesthetic units based on a modified Gonzalez-Ulloa distribution (previously used to perform studies evaluating skin cancer distribution¹) (Figure 1). There was a total of 21 aesthetic units.

FIGURE 1. Modified Gonzalez-Ulloa cosmetic facial subunits used to record facial lentigines from photograph review (*Used with permission*). *Auricular unit was not included in our evaluation as photos did not capture this site and the study focused on assessing lentigines on the face. **The nasal unit remained as a single unit given its central location on the face and difficulty in determining laterality for lentigines on the dorsum of nose. ***Modified to include laterality for a left-right comparison.



Arch Plast Surg. 2013 Jul; 40(4): 387–391.

FIGURE 2. Lentigines Distribution. Peripheral units are shaded yellow.

RESULTS

A total of 191 patients' charts were screened and 62 met the criteria. The patient cohort had a mean and median age of 57 with a range of 27–78. Of the 62 patients evaluated, there were 52 women and 7 men. Approximately 10% of the cohort had a prior history of a non-melanoma skin cancer. With respect to Fitzpatrick skin types, 3% were skin type I (n=2), 40% skin type II (n=25), 44% skin type III (n=27), and 13% skin type IV (n=8).

The number of facial lentigines in each of 21 units were recorded. A heat map schematic was created by manually plotting each individual lentigo into each of the aforementioned units. (Figure 2).

With regards to individual units, the frontal unit had the greatest number of lentigines with 106 on the left-side and 82 on the right-side (total 188 lentigines). This was followed by the

TABLE 1.

Average Lentigines Count by Facial Aesthetic Unit			
	Left	Right	Total
Supraorbital	0.27	0.32	0.59
Orbital	0.34	0.21	0.55
Temporal	0.98	0.9	1.88
Zygomatic	1.15	1.02	2.17
Infraorbital	0.5	0.34	0.84
Parotid-masseteric	1.4	1.15	2.55
Buccal	0.92	0.94	1.86
Labial	0.23	0.16	0.39
Mental	0.15	0.15	0.3
Frontal	1.71	1.32	3.03
Nasal	N/A	N/A	N/A
Total	7.65	6.51	14.16

parotid-masseteric unit with 87 on the left-side and 71 on the right-side (total 158 lentigines). The nasal unit had 89 lentigines. Other areas that were noted to have relatively high numbers of lentigines included the temporal, zygomatic, and buccal units (Table 1). The Wilcoxon rank-sum test was applied to assess for a difference in laterality and found the average number of facial lentigines was 7.7 for left facial units and 6.5 on right facial units, however, this was not statistically significant ($P=0.20$).

Finally, in order to compare the distribution of lentigines as central or peripheral, subunits were categorized as follows: central (nasal, labial, zygomatic, infraorbital, and orbital) and peripheral (frontal, supraorbital, temporal, parotid-masseteric, buccal, and mental). A Wilcoxon-rank sum test was performed to evaluate for a difference between lentigo distribution within the designated central and peripheral subunits. The mean number of lentigines in the central units was 0.60 and in the peripheral units was 0.85. This finding was statistically significant with a P value of 0.0001.

DISCUSSION

The comparisons were analyzed using a Wilcoxon rank-sum given the non-normal distribution of the collected data. Our findings were notable in several key ways. First, in this cohort of patients, lentigines were noted to be more prevalent in the grouped peripheral units than the grouped central facial units (0.85 vs 0.6; $P<0.0001$). Additionally, it is important to note that although the frontal subunits had the highest absolute number of lentigines, the density appears to be highest in the temporal, zygomatic, and parotid-masseteric units. This is explained by the high number of lentigines in these units, which have small surface areas (especially when compared to frontal subunit, which has the largest surface area). We hypothesize that the reason that lateral facial compartments have more lentigines than central ones is related to sun exposure and behavior. For the most part, unless trying to actively tan, one tends to look away and not directly at the sun. Thus, the lateral face gets more sun exposure than the central face and could explain the difference. Several studies have shown that the most common aesthetic units affected by skin cancer are the nasal, buccal, and temple units.^{1,2,3,4} In this subset of patients, there was a statistically significant difference in distribution of lentigines with more lentigines in the peripheral cosmetic units. This may be attributed to a number of reasons including differences in biology between lentigines and skin cancer, site-specific biology, and patient behavior. This information is helpful when counseling patients regarding sun protection and prevention of lentigines. Recently published data has shown the rates of skin cancer development on different parts of the face are not associated with the amount of sun exposure as some of the least exposed units (ie, under eyebrow, eyelids, nasolabial folds, and the medial/lateral canthus) had higher rates of skin cancer development than more exposed units (ie, forehead, chin, temple, jaw).²

The predilection for photoaging and skin cancer development to occur more frequently on the left side of the face has been the subject of several hypotheses, with one of the leading hypotheses linking drivers in right-hand-drive cars to greater sun exposure on the left side of the face. Our data did not show a statistically significant difference for lentigines on the left side of the face, which is a distribution pattern that has been previously observed with facial skin cancer distribution.⁵ This is likely due to the small sample size of the study.

Our study had several limitations. The distribution of the lentigines was plotted by the cosmetic unit, which may result in a loss of information as some subunits covered large surface areas. This was addressed by using a heat map that demonstrated the density in each unit by mapping each individual lentigo. Second, the results of this study were limited to a small population at a single practice in a Boston suburb. The geographic location may result in different sun exposures factors, both with respect to the environment and the patients. As a result, the findings may not be generalizable. Additionally, each lentigo recorded was plotted equally and we did not account for size or degree of pigment of each lentigo.

CONCLUSION

In this study, lentigines, a marker of photodamage, tended to be peripherally distributed in the cohort of patients. This data provides insight into how lentigines are distributed and can help when counseling patients on sun protective practices such as sun avoidance, paying particular attention to sunscreen application on the lateral part of the face, and wearing a broad-brimmed hat as opposed to shorter brims, or a baseball cap to get more lateral coverage of the face.

DISCLOSURES

The authors have no conflicts to report.

REFERENCES

1. Choi JH, Kim YJ, Kim H, Nam SH, Choi YW. Distribution of basal cell carcinoma and squamous cell carcinoma by facial esthetic unit. *Arch Plast Surg*. 2013;40(4):387–391. doi:10.5999/aps.2013.40.4.387
2. Subramaniam P, Olsen CM, Thompson BS, Whiteman DC, Neale RE, for the QSkin Sun and Health Study Investigators. Anatomical distributions of basal cell carcinoma and squamous cell carcinoma in a population-based study in Queensland, Australia. *JAMA Dermatol*. 2017;153(2):175–182. doi:10.1001/jamadermatol.2016.4070
3. Richmond-Sinclair, Naomi M, et al. Incidence of basal cell carcinoma multiplicity and detailed anatomic distribution: longitudinal study of an Australian population. *J Invest Dermatol*. 129(2):323–328
4. Kang KW, Lee DL, Shin HK, Jung GY, Lee JH, Jeon MS. A retrospective clinical view of basal cell carcinoma and squamous cell carcinoma in the head and neck region: A single institution's experience of 247 cases over 19 years. *Arch Craniofac Surg*. 2016;17(2):56–62. doi:10.7181/acfs.2016.17.2.56
5. Butler ST, Fosko SW. Increased prevalence of left-sided skin cancers. *J Am Acad Dermatol*. 63(6):1006–1010

AUTHOR CORRESPONDENCE

Farah A. Moustafa MD

E-mail:..... famousta010@gmail.com