

Efficacy of a Hand Regimen in Skin Barrier Protection in Individuals With Occupational Irritant Contact Dermatitis

Laura Jordan DO MS

Tri-County Dermatology, Cuyahoga Falls, OH

ABSTRACT

Background: Occupational irritant contact dermatitis (OICD) is a difficult and hard to manage condition. It occurs more frequently in certain occupations where contact with harsh chemicals, use of alcohol-based disinfectants, and frequent hand washing heightens the risk. Treatment for OICD includes patient education in addition to physical, topical, and systemic therapies.

Objective: To review the pathogenesis and treatment options for OICD and evaluate the efficacy of a selective skin-care regimen involving a hand protectant cream alone as well as combined with a repair cream and specific cleanser.

Materials and Methods: A single-center open study was performed comprising 42 healthy male and female adult volunteers prone to occupational irritant contact dermatitis due to frequent wet work or contact with detergents. Between day 0 and day 7, subjects applied a hand protectant cream as needed on both hands (at least twice daily). On days 7 to 14, subjects applied a hand protectant cream and cleanser as needed on both hands (at least twice daily) as well as a repair cream each evening. A diary log was given to each volunteer for application control and for a subjective evaluation of daily tolerability.

Results: In these subjects prone to occupational irritant contact dermatitis, the hand protectant cream applied during the initial 7-day period was effective in restoring the damaged skin barrier and improving the stratum corneum hydration.

A regimen that combined the hand protectant and repair creams with a specific cleanser during a further 7-day period allowed continued improvement of skin hydration and additional clinical benefits while respecting the skin barrier function.

Conclusion: The results of this study support the use of a 3-step approach for patients who are at risk of repeated exposure to external irritants.

J Drugs Dermatol. 2016;15(suppl 11):s81-85.

INTRODUCTION

Irritant contact dermatitis (ICD) is an inflammatory condition triggered by chemical stimuli on epidermal keratinocytes and skin barrier disruption, and both internal and external elements play a role in its pathogenesis.¹ The amount and period of time an individual is exposed to a trigger contributes to that individual's inflammatory response and type of ICD developed.² In acute ICD (AICD), an individual experiences dermatitis for less than 3 months which does not occur more than once per year.³ AICD typically occurs as a result of accidental skin damage by brief contact with a strong irritant.² On the other hand, chronic ICD (CICD) lasts for greater than 3 months with 2 or more episodes per year, usually arising after recurrent skin exposure to irritating elements, resulting in minor damage when compared to AICD. In CICD, the skin fails to repair completely between exposures, leading to this more chronic dermatitis, which is most common in wet work occupations such as healthcare and hairdressing.^{1,2,3}

Occupational ICD (OICD) is a form of ICD that occurs as a result of working conditions,⁴ and hand dermatitis is the most common form of OICD. Childhood dermatitis is a significant predictive factor in the development of hand OICD, and hand washing is its greatest risk factor. Women are affected twice

as often as men due to their increased exposure to water and other skin irritants. Hand dermatitis is accompanied by a considerable economic burden, poor long-term prognosis, and impaired quality of life. Locating and avoiding exposure to risk factors could lessen such consequences.⁵

Occupational skin diseases (OSD) are the second most common occupational diseases worldwide with OICD serving as the most frequent OSD, responsible for 77–95% of cases.¹ Globally, OICD affects 5 to 20 of 10,000 full-time workers per year.⁶ Eighty percent of OICD occurs in 7 distinct professional groups: hairdressing, healthcare, metalworking, food industry, painters/decorators, construction industry, and cleaning professions.⁷ Because OICD is not a life threatening disease, its potential impact on an individual's quality of life is frequently undervalued, and milder forms are often accepted as expected outcomes in certain occupations.^{4,6}

Pathogenesis

OICD is a form of ICD, occurring in people who regularly come into contact with irritants during their workday. Such irritants can include chemicals (eg, detergents, organic solvents, disinfectants, water), physical factors (eg, mechanical friction, cold or

dry environment), and mechanical factors (eg, pressure, friction, abrasion).^{2,6,8} Direct contact of the skin with an irritating factor can cause skin barrier disruption and a localized inflammatory reaction mediated by innate immunity, leading to OICD.^{2,8} Chemical irritants can disrupt the skin barrier by removing lipids or hampering their organization within the stratum corneum. These irritants can also invade the epidermis, interfering with proper extrusion of lipids and harming keratinocytes, which subsequently respond with the release of pro-inflammatory cytokines such as IL-1 α , IL-1 β , TNF- α , GM-CSF, and IL-8.¹

Upon recurrent exposure of mild irritants to an impaired skin barrier, reactivation of atopic dermatitis can occur, further worsening skin integrity.^{1,6} Frequent exposure to water is a prevailing cause of skin barrier impairment, as indicated by increased transepidermal water loss (TEWL), a marker for barrier function, in such individuals.⁹ Consequently, skin barrier impairment is the key step in OICD pathogenesis and is the hallmark of atopic skin.¹ Endogenous elements have also been found as risk factors for development of OICD such as the genetic mutation of the filaggrin gene (FLG) and history of atopic dermatitis during childhood.^{2,6}

Treatment options

Treatment options for OICD include education as well as physical, topical, and systemic therapies. Patient education on the avoidance and substitution of irritating elements is recommended in addition to precautions from future outbreaks. Topical therapy options include emollients, corticosteroids, and calcineurin inhibitors while systemic treatments include acitretin, alitretinoin, azathioprine, cyclosporine, corticosteroids, and methotrexate. Patients also have the option for physical treatments such as UVB and PUVA.³

Prescribed medications may add to long-term health problems. For example, although topical corticosteroids can prove efficacious in the short term, continuous use beyond 6 weeks is not recommended as they can inhibit stratum corneum repair and induce skin atrophy, thus undermining long-term therapy success. Additionally, while systemic corticosteroids can improve symptoms in an acute reaction, they are not appropriate for use in chronic hand ICD due to their association with long-term side effects including osteoporosis, osteonecrosis, and immunosuppression. Similarly, long-term use of methotrexate is also associated with potential side effects including hepatitis, liver cirrhosis, and pulmonary fibrosis. Cyclosporine use requires careful monitoring and can also be linked with adverse effects such as nephrotoxicity, hypertension, and increased risk of infection. Of note, it is recommended that if the patient does not respond to cyclosporine therapy within 8 weeks, the medication should be discontinued.³

Non-pharmacologic treatment is ideal in the treatment of OICD with an emphasis on preventing occurrences.⁶ For example,

patients should avoid high-risk occupations and causative exogenous factors when possible as well as wear protective gloves and clothing.^{1,3,6} For both primary and secondary prevention of OICD, skin care regimens including barrier creams, moisturizers, and cleansers, are encouraged.^{1,3,6,11,12} The combined benefit of skin care and wearing gloves is widely recommended as the most important method for protection against OICD.^{3,6} Skin protection education and training are an important part of secondary prevention.^{1,3}

Formulation of skin care products should be carefully selected in the treatment of OICD. Products should be hydrating so that they may accelerate regeneration of the skin barrier and prevent recurrence of OICD.^{7,8} They should be individualized to the patient in order to match their skin status, and products that are heavily stressful to the skin should be avoided. Application of these products is recommended after work and after cleansing.⁷ Emollients in particular play a principal role in OICD treatment as they serve to normalize the abnormal epidermal barrier, and those with higher lipid content further hasten the healing process.^{1,3} Further, regular use of barrier-strengthening skin moisturizers protects against irritants and prevents relapse.¹³

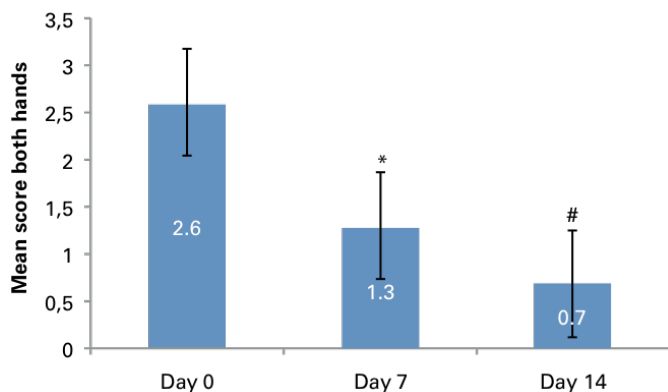
Glycerol is an ingredient widely used for its moisturizing and smoothing effects in different dermatological and cosmetic preparations. It penetrates the epidermis, delivering a moisturizing effect, depending on its concentration (commonly 5–10%). This humectant property hydrates the skin, especially the stratum corneum, aids in cutaneous elasticity, maintains and improves barrier function via reduction in TEWL, accelerates wound healing, and provides both antimicrobial and anti-irritant effects.¹⁴ In a 2008 study, Breternitz et al. evaluated the application of glycerol-based emollient on 24 patients with mild to moderate atopic dermatitis (AD). Patients were treated for 4 weeks twice daily with a glycerol-based (20%) cream. The study found that stratum corneum hydration was significantly higher after glycerol-based application versus placebo at all time points, even remaining higher during washout, indicating a sustainable effect in AD.¹⁵

Paraffinum liquidum has also been applied to numerous topical applications, acting as both an emollient and an occlusive. A complex mixture of highly refined saturated hydrocarbons, this ingredient traps water in the SC, reducing TEWL and improving distensibility of the skin.^{16,17,18} Further, skin softness is increased after use, more so than with wax esters, triglycerides, or fatty acids. It has a limited penetration into the skin and is mainly confined into the epidermal layers and thus considered safe for cosmetic application.¹⁶

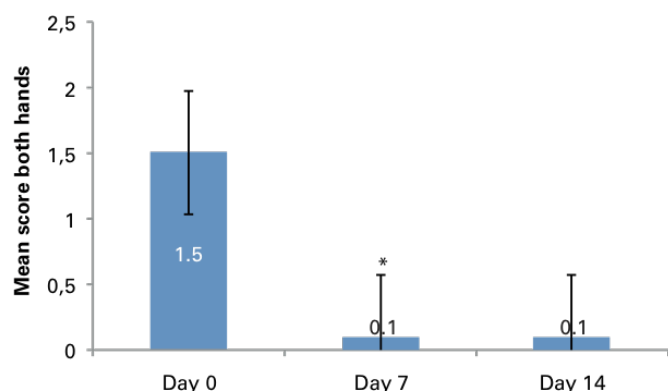
Aluminum chlorohydrate is a commonly utilized aluminum compound found in cosmetic products, acting as an astringent, buffering agent, and antiperspirant. It coordinates is

FIGURE 1. Clinical scoring of (A) dryness and (B) itching on a 5-point scale from 0 (none) to 4 (severe) after 7 days. Protect cream followed by 7 days Protect, Cleanser, and Repair cream.

(A)



(B)



*p<0.05 for change from baseline; #p<0.05 for change from Day 7 to Day 14

bioaccessible for skin absorption, the FDA considers aluminum chlorohydrate use in topical products to be suitable for use and permitted in concentrations up to 25%.^{19,20}

Limnanthes alba seed oil (also known as Meadowfoam seed oil) serves as a non-occlusive emollient which moisturizes the skin. It is rich in long-chain monounsaturated fatty acids and antioxidants. The long-chain fatty acids in this oil are akin to sebum, thus promoting their rapid absorption into the skin.²¹

Niacinamide has also been applied to cosmetic formulations. In vivo it has displayed anti-inflammatory, antipruritic, and antimicrobial properties.²² Further, it reduces TEWL, improving barrier function. It has demonstrated anti-inflammatory effects in AD, psoriasis, rosacea, and acne vulgaris with topical formulations considered suitable for use in concentrations up to 5%.^{22,23} In a 2005 study, Soma et al. investigated the topical application of nicotinamide 2% in 28 patients with atopic dermatitis and found a gradual time-dependent reduction in skin TEWL with a significant reduction between 0 and 8 weeks after treatment

($P<0.05$). A significant increase in stratum corneum hydration was evident in the nicotinamide group after 4 weeks ($P<0.01$) and after 8 weeks ($P<0.01$).²⁴

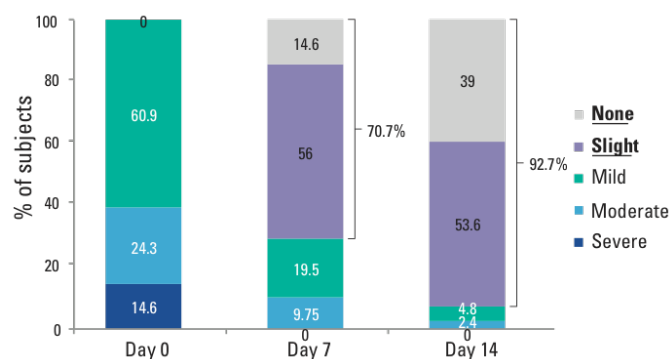
MATERIALS AND METHODS

The ideal approach to managing OICD is a skin-care regimen that works to normalize the abnormal epidermal barrier and prevent relapse. To evaluate this treatment model, a clinical study was conducted from October through November 2015 as a single-center open study, comprising 42 male and female adult subjects with a history of occupational irritant contact dermatitis due to frequent exposure to water and detergents.

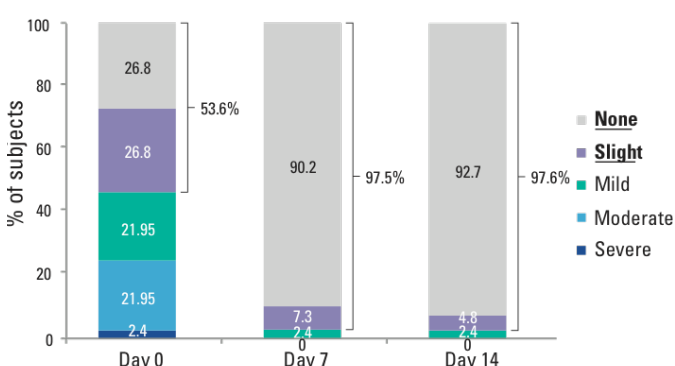
During Phase 1 of the study (between day 0 and day 7), subjects applied a hand protectant cream containing paraffinum liquidum as an emollient, aluminum chlorohydrate as an astringent, and glycerin as a humectant at least twice daily and more often if needed. The goal of this application was to create a protective barrier, decrease epidermal permeability, preserve hydration, and repair skin integrity. The role of the 5% aluminum chlorohydrate was to help prevent excess moisture accumulation under glove occlusion by plugging eccrine gland secretions and minimizing the extent to which irritants could penetrate the skin.

FIGURE 2. Subject assessment of (A) dryness and (B) itching (left hand) after 7 days Protect cream followed by 7 days Protect, Cleanser, and Repair cream.

(A)



(B)



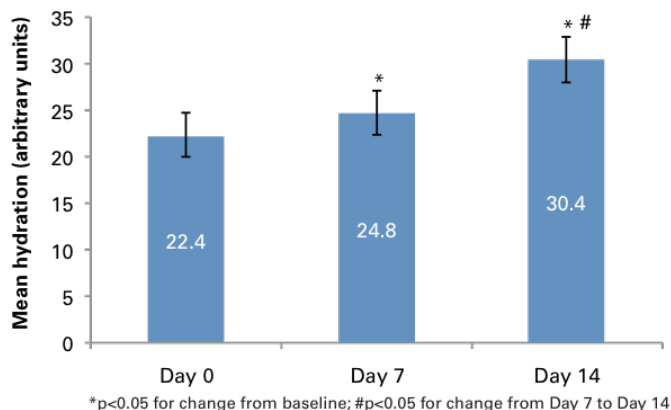
© 2016-Journal of Drugs in Dermatology. All Rights Reserved.

This document contains proprietary information, images and marks of Journal of Drugs in Dermatology (JDD).

No reproduction or use of any portion of the contents of these materials may be made without the express written consent of JDD.

If you feel you have obtained this copy illegally, please contact JDD immediately at support@jddonline.com

FIGURE 3. Mean hydration score as assessed by corneometer (arbitrary units) after 7 days Protect cream followed by 7 days Protect, Cleanser, and Repair cream.



During Phase 2 of the study (between day 7 and day 14), all subjects applied the hand protectant cream and specific cleanser as often as needed (at least twice daily) and applied a repair cream nightly. The repair cream, designed for post-exposure use, was an oil-in-water cream formulated with skin conditioners and 29% lipids. It contained niacinamide (vitamin B₃), panthenol (pro-vitamin B₅), and tocopherol (vitamin E), ingredients which have displayed the ability to stabilize and improve epidermal barrier integrity by supporting the synthesis of barrier lipids, improving hydration, and enhancing anti-oxidative capacity, respectively. The purpose of this lipid composition was to act as an emollient, repairing skin barrier damage that occurs after exposure to common irritants.

Assessments were based on skin roughness, dryness, softness, discomfort, desquamation, fissure, erythema, burning, itching, edema and overall irritation. Each item was assessed

on a 5-point scale (0=none, 1=slight, 2=mild, 3=moderate, 4=severe). Subjects in the study were also given a self-assessment questionnaire that allowed them to evaluate daily tolerability subjectively.

Corneometer and transepidermal water loss were included as biophysical measurements of hydration. Imaging via high-resolution UVA-light video camera and confocal microscopy were also utilized to assess treatment efficacy. Adverse events were collected during the study period, and tolerability was recorded in a subject diary.

RESULTS

Results from the clinical scoring illustrated a significant improvement ($P<0.05$) in skin roughness, dryness, softness, discomfort, desquamation, fissure, burning, and itching. Erythema and overall irritation decreased without reaching a statistical significance, and edema remained unchanged.

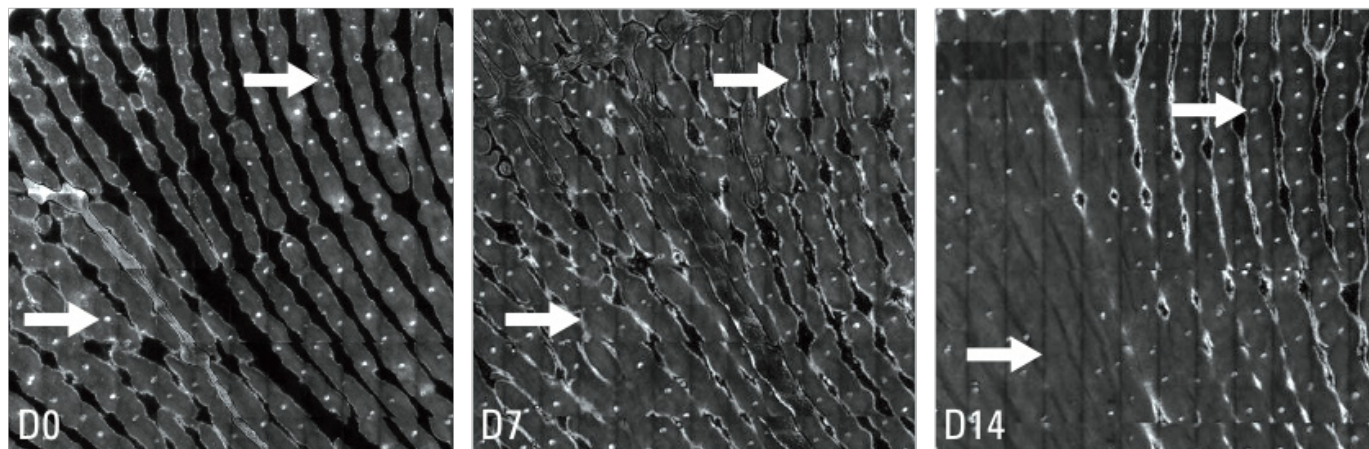
A marked improvement was observed by day 7 in roughness, dryness, softness, and skin discomfort, which continued to significantly improve ($P<0.05$) up to day 14. The mean dryness score decreased by 50% by day 7 from 2.6 to 1.3 (7 days use of the hand protectant cream) and further continued to decrease to 0.7 by day 14 (7 days with the hand protectant cream, specific cleanser, and repair cream; Figure 1a).

The mean itching severity score significantly decreased during the first week, and the effect was sustained up to day 14 (Figure 1b).

Subject Assessment

In those subjects prone to occupational irritant contact dermatitis, all had mild, moderate, or severe dryness on day 0 before application. After 7 days applying the hand protectant cream,

FIGURE 4. Confocal microscopy showing a visible decrease of the intensity of pores filled by the protect cream. D=day



© 2016-Journal of Drugs in Dermatology. All Rights Reserved.

This document contains proprietary information, images and marks of Journal of Drugs in Dermatology (JDD).

No reproduction or use of any portion of the contents of these materials may be made without the express written consent of JDD.

If you feel you have obtained this copy illegally, please contact JDD immediately at support@jddonline.com

70.6% of the subjects reported having none or only slight dryness (Figure 2a).

The proportion of subjects reporting having none or only slight itching was 97.5% on day 7 and 97.6% on day 14 (Figure 2b).

Skin hydration

Transepidermal water loss decreased by 5% on day 7 ($P=0.012$) and then remained stable, demonstrating that the cream respected the skin barrier function. Hydration had increased by 18.9% between baseline and day 7 ($P=0.0142$) and continued to improve by 30.7% from day 7 to day 14 ($P=0.0199$), giving an overall difference from baseline to day 14 of 55.4% ($P<0.05$; Figure 3).

To further illustrate the improvements, confocal microscopy was performed on the palmar side of the hand. Images showed a decrease in the visibility of the sweat ducts on day 7 and day 14 and an enhanced hydration aspect (Figure 4).

Safety

All products were well tolerated with only 2 of the 41 subjects included in the safety population experiencing related adverse events (1 tingling sensation after the first application and 1 burning sensation after the first application).

DISCUSSION

Occupational contact dermatitis is the most frequent cause of occupational skin diseases with its subtypes comprising irritant contact dermatitis and allergic contact dermatitis.¹ Occupational irritant contact dermatitis most frequently occurs in individuals coming into regular contact with irritants during their workday.^{2,6,8} Direct contact of an irritant with the skin can disrupt the skin barrier, causing a local inflammatory reaction mediated by innate immune system components and lead to OICD.^{2,8} Diagnosis of OICD rests upon a multi-faceted approach and exclusion of other skin diseases as no specific diagnostic test currently exists.¹ OICD can have a significant negative impact on an individual's quality of life which is often discounted.^{4,6} A variety of treatment options exist for OICD. However, emphasis on a preventative hand regimen is highly recommended as skin care products can help repair the skin barrier and prevent recurrence of OICD.^{7,8} Emollients in particular are important for OICD prevention and repair as they are able to normalize the disrupted epidermal barrier.¹

CONCLUSION

In these subjects prone to occupational irritant contact dermatitis, the hand protectant cream when applied alone during the initial 7-day period was effective in restoring the damaged skin barrier and improving the stratum corneum hydration. A regimen that combined the hand protectant cream, repair cream, and a specific cleanser during a further 7-day period allowed continued improvement of skin hydration and additional clinical benefits while respecting the skin barrier function. The result

of this study supports the use of a 3-step approach for patients who are at risk of repeated exposure to external irritants.

DISCLOSURES

Dr. Jordan received an honorarium for contributing to this publication sponsored by Galderma.

REFERENCES

1. Kasemsarn P, Bosco J, Nixon RL. The role of the skin barrier in occupational skin diseases. *Curr Probl Dermatol*. 2016; 49:135-143.
2. Kezic S, Visser MJ. Irritant contact dermatitis. In: Thyssen JP, Maibach HI, eds. *Filaggrin*. Berlin: Springer. 2014:259-262.
3. Diepgen TL, Andersen KE, Chosidow O, et al. Guidelines for diagnosis, prevention, and treatment of hand eczema: a short version. *J Dtsch Dermatol Ges*. 2015; 13(1):77-85.
4. Lau MY, Burgess JA, Nixon R, et al. A review of the impact of occupational contact dermatitis on quality of life. *J Allergy*. 2011; 96:4509.
5. Johannisson A, Pontén, Svensson A. Prevalence, incidence, and predictive factors for hand eczema in young adults: a follow-up study. *BMC Dermatol*. 2013;13:14.
6. Bauer A, Schmitt J, Bennett C, et al. Interventions for preventing occupational irritant hand dermatitis (review). *Cochrane Database Syst Rev*. 2010; 6:CD004414.
7. Fartasch M, Diepgen TL, Drexler H, et al. S1 guideline on occupational skin products: protective creams, skin cleansers, skin care products (ICD 10: L23, L24): a short version. *J Dtsch Dermatol Ges*. 2015; 13(6):594-606.
8. Brasch J, Becker D, Aberer W, et al. Contact dermatitis. *J Dtsch Dermatol Ges*. 2007; 5(10):943-951.
9. Fartasch M. Wet work and barrier function. *Curr Probl Dermatol*. 2016;49:144-151.
10. Usatine RP, Riojas M. Diagnosis and management of contact dermatitis. *Am Fam Physician*. 2010; 82(3):249-255.
11. Bock M, Wulffhorst B, Gabard B, et al. Occlusion effect of protective gloves: efficacy of a skin protection cream containing aluminum chlorohydrate. *Occup Environ Dermatol*. 2011; 49:85-87.
12. Mostosi C, Simonart T. Effectiveness of barrier creams against irritant contact dermatitis. *Dermatology*. 2016; 232(3):353-362.
13. Lodén M, Wirén K, Smerud KT, et al. Treatment with a barrier-strengthening moisturizer prevents relapse of hand eczema: an open, randomized, protective, parallel group study. *Acta Derm Venereol*. 2010; 90:602-606.
14. Fluhr JW, Darlenski R, Surber C. Glycerol and the skin: holistic approach to its origin and functions. *Br J Dermatol*. 2008;159:23-34.
15. Breternitz M, Kowazki D, Langenauer M, et al. Placebo-controlled, double-blind, randomized, prospective study of a glycerol-based emollient on eczematous skin in atopic dermatitis: biophysical and clinical evaluation. *Skin Pharmacol Physiol*. 2008; 21(1):39-45.
16. Rawlings AV, et al. *Int J Cosmet Sci* 2012; 34(6):511-518.
17. Patzelt A, et al. *Skin Res Technol* 2012; 18(3):364-369.
18. Overgaard Olsen L, et al. *Acta Derm Venereol* 1993; 73(6):404-406.
19. Scientific Committee on Consumer Safety (2014). Opinion on the Safety of Aluminium in Cosmetic Products. Available at: http://ec.europa.eu/health/scientific_committees/consumer_safety/docs/scsccs_o_153.pdf. Date accessed: April 2016.
20. Strassburger J, et al. *J Soc Cosmet Chem* 1987; 38:109-124.
21. Rigano L, et al. (2012). Polyfunctional Vehicles by the Use of Vegetable Oils. In: Lodén, M & Maibach, HI (Eds.) *Treatment of Dry Skin Syndrome: The Art and Science of Moisturizers*. Berlin: Springer. pp 419-429.
22. Wohlrab J, et al. *Skin Pharmacol Physiol* 2014; 27:311-315.
23. Elsner P, et al. *JDDG* 2011; 9(Suppl 3):S1-S32.
24. Soma Y, et al. *Int J Dermatol* 2005; 44(3):197-202.

AUTHOR CORRESPONDENCE

Laura Jordan DO MS

E-mail:..... dr.laura.jordan@gmail.com