

A Case of Erythema Elevatum Diutinum With Pancytopenia: Focus on Dapsone-Induced Hematologic Side Effects and Colchicine as a Safe Treatment Option

Emek Kocatürk MD, Bachar Memet MD,
İlteris Oguz Topal MD, Tülin Yüksel MD,
Pelin Kuteyla Ülkümen MD, Utkan Kızıltaç MD

Emek Kocatürk Okmeydanı Training and Research Hospital Department of Dermatology, Istanbul, Turkey

Erythema elevatum diutinum (EED) is a disease characterized by red to yellow cutaneous papules, nodules, and plaques distributed mainly over extensor surfaces. Histologically, there is leukocytoclastic vasculitis with fibrinoid necrosis of the upper and mid dermal vessel walls. The etiology of EED is not well understood, but it is thought to be secondary to immune complex deposition in dermal vessels, resulting in complement fixation and subsequent inflammation. The treatment of choice for EED is dapsone. A review of the literature reveals many other reported treatment options, including sulfapyridine, chloroquine, colchicine, tetracycline, niacinamide, and topical, intralesional, and systemic glucocorticoids. Here we report a case of EED presenting with pancytopenia after prolonged dapsone use and responded well to colchicine.

Erythema elevatum diutinum (EED) was first described in 1888 by Hutchinson¹ and in 1889 by Bury.² However, the name erythema elevatum diutinum was first used by Radcliff-Crocker and Williams,³ who found similarities between the cases of Hutchinson and Bury and their own. No clinical examination difference is apparent between the Hutchinson type and the Bury type of erythema elevatum diutinum. Acute lesions may appear bullous, necrotic or hemorrhagic. Early histologic changes are characterized by leukocytoclastic vasculitis.

CASE

A 70-year-old woman presented with a 10-year history of asymptomatic papules and plaques evolving into numerous 0.5 cm to 2.0 cm sized nodules over the interphalangeal joints, elbows, ankles, and feet (Figure 1). Skin biopsy from the nodule on the elbow revealed dermal fibrosis, dense dermal infiltrate composed of lymphocytes, and neutrophils. Leukocytoclastic vasculitis (LCV) with areas of fibrinoid necrosis and neutrophils infiltrating the vessel walls were also seen (Figure 2). Laboratory investigations revealed pancytopenia with a leukocyte count

of 3.76×10^3 /L, platelet count of 92×10^3 /L and hemoglobin level of 9.3g/dL. Results of a peripheral blood smear examination showed anisocytosis and macrocytosis of erythrocytes. Liver function tests were abnormal with a direct bilirubin of 1.6 mg/dl, indirect bilirubin of 2.0 mg/dl, aspartate aminotransferase of 66 U/l, alanine aminotransferase of 38 U/l, alkaline phosphatase of 182 U/l, serum albumin of 2.3 g/dl, and prothrombin time of 12 seconds. Viral hepatitis serology (IgM antibody to hepatitis A antigen, hepatitis B surface antigen, and hepatitis C antibody) were negative. The levels for urea, creatinine, uric acid, and electrolytes were within normal limits.

It was understood from the history that she has been diagnosed with EED 5 years ago and has been using dapsone without any medical control. The patient was consulted with hematology due to pancytopenia. Methemoglobin levels were normal. Abdominal USG revealed a splenomegaly. PET scan revealed enlargement of spleen with calcified foci and increased FDG uptake. After bone marrow biopsy which was in normal ranges, the hematologist stated that the hematological picture was not induced by dapsone. However, because of pancytopenia, we preferred colchicine as the treatment of choice instead of dapsone in this patient.

Dapsone was ceased and colchicine with a dose of 0.5 mg twice daily was started. The lesions improved gradually and near complete resolution was seen after 6 months of colchicine therapy (Figure 3).

DISCUSSION

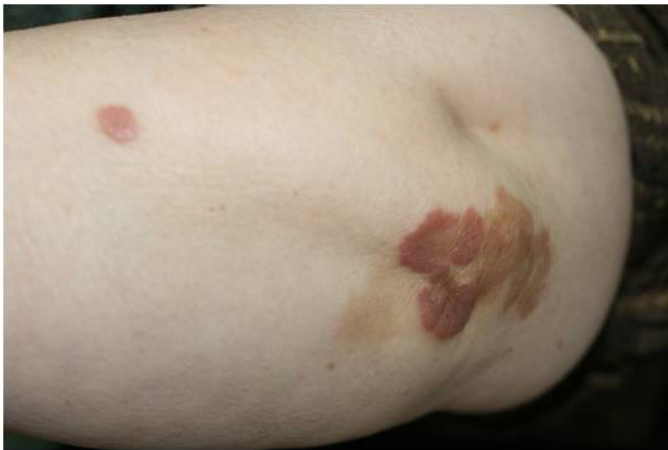Erythema elevatum diutinum (EED) is a rare chronic cutaneous vasculitis. The disease can occur at any age, but is seen more frequently in middle-aged to older individuals with roughly equal distribution between the sexes and with no specific racial predilection.⁴

EED, a chronic inflammatory dermatosis characterized by brownish red, elevated lesions occurring symmetrically over extensor surfaces of the interphalangeal joints, elbows, ankles, and knees. Constitutional symptoms of fever and arthralgia may be seen, but systemic involvement is rare. It is frequently found with hematologic disorders, such as immunoglobulin A monoclonal gammopathy, myelodysplasia, myeloproliferative disorders, paraproteinemia, and hairy cell leukemia. Infections from group B streptococci, HIV, syphilis, and viral hepatitis are commonly associated with the disease. Autoimmune disorders, such as celiac disease, Crohn disease, systemic lupus erythematosus, and rheumatoid arthritis have also been associated with EED.⁵

The exact pathogenesis of EED remains elusive. However, EED is related to viral infections (especially among patients with HIV), bacterial infections, rheumatic diseases, and hematologic diseases. Immunoglobulin A monoclonal gammopathy was also reported to be correlated with EED.⁶

Further to the above, the exact pathogenesis of the disease may play an

FIGURE 1. Asymptomatic papules and plaques evolving into numerous 0.5 cm to 2.0 cm sized nodules over the elbow.



important role in the pathogenesis of EED.⁷ Deposition of immune complexes on the vessels can trigger the chain immunologic reaction to damage the vessels.⁸

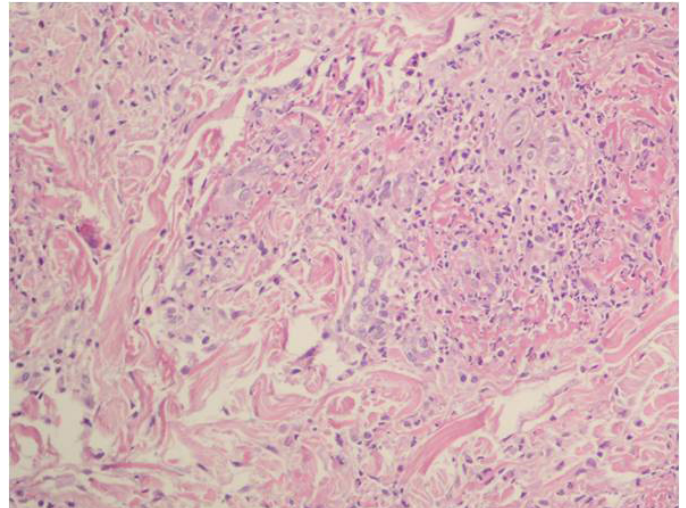
The clinical differential diagnoses include Sweet's syndrome, pyoderma gangrenosum, granuloma faciale, fixed drug reaction, erythema multiforme, lichen planus, porphyria cutanea tarda, fibrous histiocytoma or dermatofibroma, bacillary angiomatosis, Kaposi's sarcoma, xanthoma, and necrobiotic xanthogranuloma.⁶

“The exact pathogenesis of EED remains elusive.”

The histopathologic findings in EED vary depending upon the stage of the lesion. Early stage lesions show features of an acute leukocytoclastic vasculitis. This typically entails neutrophil permeation of vessels walls, fibrin thrombosis, and erythrocyte extravasation. A dermal mixed infiltrate of neutrophils, histiocytes, lymphocytes, and occasionally eosinophils accompanies the vasculitis. In its later stages, EED transitions to a fibrotic dermis. Still at this stage, occasional areas of neutrophilic vasculitis can be seen, while other vessels often show hyaline thickening. Extracellular lipid may be seen in the later stages, but cholesterol deposits are rare.⁵

The treatment of choice for EED is dapsone. To minimize the risk of life-threatening hemolytic anemia associated with dapsone, glucose-6-phosphate dehydrogenase deficiency should be screened before beginning therapy. A review of the literature reveals many other reported treatment options, including sulfapyridine, chloroquine, colchicine, tetracycline, niacinamide, and topical, intralesional, and systemic glucocorticoids. EED is a chronic condition with frequent recurrences after cessation of therapy.⁵⁻⁹ Dapsone 100 mg daily remains the initial treatment of choice. The response may be partial and dose dependent. Dapsone may induce a dose-related neutropenic

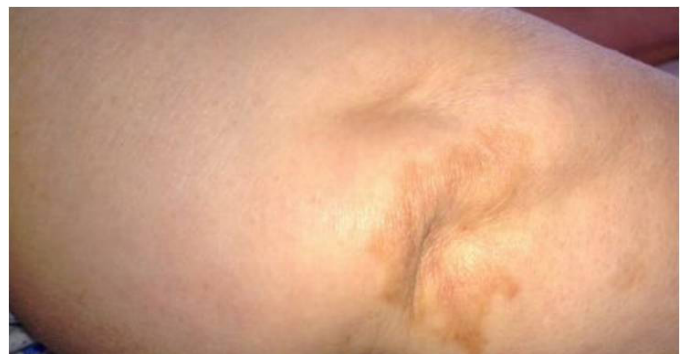FIGURE 2. Dermal fibrosis and dense dermal infiltrate composed of lymphocytes, and neutrophils. Leukocytoclastic vasculitis (LCV) with areas of fibrinoid necrosis and neutrophils infiltrating the vessel walls (H&EX100).



anemia, which is more likely with doses greater than 200 mg/day or in patients with glucose-6-phosphate dehydrogenase (G-6-PD) deficiency. Hematologic side effects include methemoglobinemia, aplastic anemia, leukopenia, agranulocytosis, eosinophilia, macrocytic anemia, and Heinz bodies. Leukopenia, megaloblastic pancytopenia, and hemolysis have been reported. At least one case of pure red cell aplasia has also been reported, in addition to a case of exanthema with desquamation of the trunk and extremities. Agranulocytosis usually occurs during the first few months of therapy and has been fatal. In one case report, filgrastim (G-CSF) was used to control the agranulocytosis.¹⁰ Linda Milkova et al informed asymptomatic dapsone-induced agranulocytosis in a patient with chronic spontaneous urticaria.¹¹

Aplastic anemia due to dapsone has been reported occasionally. The onset of aplastic anemia has ranged from 2 to 12 weeks following initiation of therapy and has been fatal. A 75-year-old male with granuloma annulare experienced pure

FIGURE 3. Gradual improvement of papules and plaques after the treatment with colchicine therapy.



red cell aplasia (PRCA) coincident with dapsone therapy. He was given dapsone 100 mg per day. Four weeks after the start of this therapy, the patient presented with asthenia. A diagnosis of PRCA was made based off of hematological counts. Dapsone was discontinued, and the patient received blood transfusions until his condition improved considerably. Hematological counts gradually returned to normal levels.¹²

Corticosteroids have also been effective in patients with EED. Topical betamethasone and topical fluocinolone acetonide have been used under occlusion with good effect. In other patients both intralesional and systemic corticosteroids (prednisolone 30–40 mg daily) have produced favorable responses.⁹

Sulfonamides (sulfamethoxypyridazine 500 mg once daily and sulfapyridine 0.5–1 g three times daily), nicotinamide 100 mg three times daily, colchicine 0.5 mg twice daily with 0.5 mg three times daily for 3 to 4 days to abate minor disease flares, and chloroquine 300 mg daily have produced resolution of lesions.⁹

Treatment of EED is difficult because this disorder follows a chronic and recurrent course.¹³ Recurrence rate of EED is still high if the underlying triggering factors are not under control. In our case, the patient treated with colchicine 0.5 mg twice daily. Significant improvement was observed in 6 months. Although it is ultimately the first option, it can not be used in patients with hematological problems, colchicine should be considered as a good and safe option in those patients.

Disclosure

The authors have no conflict of interest to declare.

References

1. Hutchinson J. On two remarkable cases of symmetrical purple congestion of the skin in patches, with induration. *Br J Dermatol* 1880;1:10.
2. Bury JS. A case of erythema with remarkable nodular thickening and induration of the skin associated with intermittent albuminuria. *Illus Med News* 1889;3:145.
3. Radcliffe-Crocker H, Williams C. Erythema elevatum diutinum. *Br J Dermatol* 1894;6:1-9.
4. Tomasini C, Seia Z, Dapavo P, Soro E, Addese C, Pippione M. Infantile erythema elevatum diutinum: report of a vesico-bullous case. *Eur J Dermatol* 2006; 16(6):683–6.
5. Khan F, Chan CS, LeLeux TM, Diwan AH, Hsu S. JAAD Grand Rounds quiz. Adult with red-brown nodules and plaques. *J Am Acad Dermatol* 2011 Aug; 65(2):469-71.
6. Gibson LE, el-Azhary RA. Erythema elevatum diutinum. *Clin Dermatol* 2000;18:655–659.
7. Tomasini C, Seia Z, Dapavo P, Soro E, Addese C, Pippione M. Infantile erythema elevatum diutinum: report of a vesiculo-bullous case. *Eur J Dermatol* 2006;16:683–686.
8. Wahl CE, Bouldin MB, Gibson LE. Erythema elevatum diutinum: clinical, histopathologic, and immunohistochemical characteristics of six patients. *Am J Dermatopathol* 2005;27:397–400.
9. Pamela Fiandero, Emma Benton, Ian Coulson In Treatment of Skin Disease: Comprehensive Therapeutic Strategies. Mark G. Lebwohl, Warren R. Heymann, John Berth-Jones, and Ian Coulson. Elsevier Limited, Fourth Edition, China, 2014, 223-225.
10. McConkey B. Adverse reactions to dapsone. *Lancet* 1981;2:525.
11. Milkova L, Hallermann C, Simon JC, Treudler R. Asymptomatic dapsone-induced agranulocytosis in a patient with chronic spontaneous urticaria. *J Dtsch Dermatol Ges* 2014 Aug;12(8):717-9.
12. Borrás-Blasco J, Conesa-García V, Navarro-Ruiz A, Devesa P, Matarredona J, Marin-Jiménez R. Pure red cell aplasia associated with dapsone therapy

(June). *Ann Pharmacother* 2005;39:1137-8.

13. Michaels J, Scottsdale, AZ, DiCaudo D, Yiannias J. Erythema elevatum diutinum in a 32-year-old pregnant woman. *J Am Acad Dermatol* 2013;68(4):suppl:50.

AUTHOR CORRESPONDENCE

Emek Kocatürk MD

E-mail:..... emekozgur@yahoo.com