

The Alexiades Filler Lift Method

Macrene Alexiades MD PhD

Yale University School of Medicine, New Haven, CT
Dermatology and Laser Surgery Center, New York, NY
Dr. Macrene Skin Results 37 Actives, New York, NY



Macrene Alexiades MD PhD

In this article, I present my unique method of injecting dermal fillers in the hairline to create a lifting effect that is concealed from view and does not distort the patient's natural appearance. As a portrait artist and sculptor with an expertise in the natural human face, my objective as an injector has been to reverse the laxity and accordion effects of age due to osteoporosis, loss of subcutaneous support tissues, and loss of elasticity without changing the natural

contours and appearance of my subject. My method entails placing hyaluronic acid dermal fillers in the scalp and hairline so as to provide a lifting effect without the product being

in any way apparent on the face. Akin to surgical facelifting, I place the filler in the areas where a surgeon would routinely cut and sew to obtain a lift to the lower, mid-face, and upper face, including the posterior and pre-auricular areas, and the temporal and frontal scalp. Instead of incising and excising skin, I employ the tension caused by the deposition of filler to create the lift in vectors depicted to achieve the lift required to elevate jowels, nasolabial folds, periorbital folds, and the brow (see Figure). In placing the hyaluronic acid fillers intradermally, my method has achieved long-term improvements beyond the duration of the filler, likely due to the neocollagenesis that has been observed with intradermal placement of hyaluronic acid fillers. To date, I have treated over one thousand cases, and have not observed any incidence of hair loss or occlusion due to intradermal placement.

References

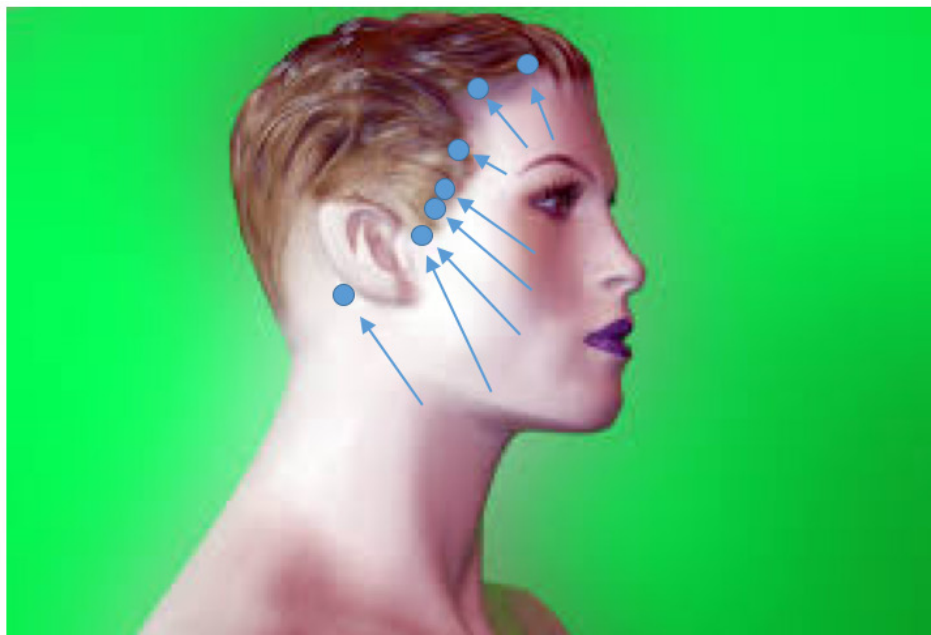
1. Carruthers, J. D., Carruthers, J. A., Humphrey, S. Fillers and neocollagenesis. *Derm Surg.* 2014; 40:S134-S136.
2. Ho, D and Jadeo J. Biological properties of a new volumizing hyaluronic acid filler: a systematic review. *J Drugs Dermatol.* 2015; 14(1):5.

AUTHOR CORRESPONDENCE

Macrene Alexiades MD PhD

E-mail:..... dralexiades@nyderm.org

FIGURE 1. Alexiades Filler Lift Method. Dermal filler is injected intradermally into concealed hair-bearing areas to effectuate a lift in areas typically incised and/or excised in a surgical facelift: into lateral aspects of face in the hairline preauricularly to lift the jawline; post-auricularly to lift the submandibular skin; temporally in the scalp to lift the nasolabial folds, cheeks, and periorbital skin; and in the frontal scalp to create a brow lift effect. The duration of the lifting effect is of long duration and may result in long-lasting effects due to neocollagenesis and a rejuvenative effect induced by intradermal placement. No hair loss has been observed with this technique. No occlusion of blood vessels has been observed as filler is intradermally placed.



Key: ● = filler aliquot
↗ = direction of lift