

The Effects of a Daily Skincare Regimen on Maintaining the Benefits Obtained from Previous Chemical Resurfacing Treatments

Suzanne Bruce MD,^a Wendy Roberts MD,^b Craig Teller MD,^c and Lora Colvan BS^d

^aSuzanne Bruce and Associates, Houston, TX

^bRancho Mirage Dermatology, Rancho Mirage, CA

^cBellaire Dermatology Associates, Bellaire, TX

^dMDRejuvena, Inc., San Diego, CA

ABSTRACT

Background: Chemical peels are versatile treatments that involve chemical exfoliation of the skin for cosmetic improvement. Deeper peels produce more significant results, but can be associated with longer healing time and potential complications. Novel chemical resurfacing treatments (AGE and MELA) were developed in Europe to produce skin resurfacing via controlled inflammation to promote cell regeneration with minimum negative effects associated with conventional peelings. The AGE Resurfacing regimen is indicated for the treatment of photoaging, and consists of multi-ingredient peeling solution with trichloroacetic acid, pyruvic acid, salicylic acid, mandelic acid, and lactobionic acid. The MELA Resurfacing regimen addresses hyperpigmentation concerns and contains mandelic acid, potassium azeloyl diglycinate, retinol, salicylic acid, phytic acid, lactobionic acid, and lactic acid. Results of previously conducted US clinical experience trial of AGE and MELA resurfacing protocols rated 81% of subjects with some level of improvement according to physician assessment.

Objectives: To evaluate whether a daily skin care regimen used for 12 weeks could maintain the benefits achieved with AGE and MELA chemical resurfacing treatments.

Methods: Subjects who completed participation in the AGE and MELA skin resurfacing clinical trial were recruited to participate in a continuation trial and used a daily regimen of MDRejuvena facial products for 12 weeks. No other facial products were permitted. Physicians assessed the severity of individual skin parameters at baseline and week 12 and provided global assessment. Subjects assessed improvement of individual skin parameters at week 12 and provided an overall assessment.

Results: Thirteen subjects participated in the 12-week continuation trial. According to the physician's global assessment, all subjects demonstrated some level of improvement at week 12 compared to baseline. Physician assessment showed a decrease in severity of all skin parameters assessed at week 12 compared to baseline. According to the subject overall assessment at week 12, 11 of 12 subjects noted some level of improvement, 1 subject saw no improvement, and 1 subject did not provide an overall assessment. Mild to moderate improvement was observed by subjects in all individual skin parameters assessed except for skin discoloration.

Conclusions: The results of the continuation study demonstrate that use of a daily skin care regimen, which include combination of 2 various strengths of MDRejuvena Rejuvaphyl® Rejuvenating Complex: low strength (LS) and high strength (HS), not only maintains but can enhance the beneficial effects of skin resurfacing treatments for at least 12 weeks.

J Drugs Dermatol. 2016;15(9):1145-1150.

INTRODUCTION

Chemical peeling is a procedure used for cosmetic improvement of skin in which a chemical exfoliating agent is applied to destruct portions of epidermis and/or dermis with subsequent regeneration and rejuvenation of the tissues. These treatments provide reliably reproducible results in a wide variety of patients with a good cost-benefit ratio. Chemical peels are divided into 3 categories depending upon the depth of the wound created by the peel.¹ For superficial peels alpha-hydroxy-acids and most recently lipo-hydroxy acid are used to induce an exfoliation of the epidermis; medium-depth agents such as trichloroacetic acid (<50%) cause an epidermal

to papillary dermal peel and regeneration; deep peels using trichloroacetic acid (>50%) or phenol based formulations reach the reticular dermis to induce dermal regeneration.² Deeper peels produce more significant results, but are associated with longer healing times and the potential for complications.^{3,4}

The skin resurfacing products and protocols (from Laboratorio pHformula Internacional SL, Barcelona, Spain) were developed as a dermatological skin resurfacing system to address specific skin conditions such as aging, hyperpigmentation, acne, and chronic redness. The systems are based on the concept of

creating skin resurfacing via controlled inflammation. Unlike conventional skin peelings which may cause extensive skin exfoliation, controlled skin resurfacing actively promotes an accelerated form of cell regeneration in the different layers of the skin using low concentrations of multiple acids, thereby reducing trauma and superficial irritation. This action is achieved through the mechanism of a unique bio-availability delivery complex (PH-DVC™) that promotes maximum controlled delivery of actives with minimal negative effects normally seen with conventional peelings. These resurfacing systems have been available in Europe for several years, and MDRejuvena, Inc. (San Diego, CA) is now developing the products for use in North America.

The resurfacing treatment systems provide customized treatment options based on the patient's individual skin tolerability level and include products to treat various skin conditions. Two of the treatments that have been tested in a US clinical experience trial are AGE and MELA. Each of these treatments provides a progressive application system with three levels (strengths) of resurfacing.

- AGE (*trichloroacetic acid, pyruvic acid, salicylic acid, mandelic acid and lactobionic acid*) indicated for the treatment of typical signs of aging like photoaging, pigment changes, lentigines, telangiectasia, dull sallow appearance, keratosis, unhealthy stratum corneum, and fine lines and wrinkles.
- MELA (*mandelic acid, potassium azeloyl diglycinate, retinol, salicylic acid, phytic acid, lactobionic acid and lactic acid*) indicated for improvement of hyperpigmentation spots in all skin types, including mottled pigmentation, melasma, UV induced hyperpigmentation, superficial melanin disorders, post inflammatory hyperpigmentation, solar lentigines, and freckles.

A US clinical experience trial enrolled 20 subjects in AGE and 20 subjects in MELA resurfacing protocols. No additional products were permitted. Results of investigator assessment of global improvement rated 81% of subjects with some level of improvement (11% marked, 27% moderate, 43% mild; n=37 subjects). Subject self-assessment ratings were 63% much improved, 20% improved, and 17% no change (n=30 subjects). The procedures were tolerated with no or mild discomfort by 73% of subjects (n=36 subjects).

Subjects who completed participation in the US clinical experience trial and received 3 chemical resurfacing treatments (AGE or MELA) were invited to participate in a continuation trial in which they used a daily regimen of MDRejuvena products for 12 weeks to assess whether the benefits achieved with the chemical resurfacing treatments could be maintained. MDRejuvena products feature Phytochromatic MD® Complex, which is included in the Rejuvaphyl® line of topical products. The active component of Phytochromatic MD® Complex is liposomal sodium copper chlorophyllin complex. This complex has been shown in clinical

TABLE 1.

Subjects Demographics and Corresponded Treatments			
Subject #	Age	Fitzpatrick Skin Type	Resurfacing Treatment
1	53	II	MELA
2	64	III	AGE
3	47	III	MELA
4	63	II	AGE
5	50	II	AGE
6	54	II	MELA
7	48	IV	AGE
8	65	III	MELA
9	65	I	AGE
10	46	III	MELA
11	65	IV	AGE
12	59	II	AGE
13	49	III	AGE

studies to have multiple activities including anti-aging, anti-inflammatory and antioxidant actions, and has demonstrated improvement in skin condition in women with photodamaged facial skin.⁵ In addition, studies have demonstrated Phytochromatic MD® Complex to have potent inhibitory effects on hyaluronidase which helps maintain structural integrity in the skin.⁶

METHODS

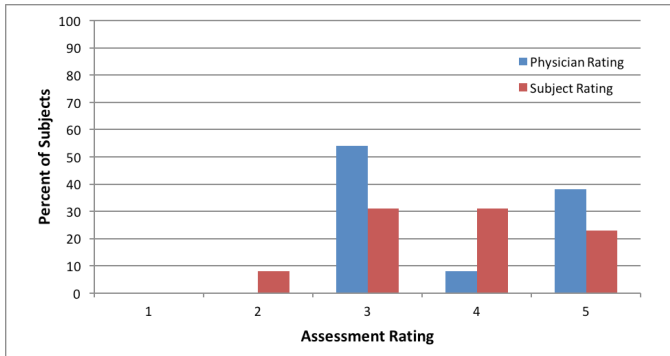
Subjects

Subjects who completed participation in a US experience trial of chemical resurfacing treatments (AGE or MELA) were invited to participate in a continuation study to evaluate the effectiveness of MDRejuvena product regimen to maintain the benefits achieved with the facial skin resurfacing treatments. Subjects provided written informed consent prior to receiving the treatments. Efficacy was evaluated by clinical assessments and digital photographs. Subjects also completed a self-assessment questionnaire.

Treatments

Subjects used the following MDRejuvena facial products for 12 weeks:

- AM Sunscreen SPF 30
- AM/PM Daily Cleanser
- AM/PM Daily Balancing Toner
- AM/PM Rejuvaphyl Rejuvenating Complex LS (1st 6 weeks)
Rejuvaphyl Rejuvenating Complex HS (2nd 6 weeks unless they are unable to tolerate in which case they will continue with LS for the remaining 6 weeks)
- AM Daily Hydration
- PM Rejuvaphyl Ultra-Rich Hydration

FIGURE 1. Assessment ratings at week 12.

Assessment Rating Scale: 1 = Worse; 2 = No Improvement; 3 = Mild Improvement; 4 = Moderate Improvement; 5 = Marked Improvement

Assessments

Assessments were performed at baseline and week 12 by physician and included rating the severity of the following parameters. A 5-point scale was employed for these assessments (1 = mild, 3 = moderate, 5 = severe).

- Fine Lines
- Coarse Wrinkles
- Skin Roughness
- Brown Spots
- Skin Discoloration

Global Assessment Rating (week 12 only)

The subject week 12 self-assessment included the following parameters. A 5-point scale was used for these assessments (1 = worse, 2 = no improvement, 3 = mild improvement, 4 = moderate improvement, and 5 = marked improvement).

- Fine Lines
- Coarse Wrinkles
- Skin Roughness
- Brown Spots
- Skin Discoloration

Overall Assessment Rating (week 12 only)

For the Global and Overall Assessment ratings at week 12, both the physician and subjects used the following scale:

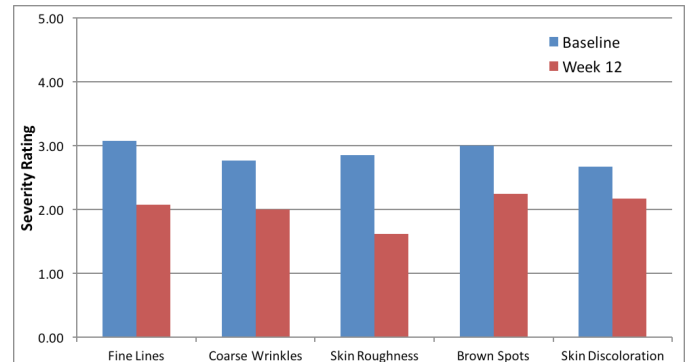
Rating	Assessment
1	Worse
2	No improvement
3	Mild improvement
4	Moderate improvement
5	Marked improvement

© 2016-Journal of Drugs in Dermatology. All Rights Reserved.

This document contains proprietary information, images and marks of Journal of Drugs in Dermatology (JDD).

No reproduction or use of any portion of the contents of these materials may be made without the express written consent of JDD.

If you feel you have obtained this copy illegally, please contact JDD immediately at support@jddonline.com

FIGURE 2. Physician assessment of severity of parameters at baseline and week 12.

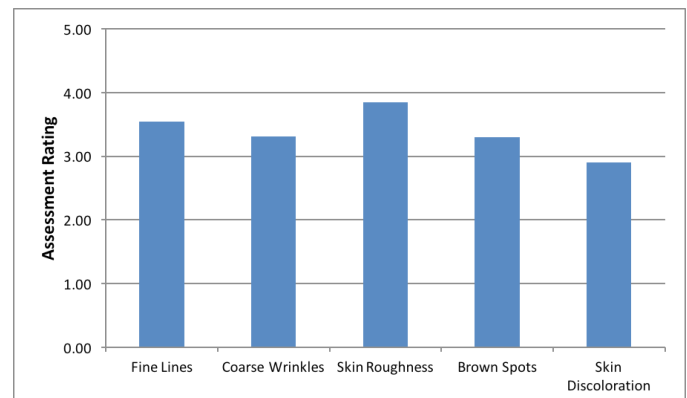
Severity Ratings: 1 = Mild; 3 = Moderate; 5 = Severe

RESULTS

Thirteen subjects who completed the skin resurfacing trial participated in the 12-week continuation trial. See Table 1 for demographics. The subjects ranged in age from 46 to 65 years, and included Fitzpatrick skin types I-IV. Eight of the subjects had undergone the AGE resurfacing treatment, and five had undergone the MELA resurfacing treatment in the skin resurfacing protocol. All subjects used the MDRejuvena continuation skin care regimen for 12 weeks as directed.

Results of the physician and subject assessments at week 12 are shown in Figure 1. According to the physician's global assessment at week 12, 7 subjects (54%) showed mild improvement, 1 subject (8%) showed moderate improvement and 5 subjects (38%) showed marked improvement.

According to the subject overall assessment at week 12, 1 subject (8%) saw no improvement, 4 subjects (31%) saw mild improvement, 4 subjects (31%) saw moderate improvement, and 3 subjects (23%) saw marked improvement; 1 subject (7%) did not provide an overall assessment.

FIGURE 3. Subject assessment of improvement of parameters at week 12.

Assessment Rating Scale: 1 = Worse; 2 = No Improvement; 3 = Mild Improvement; 4 = Moderate Improvement; 5 = Marked Improvement

FIGURE 4. 48-year-old Caucasian female, Fitzpatrick skin type II, at baseline (A) and after 12 weeks on MDRejuvena regimen (B). Results: Marked improvement in overall hyperpigmentation.

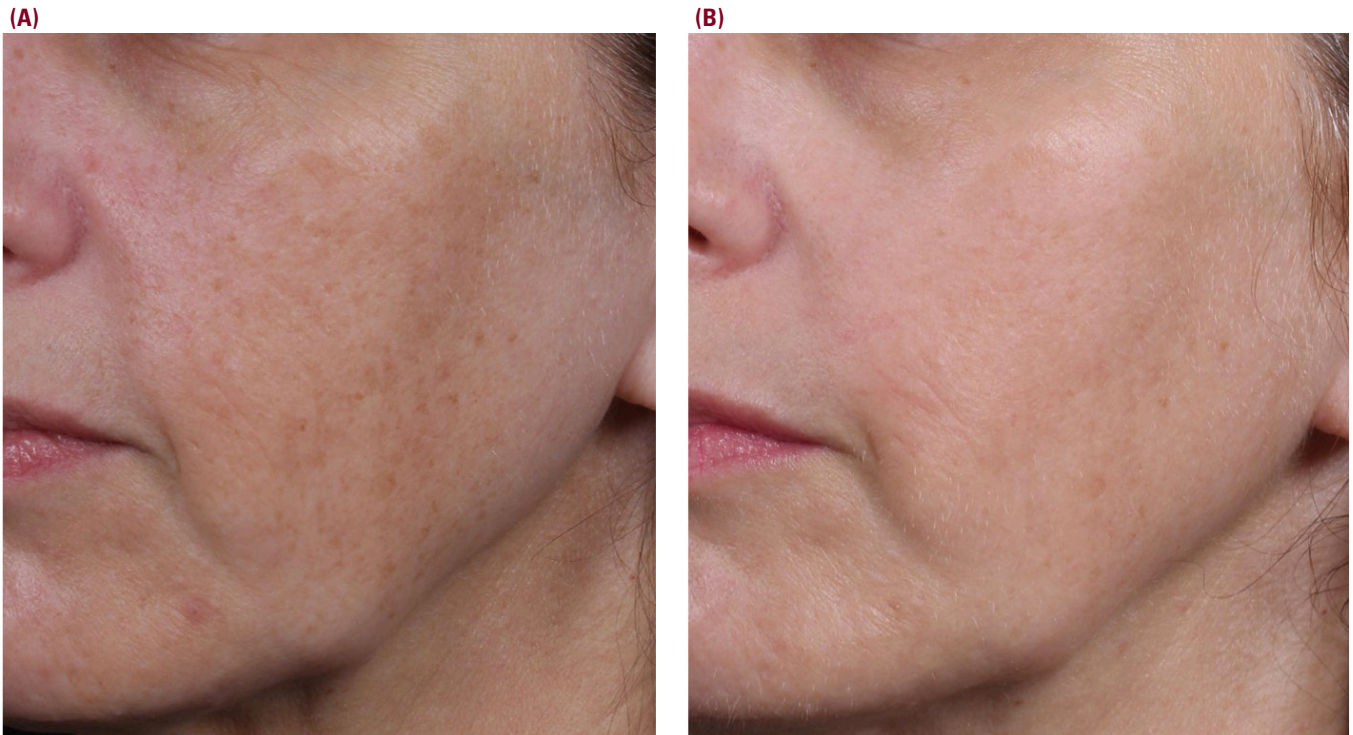


FIGURE 5. 50-year-old Caucasian female, Fitzpatrick skin type II, at baseline (A) and after 12 weeks on MDRejuvena regimen (B). Results: Marked improvement in overall skin color and clarity.

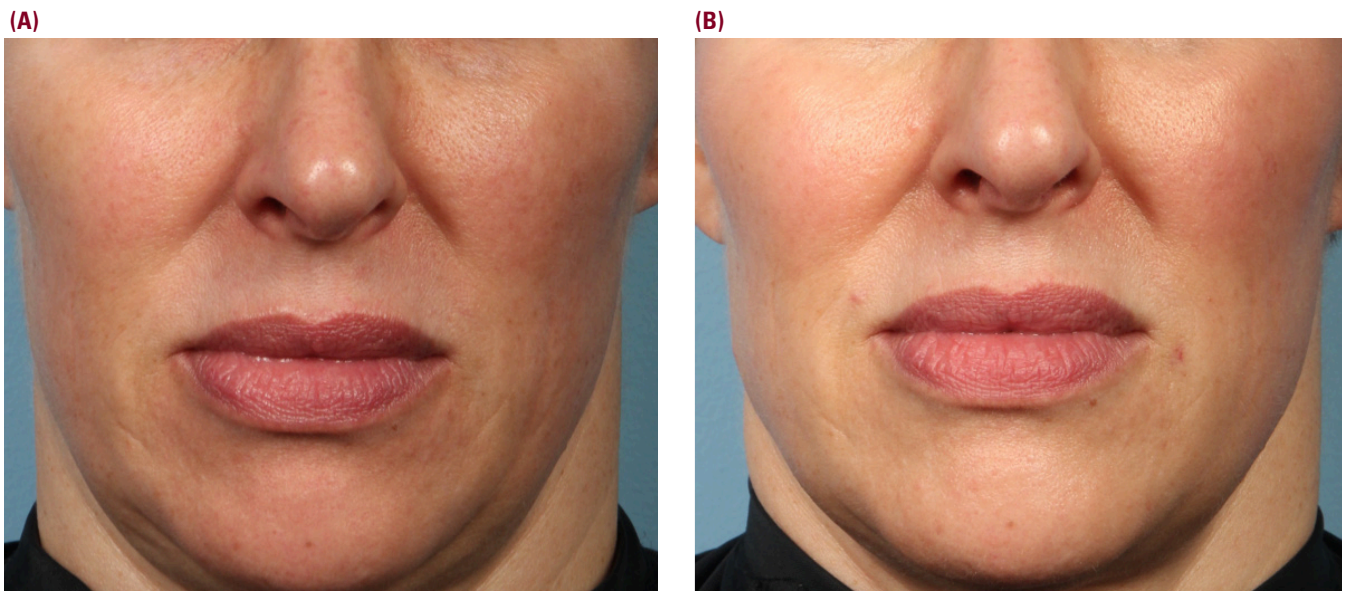

Figure 2 shows results of the physician assessment of severity of the various parameters evaluated at baseline and week 12. There was a decrease in mean severity of all parameters measured at week 12 compared to baseline.

Figure 3 shows results of the subject assessment of improvement of various skin parameters at week 12. Mild to moderate improvement was observed by subjects in all parameters assessed.

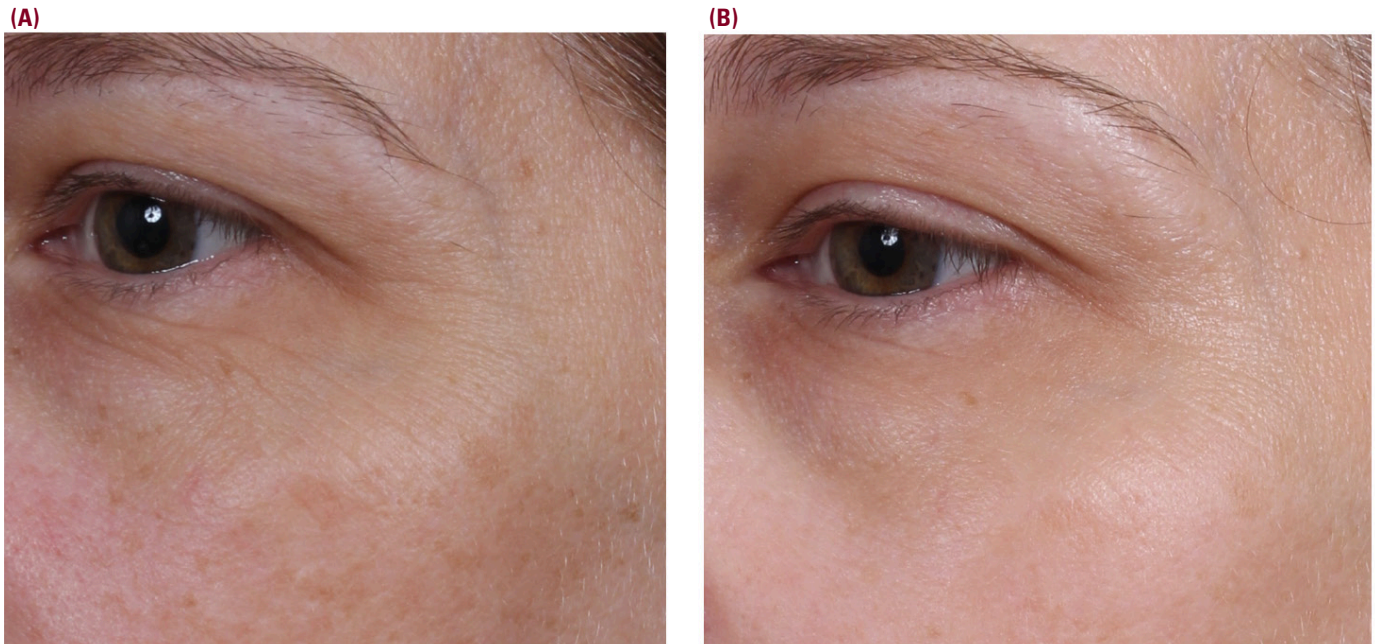
© 2016-Journal of Drugs in Dermatology. All Rights Reserved.

This document contains proprietary information, images and marks of Journal of Drugs in Dermatology (JDD).

No reproduction or use of any portion of the contents of these materials may be made without the express written consent of JDD.

If you feel you have obtained this copy illegally, please contact JDD immediately at support@jddonline.com

FIGURE 6. 48-year-old Caucasian female, Fitzpatrick skin type II, at baseline (A) and after 12 weeks on MDRejuvena regimen (B). Results: Marked improvement in the appearance of fine lines and hyperpigmentation.



Photographs taken before and after the 12-week continuation treatment are presented for representative subjects in Figure 4, 5 and 6 who previously received MELA, AGE and MELA treatments respectively.

Safety assessments revealed no adverse events or other safety issues experienced by any of the subjects during the continuation treatment.

DISCUSSION

A daily skin care regimen consisting of a proper cleanser, moisturizer, retinoid, and sunscreen has multiple beneficial effects⁷⁻¹². These clinical benefits include minimizing disruption in the skin barrier, hydration of the stratum corneum, maintaining optimal pH, improvement in photoaging of the face (reduction in wrinkling, mottled hyperpigmentation, skin roughness, tone and laxity) and protection against UV-induced erythema, sunburn and skin cancer. Topical tretinoin in particular has demonstrated significant improvement in multiple clinical signs of photodamaged skin.^{9, 10}

For more dramatic results, chemical peels that rely on skin exfoliation have commonly been used, however deep peels can be associated with long healing time and potential for complications.^{3, 4} Treatments based on the concept of creating skin resurfacing via controlled inflammation have been developed to successfully address skin disorders such as aging, hyperpigmentation, acne, and chronic redness. AGE and MELA resurfacing treatments have demonstrated improvements in skin condition

in women with signs of photoaging and hyperpigmentation, respectively, with minimal discomfort. The goal of the present study was to demonstrate that a daily treatment regimen of customized skin care products could maintain the benefits achieved from AGE, and MELA skin resurfacing treatments.

The results of this continuation study demonstrate that the use of a daily skin care regimen (including the MDRejuvena Rejuvaphyl Rejuvenating Complex) not only maintains but can enhance the beneficial effects of skin resurfacing treatments for at least 12 weeks. All of the physician assessments, and all but one of the subject assessments, indicated overall improvement compared to baseline in facial skin condition after 12 weeks of MDRejuvena product use following successful skin resurfacing treatments.

DISCLOSURES

Lora Colvan is employed by MDRejuvena, Inc.

REFERENCES

1. Coleman WP 3rd, Brody HJ. Advances in chemical peeling. *Dermatol Clin*. 1997;15:19-26.
2. Fischer TC, Perosino E, Poli F, Viera MS, Dreno B. Chemical peels in aesthetic dermatology: an update 2009. *J Eur Acad Dermatol Venereol*. 2010;24(3):281-92.
3. Landau, M. Chemical peels. *Clinics in Dermatol* 2008;26:200-208.
4. Rendon MI, Berson DS, Cohen JL, et al. Evidence and considerations in the application of chemical peels in skin disorders and aesthetic resurfacing. *J Clin Aesthetic Dermatol* 2010;3:32-43.
5. Sigler ML, Stephens TJ. Assessment of the safety and efficacy of topical copper chlorophyllin in women with photodamaged facial skin. *J Drug Dermatol*. 2015;14:401-4.
6. McCook JP, Dorogi PL, Vasily DB, Cefalo DR. In vitro inhibition of hyaluronidase by sodium copper chlorophyllin complex and chlorophyllin analogs. *Clinical, Cosmetic and Investigational Dermatology*. 2015;8:443-8.

7. Kuehl BL, Fyfe KS, Shear NH. Cutaneous cleansers. *Skin Ther Lett.* 2003;8(3):1-4.
8. Schorr ES, Sidou F, Kerrouche N. Adjunctive use of a facial moisturizer SPF 30 containing ceramide precursors improves tolerability of topical tretinoin 0.05%: a randomized, investigator-blinded, split-face study. *J Drugs Dermatol.* 2012;11(9):1104-7.
9. Kang S, Bergfield W, Gottlieb AB, et al. Long-term efficacy and safety of Tretinoin emollient cream 0.05% in the treatment of photodamaged facial skin: a two-year, randomized, placebo-controlled trial. *Am J Clin Dermatol.* 2005;6(4):245-53.
10. Weinstein GD, Nigra TP, Pochi PE, et al. Topical tretinoin for treatment of photodamaged skin. A multicenter study. *Arch Dermatol.* 1991;127(5):659-65.
11. Hirst NG, Gordon LG, Scuffham PA, Green AC. Lifetime cost-effectiveness of skin cancer prevention through promotion of daily sunscreen use. *Value in Health* 2012;15:261-8.
12. Rouabhia M, Mitchell DL, Rhoads M et al. A physical sunscreen protects engineered human skin against artificial solar ultraviolet radiation-induced tissue and DNA damage. *Photochem Photobiol Sci* 2002;1(7):471-7.

AUTHOR CORRESPONDENCE

Lora Colvan BS

E-mail:..... lcolvan@mdrejuvena.com