

Management of Impending Necrosis Associated With Soft Tissue Filler Injections

Steven H. Dayan MD FACS,^{a,b} John P. Arkins BS,^c Clyde C. Mathison MD^d

^aChicago Center for Facial Plastic Surgery, Chicago, IL

^bDepartment of Otolaryngology, University of Illinois at Chicago, Chicago, IL

^cDeNova Research, Chicago, IL

^dDepartment of Otolaryngology, Head and Neck Surgery at University of Illinois at Chicago, Chicago, IL

ABSTRACT

Background: As the number of soft tissue filler injections increases, the number of adverse events associated with injection may rise. Impending necrosis represents a serious complication that, if not treated correctly and timely, may have grave consequences.

Objective: We describe a protocol utilizing hyaluronidase, nitroglycerin paste, aspirin, antacid and a topical oxygen therapy that may be used to treat impending necrosis subsequent to injection with soft tissue fillers.

Conclusion: We have successfully treated nine post-filler injection adverse events involving impending necrosis or necrosis following both hyaluronic acid and calcium hydroxylapatite injections using our protocol.

J Drugs Dermatol. 2011;10(9):1007-1012.

INTRODUCTION

The increasing demand for soft tissue augmentation using non-permanent and semi-permanent fillers represents a shift in aesthetic medicine towards minimally invasive procedures with fast actualization of results and minimal morbidity. Soft tissue fillers offer patients a means to achieve a more youthful appearance through the treatment of fine lines and facial volume loss associated with the aging face. In 2009, nearly 1.5 million injections of hyaluronic acid (HA) and calcium hydroxylapatite (CaHA) were performed, making it the second most popular medical cosmetic procedure in the U.S.¹ However, despite the strong safety profile, complications can occur.

Possible complications associated with soft tissue fillers can be categorized by time of onset (immediate, early or delayed) and by severity (minor or major). Minor complications occurring immediately or early after injection are usually transient, resolving within a week without sequelae and include injection site associated reactions such as edema, erythema, tenderness or pain, bruising and itching.⁴ Major side effects have been both early and delayed in onset and while rare, pose a significant risk if not treated immediately.

Impending necrosis following soft tissue filler injection is a major, early-onset complication that is likely the result of vascular injury, compression or obstruction of the facial artery, angular artery, lateral nasal artery, supratrochlear artery or their branches and requires swift and aggressive treatment in order to prevent

tissue necrosis.⁴⁻⁶ Certain areas, such as the glabella, are at a higher risk for developing necrosis, although there have been reports of necrosis in the ala and nasolabial fold area following treatment with HA and more recently, CaHA.^{4,5,7-9} Impending necrosis has been reported involving all types of filler with incidences estimated at 0.001 percent for collagen and HA.^{7,10}

Over the last three years, there have been nineteen patients referred to our clinic for evaluation and management of severe adverse events following soft tissue filler treatments. Following our report on treatment protocols for managing post-filler hypersensitivity reactions of infectious origins, we have seen an increase in the number of referred patients with post-treatment "hypersensitivity reactions."^{11,12} In addition and with increasing frequency, we are also seeing more patients with impending necrosis following HA and CaHA injections, a potentially devastating complication. Perhaps the increase in incidence is parallel to the rise in filler treatments performed in the US, or possibly, it is secondary to newer and deeper injection patterns. An additional concern is the varied experience level and training backgrounds of those who are treating the expanding market of patients.¹³

It has been our experience that impending necrosis presents in one of three patterns: immediate, early (within 24–48 hours) and delayed. However, in treating each presentation slightly differently, we have had success in preventing significant scarring or sequelae. To better illustrate our methods for managing post-

soft tissue filler vascular complications, we present a series of three impending necrosis cases with varying presentation and treatment timepoints, all of which have subsequently been resolved using a modified treatment protocol for treating impending necrosis associated with injections of soft tissue filler.

CASE REPORT

Case 1: Immediate Presentation

Patient is a 39-year-old woman with no significant past medical history who, following 15 minutes of ½ teaspoon of topical 30% lidocaine cream (Specialty Compounding Pharmacy, Sherman Oaks, CA), received 1.5 cc of CaHA (Radiesse, Merz Aesthetics, San Mateo, CA) into each nasolabial fold and 0.75 cc to each infraorbital region. The last treated segment was the left nasolabial fold; and after 0.5 cc of CaHA was injected, an immediate blanch was noticed over the left medial cheek, lateral left nasal sidewall and extending down to the left upper lip. The injection was immediately stopped. The patient had no complaints nor suspected anything unusual. Application of a half inch of 2% nitroglycerin paste (Nitro-BID, E. Fougera & Co., Melville, NY) was massaged onto the area. Within five minutes, a pink hue returned to the affected area and the skin appeared similar to the other side. The patient was watched for thirty minutes, and following no unusual signs or symptoms, she was discharged without any difficulty.

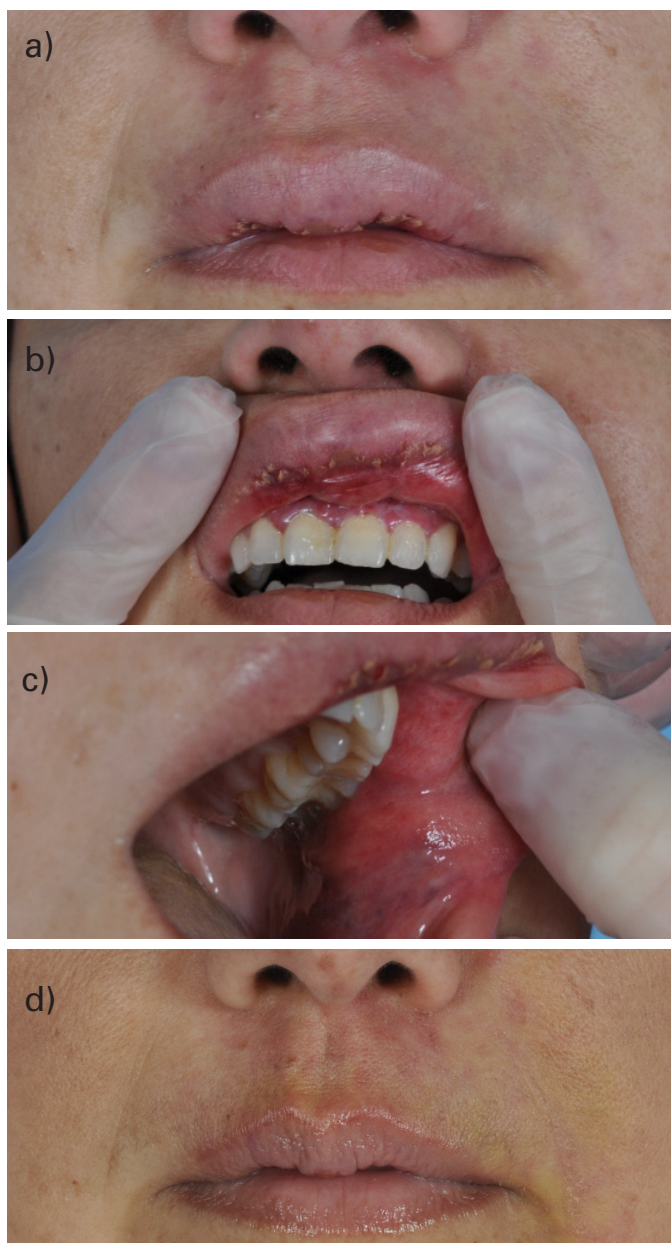
Two days later, the patient returned to the clinic with asymmetric edema and erythema of the left lower face, along with congestion of the upper lip and left buccal mucosa (Figure 1a). There was no sign of skin necrosis, but a reticulated pattern of vascular congestion was noted. Tenderness and mucosal ulceration of the upper lip was apparent (Figure 1 b and c). The patient was diagnosed with venous congestion and vascular compromise. After appropriate skin testing, she was treated with 150 units of hyaluronidase (Vitrane, ISTA Pharmaceuticals, Irvine, CA) mixed 1:1 with saline to the left nasolabial fold and a half inch of a 2% nitroglycerin paste was massaged into the area. She was placed on methylprednisolone (Medrol Dosepak, Pfizer, New York, NY), aspirin 325 mg daily, antacids and a topical oxygen infusion cream (Dermacyte Oxygen Concentrate, Oxygen Biotherapeutics, Inc., Durham, NC) to be applied topically twice-daily.

She was seen daily for nitroglycerin paste massages with decreasing congestion noted each day. Oral cavity ulceration was resolved within 24 hours of its presentation. Three days later, five days after the injection, the patient's erythema and edema were markedly improved (Figure 1d). Nitroglycerin paste massages were terminated. She was satisfied with the cosmetic results. The patient was instructed to complete the methylprednisolone pack and continue the daily aspirin and oxygen cream for one more week.

Case 2: Early Presentation (24 to 48 Hours)

Patient is a 43-year-old woman who received 1.0 cc of CaHA (Radiesse, Merz Aesthetics, San Mateo, CA) into each nasolabial fold, following 15 minutes of ½ teaspoon of topical 30% lidocaine cream (Specialty Compounding Pharmacy, Sherman Oaks, CA). The procedure was uneventful. The patient returned four days later with complaints of "soreness, swelling and redness" to the right nasolabial fold region, all of which started approximately twenty-four hours after receiving the injection (Figure 2a). She also noted small amounts of drainage coming from the superior

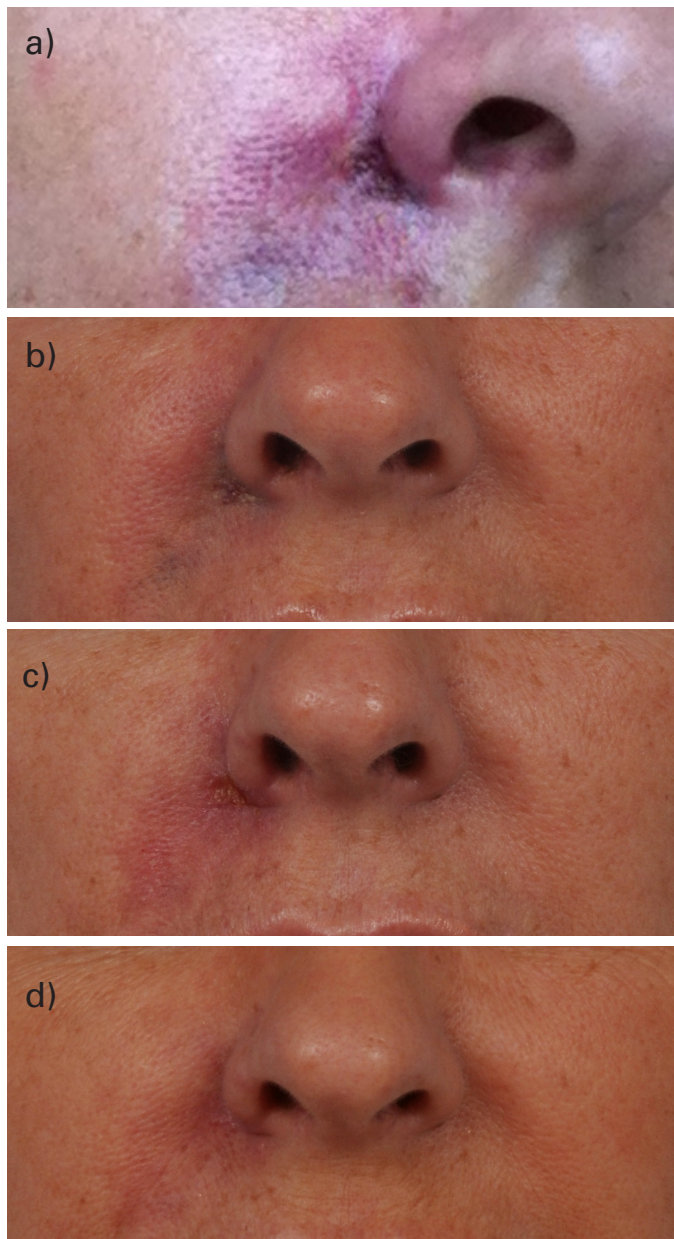
FIGURE 1. a) Impending necrosis two days after injection. **b-c)** Mucosal ulceration of the upper lip. **d)** Marked improvement following three days of treatment, five days after injection.



aspect of the right nasolabial fold. Upon examination, she was tender to palpation along the entire length of the nasolabial fold. The overlying skin was erythematous and had a congested reticular pattern (Figure 2b). A small amount of thick serous drainage was obtained from the superior aspect of the right nasolabial fold. It was swabbed and sent for culture, which returned negative for bacterial growth. The area of vascular compromise was cleansed with betadine, and 2% nitroglycerine paste (Nitro-BID, E. Fougera & Co., Melville, NY) was applied topically along the en-

tire nasolabial fold, while topical antibiotic ointment was applied to the draining area. After testing for hyaluronidase hypersensitivity, 20 units of hyaluronidase (Vitrane, ISTA Pharmaceuticals, Irvine, CA) were injected into the nasolabial fold and the patient was started on aspirin 325 mg daily and antacids. We assumed an infectious process and prescribed clindamycin 300 mg three times a day for seven days. The edema and erythema continued to worsen over the next 24 hours, and levofloxacin (Levaquin, Ortho-McNeil-Janssen Pharmaceuticals, Inc., Titusville, NJ) 750 mg daily was added to her treatment regimen.

FIGURE 2. a) Impending necrosis twenty-four hours post injection. **b)** Impending necrosis four days after injection. **c)** Marked improvement following four days of treatment, eight days after injection. **d)** Marked improvement following 11 days of treatment, 15 days after injection.



The patient returned to our clinic four days later (Figure 2c). The area of erythema and induration had increased to include the right upper lip; however, most of the edema and drainage had resolved. Fifteen units of hyaluronidase were injected into the nasolabial fold and a half inch of a 2% nitroglycerin paste was applied. The patient was also instructed to begin placing warm compresses to the area and to continue the antibiotics and aspirin. Application of topical oxygen infusion cream (Dermacyte Oxygen Concentrate, Oxygen Biotherapeutics, Inc., Durham, NC) twice-daily was begun.

After 48 hours, the induration was beginning to regress, and the area of previous drainage and skin break down was showing signs of partial thickness epithelialization. A small amount of crusting remained. After cleansing, a third dose of 2% nitroglycerin paste was applied to the nasolabial fold.

One week later, upon examination, the areas of induration and erythema were nearly resolved, and the wound at the superior aspect of the nasolabial fold had completely epithelialized (Figure 2d). Over the next several weeks, the patient returned three times for additional doses of 2% nitroglycerin paste. She believed it had an immediate effect on reducing the violaceous reticulated color to the overlying skin. Four weeks after the initial injection, all symptoms were resolved, and the patient was satisfied with the cosmetic improvement.

Case 3: Delayed Presentation (4 Weeks)

Patient is a 36-year-old woman with a past medical history significant for prior oral herpes infection who presented to our clinic one month after undergoing CaHA injection into her right nasolabial fold by an outside physician. Per the patient, within twenty-four hours of the injection, she noticed swelling, erythema and bruising extending from the nasolabial onto the right malar region. The wound worsened over the next several days with increasing spreading erythema and edema extending superiorly to her medial orbit and inferiorly to the inferior aspect of her nasolabial fold. There was skin breakdown and ulceration over the nasolabial fold (Figure 3a). The patient went to a local Emergency Room, where the treating physician suspected an infectious etiology. She was treated with an unknown intravenous antibiotic. A referral to a different local plastic surgeon resulted in a prescription for oral

valacyclovir HCL (Valtrex, GlaxoSmithKline, London, UK), ciprofloxacin (Cipro, Bayer, Leverkusen, Germany) and topical steroid therapy. There was little improvement in her condition over the next four weeks and she was referred to our clinic for tertiary evaluation. On examination in our clinic, she had a large patch of reticulated skin on the right malar region measuring 8 x 2.5 cm with a mild amount of edema, and the skin was atrophic, but epithelialized (Figure 3b). There was no purulent drainage.

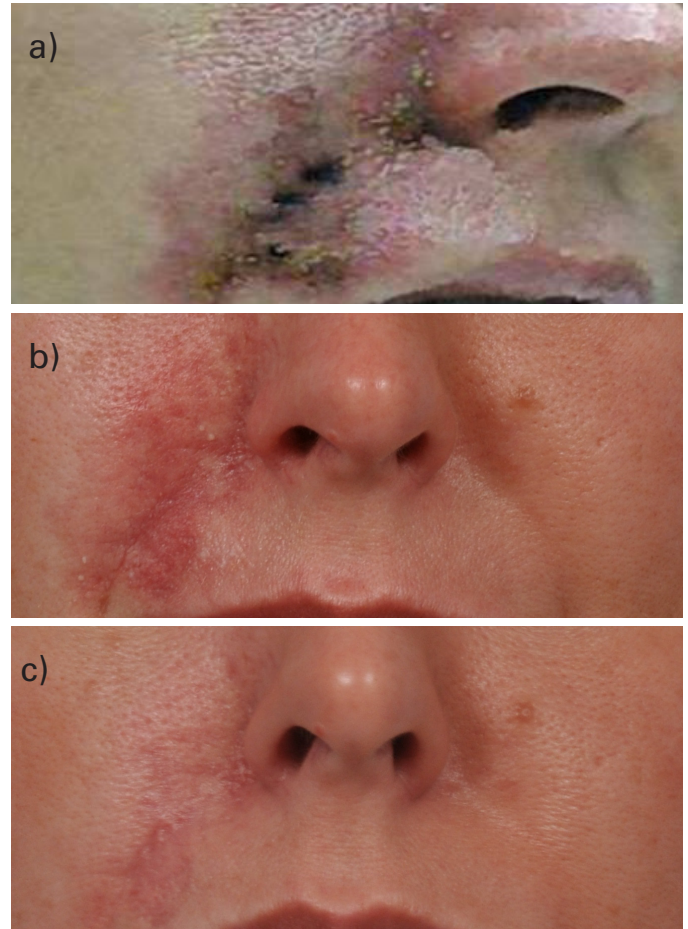
The patient was treated according to our impending necrosis protocol. After cleansing and appropriate skin testing, 40 units of hyaluronidase (Vitrace, ISTA Pharmaceuticals, Irvine, CA) was injected into the indurated areas and a 2% nitroglycerin paste (Nitro-BID, E. Fougera & Co., Melville, NY) was applied. She was started on topical oxygen therapy (Dermacyte Oxygen Concentrate, Oxygen Biotherapeutics, Inc., Durham, NC), aspirin 325 mg daily and instructed to continue the ciprofloxacin. On follow up, she continued to have erythema and induration to the nasolabial fold, but both had improved markedly. An additional dose of 2% nitroglycerin paste was applied, and the patient was instructed to continue using the topical oxygen therapy. The oral medicines were discontinued. Four weeks after beginning our treatment protocol, significant improvement was noted in the affected area, and the patient was optimistic about her outcome (Figure 3c).

Necrosis related to soft tissue filler injections of the nasolabial fold, glabella or other vascular watershed areas is a serious complication, and, while rare, all physicians should be aware of a treatment protocol.

DISCUSSION

Necrosis related to soft tissue filler injections of the nasolabial fold, glabella or other vascular watershed areas is a serious complication, and, while rare, all physicians should be aware of a treatment protocol. A possible cause of the necrosis is intravascular injection of the filler product and resulting vascular occlusion, which would result in an immediate blanching along a recognizable vascular pattern. This should be obvious to the injecting physician. One could argue that aspirating before injecting could be helpful to indentifying intravascular cannulization. However, it is technically difficult to aspirate adequately with the current FDA cosmetically approved soft tissue filler products in the U.S. In an attempt to reduce immediate intravascular embolus, it has been our practice to inject slowly antegrade and to keep the needle constantly mobile. We also avoid injection in the immediate vicinity of large named facial vessels and pre-mix our product with 0.3 ml of lidocaine prior to injecting, which decreases the viscosity of the product and theoretically reduc-

FIGURE 3. a) Impending necrosis one week after injection. **b)** Impending necrosis 4–5 weeks after injection. **c)** Marked improvement following four weeks of treatment.



es risk for occlusion. Additionally, the recent adoption of blunt tip cannulas (SoftFil, Soft Medical Aesthetics, Paris, France) for subdermal injections significantly reduces post-treatment ecchymoses and likely reduces the risk for intravascular cannulization.

However, most of the impending necrosis that we have treated is likely due to either pressure necrosis secondary to local edema or to occlusion of adjacent vasculature secondary to the hydrophilic properties of the product. These mechanisms explain the delayed onset reported.

The senior author has instituted a modified version of a previously published protocol to treat impending necrosis subsequent to soft tissue filler injection with efficacious results (Table 1).¹⁴ Upon first recognition of vascular compromise, as evident by blanching followed by a dusky or purple discoloration of the area, injection should be immediately discontinued.⁴ Regardless of the filler, 10–30 units of hyaluronidase (Vitrace, ISTA Pharmaceuticals, Irvine, CA) diluted 1:1 with saline per 2x2 cm area are injected into the area of impending necrosis. Skin testing is recommended

TABLE 1.

Recognition and Management of Impending Necrosis

Presentation	Immediate or early blanching followed by a dusky or purple discoloration of the area
Treatment	<p>Discontinue injection</p> <p>Perform hyaluronidase skin testing</p> <p>Inject 10-30 U of hyaluronidase per 2x2 cm area</p> <p>Massage ½ inch of 2% nitroglycerin paste into the area</p> <p>Apply warm compresses</p> <p>Begin 325 mg ASA and an antacid regimen</p> <p>Apply topical oxygen cosmeceutical therapy BID</p>
Further Management	<p>Follow patient daily for further signs of occlusion/necrosis</p> <p>Continue hyaluronidase and 2% nitroglycerin paste daily as needed</p> <p>Continue ASA, antacid and topical oxygen therapy until wound has healed</p> <p>If edema progresses, place on Medrol Dose pack</p> <p>Consider hyperbaric oxygen for progressing necrosis resistant to the above-mentioned treatments options</p>

prior to treatment with hyaluronidase as a hypersensitivity reaction can occur.^{4,8,15} It has been previously demonstrated that hyaluronidase has edema-reducing benefits and has been efficacious in mediating rejection-induced edema and necrosis associated with myocardial infarction.¹⁶⁻¹⁸ It is probable that an increased inflammatory response causes an increase in hyaluronan due to proinflammatory cytokines and growth factors, which is then mitigated by the hyaluronidase.¹⁹⁻²³ Its edema-reducing benefits and theoretical reduction in occluding vessel pressure is why we believe it is efficacious in treating impending necrosis secondary to all products, not just hyaluronic acid.

Additionally, 2% nitroglycerin paste (Nitro-BID, E. Fougera & Co., Melville, NY) is applied to the affected area with the amount dependent on size and area of impending necrosis. The volume of distribution of nitroglycerin is about 3 L/kg, with a half-life of about three minutes and maximal achievable duration of anti-anginal effects being about 12 hours.²⁴ The nitroglycerin paste is applied daily to the affected area so long as the capillary refill rate is less than two seconds. The area is massaged and warm compresses are applied to increase vasodilation. Often, an immediate vasodilatory effect with improvement in the skin color is realized. Care is taken to use a small amount of 2% nitroglycerin paste (approximately a half inch), as too much can lead to unwanted systemic effects.

The patient is started on an aspirin regimen of 325 mg daily to prevent further clot formation due to vascular compromise and an antacid to prevent aspirin-associated gastritis. Topical oxygen

cosmeceutical therapy (Dermacyte Oxygen Concentrate, Oxygen Biotherapeutics, Inc., Durham, NC) is applied to the affected area twice-daily. Topical oxygen therapies have demonstrated an enhanced rate of epithelialization of excisional wounds and second-degree burns.²⁵ Hyperbaric oxygen has also been recommended as a treatment option for impending necrosis, depending on the severity of the condition.^{7,9} However, the risks, benefits and inconveniences associated with the treatment may pose significant barriers to some and the procedure is recommended in instances of severe necrosis or delayed presentations in which the tissue is not healing well.⁴

Patients are followed daily for further signs of occlusion or necrosis. If improvement is noted, nitroglycerin paste massages can be stopped. However, they anecdotally seem to accelerate the reticulated vascular congestion resolution. Topical oxygen therapy and aspirin are continued until the wound is satisfactorily healed. If there is no improvement or if progression of necrosis occurs, the regimen should be repeated daily. If edema is slow to resolve, methylprednisolone (Medrol Dosepak, Pfizer, New York, NY) is added. Hyperbaric oxygen should be considered if the above measures are still not adequate.

As the use of fillers becomes increasingly more common and the skill level of those injecting is so varied, adverse events can be expected to increase as well. Avoiding complications is always the best measure, and with appropriate training and injection techniques, many complications can be avoided. However, adverse events can occur in the best of hands, and early detection is imperative. If a consensus can be agreed on how to treat adverse events effectively, then devastating complications can be prevented. It is our belief that the protocol we are using for treating impending necrosis has been successful for managing immediate and delayed presentation of impending necrosis.

CONCLUSION

We have successfully treated nine post-filler injection adverse events involving impending necrosis or necrosis following both HA and CaHA injections using our protocol. Proper management of complications associated with soft tissue fillers is imperative as both the number of injections and fillers expands.

DISCLOSURES

The authors have no relevant disclosures.

REFERENCES

1. The American Society of Aesthetic Plastic Surgery. 2009 Statistics from The American Society of Aesthetic Plastic Surgery; 2010. Available at: <http://www.surgery.org/sites/default/files/2009stats.pdf>. Accessed October 27, 2010.
2. Sclafani AP, Fagien S. Treatment of injectable soft tissue filler complications. *Dermatol Surg*. 2009;35(suppl 2):1672-1680.
3. Gladstone HB, Cohen JL. Adverse effects when injecting facial

- fillers. *Semin Cutan Med Surg.* 2007;26(1):34-39.
4. Grunebaum LD, Bogdan Allemann I, Dayan S, Mandy S, Baumann L. The risk of alar necrosis associated with dermal filler injection. *Dermatol Surg.* 2009;35(suppl 2):1635-1640.
 5. Schanz S, Schippert W, Ulmer A, Rassner G, Fierlbeck G. Arterial embolization caused by injection of hyaluronic acid (Restylane). *Br J Dermatol.* 2002;146(5):928-929.
 6. Coleman SR. Avoidance of arterial occlusion from injection of soft tissue fillers. *Aesthet Surg J.* 2002;22(6):555-557.
 7. Narins RS, Jewell M, Rubin M, Cohen J, Strobos J. Clinical conference: Management of rare events following dermal fillers—focal necrosis and angry red bumps. *Dermatol Surg.* 2006;32(3):426-434.
 8. Hirsch RJ, Cohen JL, Carruthers JD. Successful management of an unusual presentation of impending necrosis following a hyaluronic acid injection embolus and a proposed algorithm for management with hyaluronidase. *Dermatol Surg.* 2007;33(3):357-360.
 9. Georgescu D, Jones Y, McCann JD, Anderson RL. Skin necrosis after calcium hydroxylapatite injection into the glabellar and nasolabial folds. *Ophthalm Plast Reconstr Surg.* 2009;25(6):498-499.
 10. Hanke CW, Higley HR, Jolivet DM, Swanson NA, Stegman SJ. Abscess formation and local necrosis after treatment with Zyderm or Zyplast collagen implant. *J Am Acad Dermatol.* 1991;25(2 Pt 1):319-326.
 11. Dayan SH, Arkins JP, Brindise R. Soft tissue fillers and biofilms. *Facial Plast Surg.* 2011;27(1):23-28.
 12. Dayan SH. Managing Filler Complications. *Merge.* Allured Business Media. 2010:22-23.
 13. Spear M. What are the necessary practice competencies for two providers: Dermal fillers and botulinum toxin type A injections? *Plast Surg Nurs.* 2010;30(4):226-246; quiz 247-228.
 14. Cohen JL. Understanding, avoiding, and managing dermal filler complications. *Dermatol Surg.* 2008;34(suppl 1):92S-99S.
 15. Brody HJ. Use of hyaluronidase in the treatment of granulomatous hyaluronic acid reactions or unwanted hyaluronic acid misplacement. *Dermatol Surg.* 2005;31(8 Pt 1):893-897.
 16. Johnsson C, Hallgren R, Elvin A, Gerdin B, Tufveson G. Hyaluronidase ameliorates rejection-induced edema. *Transpl Int.* 1999;12(4):235-243.
 17. Maroko PR, Hillis LD, Muller JE, et al. Favorable effects of hyaluronidase on electrocardiographic evidence of necrosis in patients with acute myocardial infarction. *N Engl J Med.* 1977;296(16):898-903.
 18. Maroko PR, Libby P, Bloor CM, Sobel BE, Braunwald E. Reduction by hyaluronidase of myocardial necrosis following coronary artery occlusion. *Circulation.* 1972;46(3):430-437.
 19. Engstrom-Laurent A, Feltelius N, Hallgren R, Wasteson A. Raised serum hyaluronate levels in scleroderma: An effect of growth factor induced activation of connective tissue cells? *Ann Rheum Dis.* 1985;44(9):614-620.
 20. Hamerman D, Wood DD. Interleukin 1 enhances synovial cell hyaluronate synthesis. *Proc Soc Exp Biol Med.* 1984;177(1):205-210.
 21. Heldin P, Laurent TC, Heldin CH. Effect of growth factors on hyaluronan synthesis in cultured human fibroblasts. *Biochem J.* 1989;258(3):919-922.
 22. Yaron M, Yaron I, Wiletzki C, Zor U. Interrelationship between stimulation of prostaglandin E and hyaluronate production by poly (I) . poly (C) and interferon in synovial fibroblast culture. *Arthritis Rheum.* 1978;21(6):694-698.
 23. Suzuki M, Asplund T, Yamashita H, Heldin CH, Heldin P. Stimulation of hyaluronan biosynthesis by platelet-derived growth factor-BB and transforming growth factor-beta 1 involves activation of protein kinase C. *Biochem J.* 1995;307(Pt 3):817-821.
 24. Nitro-BID [package insert]. Melville, NY: E. Fougera & Co.; 2010.
 25. Davis SC, Cazzaniga AL, Ricotti C, et al. Topical oxygen emulsion: A novel wound therapy. *Arch Dermatol.* 2007;143(10):1252-1256.

ADDRESS FOR CORRESPONDENCE

Steven H. Dayan, MD

Chicago Center for Facial Plastic Surgery

Department of Otolaryngology at

University of Illinois at Chicago

845 North Michigan Avenue

Suite 923 East

Chicago, IL 60611

Phone:.....(312) 335-2070

Fax:.....(312) 335-2074

E-mail:.....sdayan@drdayan.com